

Case Report

Acute colon pseudo-obstruction after percutaneous endoscopic gastrostomy: An unusual co-incidence in a case of acute stroke

Suhas D. Wagle, Pradeep G. Divate¹, Pradeep M. D'Costa², Tushar Kalekar³

GI Unit, ¹Department of Neurology, ²Department of Medicine, KEM Hospital, ³Anushka Radiology Services, KEM Hospital, Pune, Maharashtra, India

Abstract

Percutaneous endoscopic gastrostomy (PEG) is a standard procedure for enteral feeding tube placement in the stomach for patients with nonobstructive dysphagia. Major and minor complications have been described in early and delayed phase. We describe a 57-year-old hypertensive male patient who underwent PEG for nonobstructive dysphagia after an acute cerebro-vascular accident that presented as right hemiplegia due to pontine hemorrhage. Patient went on to develop nonobstructive spontaneous acute colon dilation from cecum to rectum 72 h after the procedure. Computed tomography scan of the abdomen was undertaken to rule out mechanical obstruction or colon entrapment. Injection Neostigmine was used on day 10 after PEG as there was a recurrence after initial partial resolution. Thereafter patient had an uneventful recovery.

Key words

Abdomen distension, cerebro-vascular accident, colonic ileus, dysphagia, enteral feed, megacolon

Introduction

Percutaneous endoscopic gastrostomy (PEG) described originally by Ponsky and Gauderer,^[1,2] is a routine procedure for enteral access in patients with swallowing disorders. The complication rates vary from minor (7–20%) to major complications (3–4%).^[3] PEG complications have been categorized into: (a) Complications of upper endoscopy; (b) direct complications of the PEG procedure; and (c) postprocedural complications associated with PEG tube use and wound care.^[4] Acute colonic pseudo obstruction has not been reported after PEG. We report a case of colon dilation after PEG in a case of acute stroke.

Case Report

A 57-year-old male was admitted with acute stroke, right sided hemiplegia and respiratory distress. Patient needed mechanical ventilation support from the day of admission. Computed tomography (CT) scan [Figure 1] and magnetic resonance imaging scan of the brain revealed left sided pontine hemorrhage extending into the fourth ventricle with edema causing aqueduct compression.

Laboratory workup was as follows:

- First week after admission: Hemoglobin: 14.6 g% white blood cell (WBC): 13,900/cmm platelets: 3.64×10^3 /cmm
- Preprocedure hemoglobin: 12.7 g% WBC: 5,500/cmm platelets: 4.36×10^3 /cmm
- Serum creatinine: 0.6 mg% serum sodium: 130 mEq/L serum potassium: 4.7 mEq/L
- Prothrombin time: 13/11 s activated partial thromboplastin time: 31/34 s
- Postprocedure (day 3) hemoglobin: 13.1 g% WBC: 11,400/cmm platelets: 3.56×10^3 /cmm
- Postprocedure (day 6) hemoglobin: 11.7 g% WBC: 6,200/cmm platelets: 2.82×10^3 /cmm.

Access this article online

Website: www.jdeonline.in	Quick Response Code 
DOI: 10.4103/0976-5042.150670	

Address for correspondence:

Dr. Suhas D. Wagle, KEM Hospital, 489, Rasta Peth, Pune - 411 011, Maharashtra, India. E-mail: sdwagle@gmail.com

Patient had undergone tracheostomy and was treated for lower respiratory tract infection. Initially, nasogastric tube feeding was done as patient was unable to swallow. On day 16 after stroke the patient underwent PEG by pull technique using Freka 20 Fr tube (Freka PEG Set Gastric FR 20 Fresenius Kabi AG). Tube feeds commenced 24 h later were well tolerated and patient had a spontaneous bowel movement. Abdominal bloating was noticed 72 h postprocedure and there was no stool passage for 48 h. Bowel sounds were normal. There was no rectal fecal impaction on digital examination. Serum potassium on the same day was 4.4 mEq/L, dropped to 2.8/mEq/L on the next day and was corrected to 4.1 mEq/L over next 24 h. Roentgenogram of chest was normal and there was no evidence of pneumoperitoneum on roentgenogram of abdomen [Figure 2] on day 4 after PEG. The entire colon from caecum to rectum appeared dilated with preserved haustral markings. Small bowel dilation was absent. Tube feeding was discontinued. The transverse colon diameter in the roentgenogram was 5.6 cms. Clinically the patient remained

afebrile with soft abdomen, normal bowel sounds and had spontaneous bowel movements. Patient was kept in right or left lateral decubitus positions intermittently. There was gradual reduction of colon dilation observed in 72 h. CT scan of abdomen was done on day 7 postprocedure. The colon was grossly dilated from caecum to anal verge [Figure 3] without evidence of stenosis or obstruction. Dimensions measured on CT scan: Caecum 6.3 cm, ascending colon 5.2 cm, transverse colon 6.1 cm, descending colon 5.1 cm, sigmoid colon 4.9 cm and rectum 4.3 cm. The PEG tube was securely placed in the gastric lumen without colon entrapment [Figure 4]. There was no evidence of free fluid or pneumo-peritoneum. There was delay in clearance of oral contrast on follow-up abdomen roentgenograms [Figure 5] up to 72 h after CT scan. PEG feeds withheld earlier were resumed again on 9th day. Neostigmine 2 mg was administered intravenously on the next day. Patient had no abdominal symptoms thereafter and tolerated tube feeds that were continued uneventfully. Two months later, the PEG tube was removed after neurological recovery.

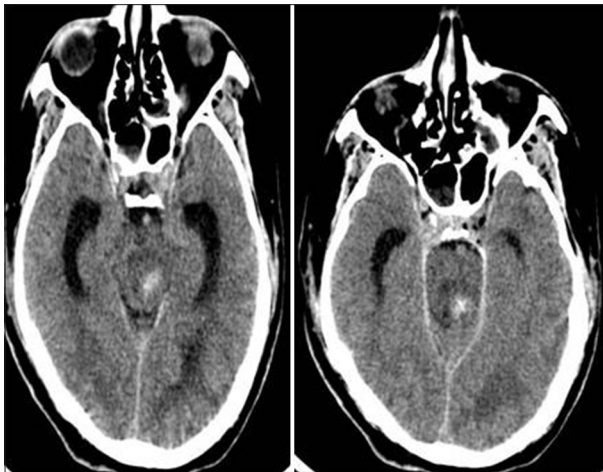


Figure 1: Computed tomography scan brain: Left pontine hemorrhage and edema causing compression of aqueduct

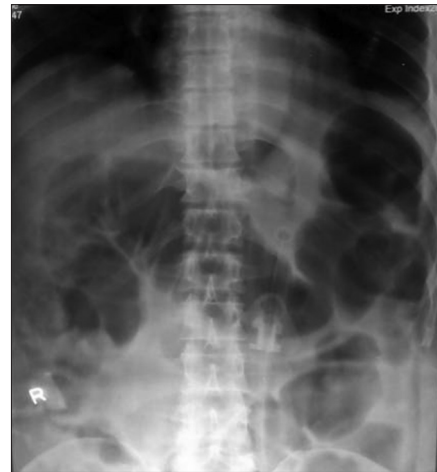

Figure 2: Abdomen roentgenogram taken on the day of distension post percutaneous endoscopic gastrostomy

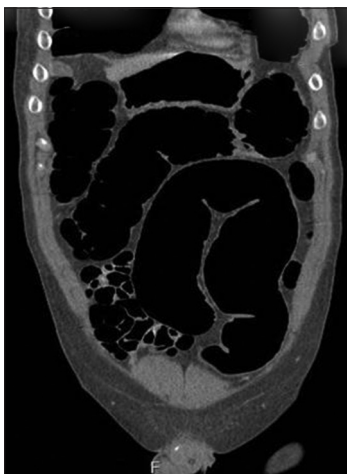

Figure 3: Computed tomography scan abdomen coronal image showing entire large bowel dilatation including rectum

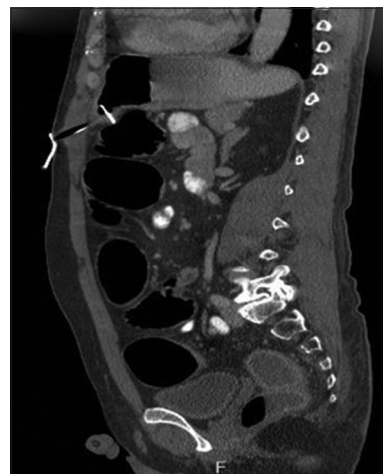


Figure 4: Computed tomography scan abdomen: Track of percutaneous endoscopic gastrostomy tube without colon entrapment

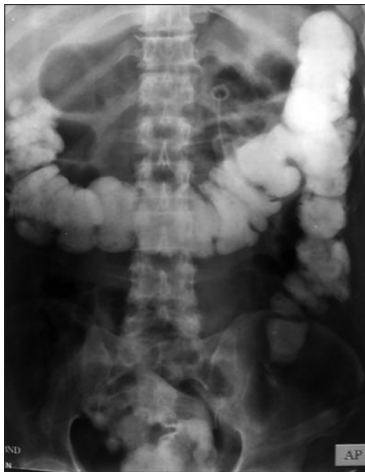

Figure 5: Post computed tomography scan abdomen roentgenogram after 72 h

Discussion

Percutaneous endoscopic gastrostomy has potential complications. Prior surgery leading to altered bowel anatomy could lead to difficulties in PEG.^[5] Acute bleeding could be seen in 1% of cases, and visceral perforation/peritonitis could be seen in 0.5–1.3% of cases immediately after PEG.^[3] Pneumoperitoneum is seen in up to 50% of patients^[4] after PEG and in the absence of fever, sepsis or signs of peritonitis may be a self-limiting complication. During percutaneous cannula puncture, there is a risk of adjacent organ injury by entrapment. The transverse colon that is in proximity with stomach is prone to injury. Acute colon injury after PEG^[4] presents as fecal peritonitis. Delayed presentation is seen as gastro-colo-cutaneous fistula. Small bowel is usually well protected by omentum but can be involved in cases with prior abdominal surgery.^[4] Acute colonic pseudo-obstruction (ACPO) has been described in patients with brainstem hemorrhage.^[6] In these cases, if the presentation is seen after PEG, bowel injury needs to be excluded.

Our patient had no abdominal signs or symptoms initially during naso-gastric tube feeding. Abdominal distension was noticed 72 h after PEG. Plain roentgenogram abdomen revealed dilation of the entire colon without small bowel distension. Haustral markings were preserved. Distal colon obstruction, colon ischemia, and acute colon injury due to PEG were considered as clinical possibilities. Presence of air in the rectum and lack of evidence of sigmoid volvulus or fecal impaction were not in favor of bowel obstruction. Spontaneous fluctuations in the colon size were noticed on serial roentgenograms. There was no clinical evidence of peritonitis. Abdominal CT scan excluded leak from the GI tract, bowel obstruction (neoplasm or diverticulitis), bowel entrapment and CT mesenteric angiography was normal.

Acute colonic pseudo-obstruction may lead to megacolon that has been defined as colon dilation where the diameters

of recto-sigmoid junction or descending colon exceeds 6.5 cm or ascending colon is more than 8 cm or cecum is more than 12 cm.^[7] Colonic dilation has also been defined as cecal diameter of more than 9 cm or transverse colon diameter of more than 6 cm.^[8] The risk of perforation is proportionate to the increase in diameter of the colon as well as the duration of dilation. Vanek and Al-Salti.^[9] reported that perforation is rare below cecal diameter of 12 cm and is seen in 29% when cecal diameter exceeds 14 cm. Saunders and Kimmey.^[10] found increasing risk of perforation when duration exceeds 6 days. Decompression could be achieved by keeping patient prone, in knee-chest position or in lateral decubitus position with hip elevation.^[11] Neostigmine 2 mg infused intravenously over 5–10 min with cardio-respiratory monitoring is used in ACPO.^[11] Cardiac arrhythmias, respiratory distress and symptoms due to parasympathetic stimulation could occur and injection atropine should be kept on standby.^[11] Role of neostigmine as first line of therapy is undecided and it may be used for delayed resolution or recurrence.^[12] Colonoscopic decompression is an alternative though recurrence could be seen. Attempts to leave a catheter behind in the ascending colon after colonoscopy,^[11] could lead to catheter blockage or migration. Percutaneous endoscopic colostomy or surgical cecostomy have been used to salvage patients for treatment failure.^[11] Monitoring for perforation and peritonitis is recommended because mortality of spontaneous perforation is reported to be 50% or higher.^[11]

Conclusion

Percutaneous endoscopic gastrostomy is a procedure with the risk of complications. Improper technique could lead to organ or bowel injury. Bowel dilation could happen after PEG and pseudo-obstruction could be encountered. In cases of acute stroke, due to brainstem hemorrhage, intestinal pseudo-obstruction could be spontaneous. If PEG has been undertaken, differentiating mechanical obstruction and pseudo-obstruction becomes crucial for clinical outcome.

References

1. Gauderer MW, Ponsky JL, Izant RJ Jr. Gastrostomy without laparotomy: A percutaneous endoscopic technique. *J Pediatr Surg* 1980;15:872-5.
2. Ponsky JL, Gauderer MW. Percutaneous endoscopic gastrostomy: A nonoperative technique for feeding gastrostomy. *Gastrointest Endosc* 1981;27:9-11.
3. Lynch CR, Fang JC. Prevention and management of complications in percutaneous endoscopic gastrostomy (PEG) tubes. In: Parrish CR, editor. *Nutrition Issues in Gastroenterology*. Series No. 22. Practical Gastroenterology; 2004. p. 66-76.
4. Schrag SP, Sharma R, Jaik NP, Seamon MJ, Lukaszczyk JJ, Martin ND, et al. Complications related to percutaneous endoscopic gastrostomy (PEG) tubes. A comprehensive clinical review. *J Gastrointest Liver Dis* 2007;16:407-18.
5. Stellato TA, Gauderer MW, Ponsky JL. Percutaneous endoscopic gastrostomy following previous abdominal surgery. *Ann Surg* 1984;200:46-50.
6. Lee SJ, Na IH, Choi ES, Jung SH, Yoon JS. Occurrence of Intestinal

- Pseudo-obstruction in a Brainstem Hemorrhage Patient. *Ann Rehabil Med* 2012;36:278-81.
7. Preston DM, Lennard-Jones JE, Thomas BM. Towards a radiologic definition of idiopathic megacolon. *Gastrointest Radiol* 1985;10:167-9.
 8. Krajewski K, Siewert B, Eisenberg RL. Colonic dilation. *AJR Am J Roentgenol* 2009;193:W363-72.
 9. Vanek VW, Al-Salti M. Acute pseudo-obstruction of the colon (Ogilvie's syndrome). An analysis of 400 cases. *Dis Colon Rectum* 1986;29:203-10.
 10. Saunders MD, Kimmey MB. Systematic review: Acute colonic pseudo-obstruction. *Aliment Pharmacol Ther* 2005;22:917-25.
 11. ASGE Standards of Practice Committee, Harrison ME, Anderson MA, Appalaneni V, Banerjee S, Ben-Menachem T, *et al.* The role of endoscopy in the management of patients with known and suspected colonic obstruction and pseudo-obstruction. *Gastrointest Endosc* 2010;71:669-79.
 12. Elsner JL, Smith JM, Ensor CR. Intravenous neostigmine for postoperative acute colonic pseudo-obstruction. *Ann Pharmacother* 2012;46:430-5.

How to cite this article: Wagle SD, Divate PG, D'Costa PM, Kalekar T. Acute colon pseudo-obstruction after percutaneous endoscopic gastrostomy: An unusual co-incidence in a case of acute stroke. *J Dig Endosc* 2014;5:164-7.

Source of Support: Nil, **Conflict of Interest:** None declared.

Staying in touch with the journal

1) Table of Contents (TOC) email alert

Receive an email alert containing the TOC when a new complete issue of the journal is made available online. To register for TOC alerts go to www.jdeonline.in/signup.asp.

2) RSS feeds

Really Simple Syndication (RSS) helps you to get alerts on new publication right on your desktop without going to the journal's website. You need a software (e.g. RSSReader, Feed Demon, FeedReader, My Yahoo!, NewsGator and NewzCrawler) to get advantage of this tool. RSS feeds can also be read through FireFox or Microsoft Outlook 2007. Once any of these small (and mostly free) software is installed, add www.jdeonline.in/rssfeed.asp as one of the feeds.