

Postcholecystectomy benign biliary stricture: Surgery is the gold standard

Sadiq S. Sikora

Chief, Department of Surgical Gastroenterology, Manipal Institute of Liver and Digestive Diseases, Manipal Hospital, Bangalore, India

Abstract

Post cholecystectomy bile duct strictures present a challenge to the treating physicians. Advancement in skills and technology offers alternative treatment modalities to the standard surgical repair. Contemporary series of surgical repair by experienced surgeons report excellent long-term results with <5% re-stricture rates. Endoscopic therapy is conceptually flawed, is not applicable to all patients, requires prolonged duration of treatment with multiple interventions. Surgical repair by an experienced surgeon is the “Gold Standard” of care in management of postcholecystectomy bile duct strictures.

Key words

Benign biliary stricture, roux-en-Y hepatico-jejunostomy, endotherapy

It has been estimated that 0.1-0.2% of patients develop a biliary stricture after open cholecystectomy.^[1] Since the introduction of laparoscopic cholecystectomy in 1985, the rates of bile duct injury with resultant stenosis from intraoperative injury have decreased as the surgeons have gained greater experience with the procedure. Currently, the biliary stricture rates vary from 0.2% to 0.7%, although some reports indicate figures as high as 2.8%.^[2-5]


Traditionally, surgical repair of biliary strictures is the standard of care. Surgical treatment involves anastomosing a Roux-en-Y loop of jejunum to the healthy, vascularized and unscarred part of the bile duct. Conventional surgical wisdom dictates avoiding the scarred and unhealthy part of the stricture for anastomosis in order to prevent re-stricture and facilitate healing. Roux-en-Y hepatico-jejunostomy is a one-time, effective and efficient method of treating biliary obstruction due to postoperative bile duct strictures. The hospital stay for most patients ranges from 5 to 10 days.^[6]

Success with endotherapy is not possible because endoscopic

stenting is conceptually flawed – the endobiliary stent forcibly dilates the scarred, unhealthy and ischemic part of the bile duct. The process of healing of an injury goes through a cascade of angiogenesis, epithelialization and connective tissue proliferation with eventual remodeling and healing Figure 1.^[7] In the event of forcible dilatation (as in the dilatation of the stricture) there is bleeding and hematoma formation, scarred tissues are hypoxic and thus there is a proliferative scarring in the process of wound healing resulting in stricture formation [Figure 2]. Thus, long-term patency in the presence of scarring and unhealthy mucosa as in endoscopic treatment is unlikely. Surgical repair, in contrast, results in a mature scar when performed without tension in healthy well-vascularized tissues [Figure 3].

Few studies have directly compared the results of surgical and endoscopic management of benign biliary strictures. The available data come primarily from nonrandomized retrospective series. Davids *et al.* compared 66 patients treated endoscopically with 35 patients treated surgically.^[7] Endoscopic therapy consisted of placement of a single 10-Fr plastic stent after biliary sphincterotomy followed 6 weeks later by exchange for two 10-Fr stents. These stents were exchanged every 3 months for a period of 1 year. Early complications were more common in the surgical group (26% vs. 8%), but complications during the treatment period were more common in the endoscopic group (27% vs. 0%). The rates of recurrence of strictures were similar in the two groups (17% each) at 50 and 42 months, respectively. Tocchi *et al.* reported good or excellent results in postcholecystectomy strictures at 60 months

Access this article online

| | |
|--|---|
| Website: www.jdeonline.in | Quick Response Code  |
| DOI: 10.4103/0976-5042.95029 | |

Address for correspondence:

Dr. Sadiq S. Sikora, MS, FRCS, FACS, Chief, Surgical Gastroenterology, Manipal Institute of Liver and Digestive Diseases, Manipal Hospital, Bangalore, India.
E-mail: drsadiqs@gmail.com

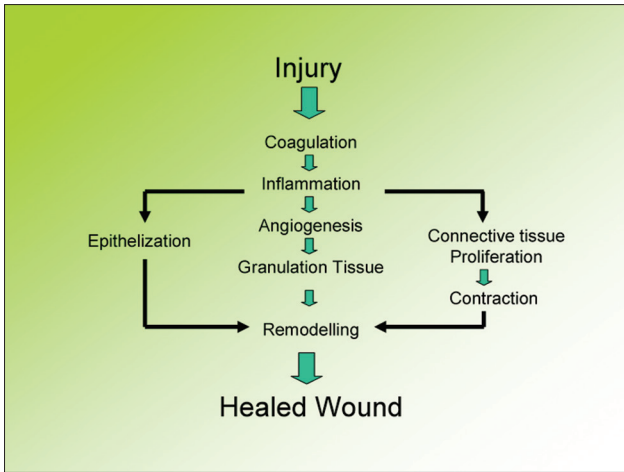


Figure 1: Pathogenesis of injury and healing

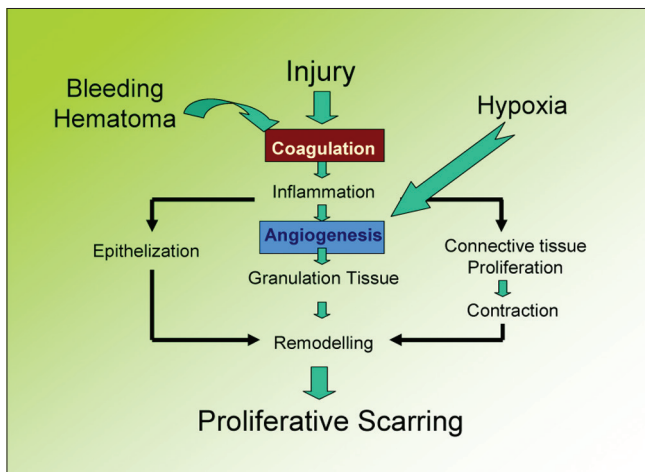


Figure 2: Pathogenesis of scar formation

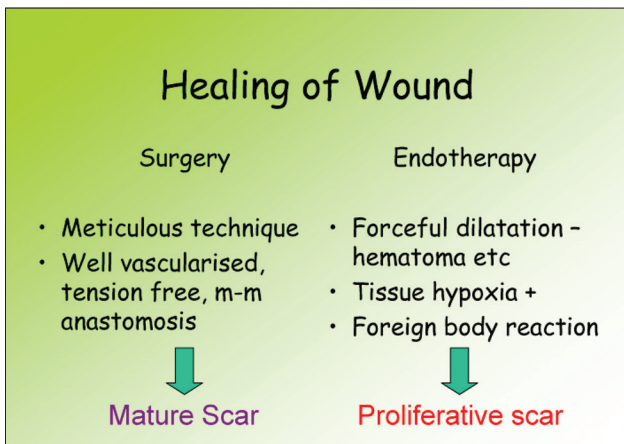


Figure 3: Wound healing in surgical repair versus endotherapy

in 17 of 22 patients treated surgically and 16 of 20 patients treated endoscopically.^[8]

In a long-term follow-up study of patients treated with endoscopic therapy followed over 9 years,^[9] only 59% completed

the treatment and eventually 47% were stricture-free with a relatively short stent removal to restricture period of 2.6 months. In a multicenter French study of postcholecystectomy bile duct strictures, of 99 patients 65 had a successful stent insertion. Of these, only 45(69%) had a partial or total success (45% of the total cases) with only 35 of 65 (54%) with long-term success.^[10]

A more aggressive endoscopic approach may yield better results. The protocol used by Costamagna *et al.*^[11] consisted of endoscopic dilatation followed by insertion of as many 10-Fr plastic biliary stents as could be fitted into the duct. Three months later, these stents were removed and replaced by an increased number of similar stents till the stricture was obliterated on occlusion cholangiogram. Of the 42 patients who completed the protocol, 2 died of unrelated causes; of the remaining 40 patients, 39 were asymptomatic with normal liver function test and normal abdominal ultrasonography at 49 months, and one patient had developed cholangitis. Dragnov *et al.* further supported the idea in their series of 29 patients who were treated with sequential insertion of multiple plastic biliary stents; 62% could be treated successfully at follow-up of 48 months.^[12] Therapy failed in 38% of patients, primarily in those with hilar stricture or related to chronic pancreatitis.

Despite all the publications of endoscopic therapy Table 1, there is a lot of variation as regards the treatment strategy. There is no consensus in terms of a) the number of stents used which varies from 1-6, b) the number and frequency of procedures in a patient, which varies from 2 to 8, and c) duration of treatment which varies from 12 to 24 months. It is also not clear from the data whether a blanket more is better in all parameters mentioned is true or not. Moreover, most endoscopic series have a case selection bias with majority of series includes only patients where the continuity of the duct is maintained, possibly Bismuth type I/II strictures (50-80%).

The major argument against surgical treatment is the high morbidity of 15-25%, mortality of 6-13% and restructure rate between 17 and 25% over a long-term follow-up. This comparison is unfair and biased since the surgical series report all cases of biliary strictures with 50% and more cases categorized as Bismuth Type III-V in most contemporary series. Moreover, the contemporary series from experienced centers have low mortality (0.6-4%) and restricture (5-13%) rates [Table 2]. So the outcomes of worst case surgical series with difficult strictures are compared to the best case Type I/II strictures in endoscopical series, to suggest that both treatment modalities are comparable. In a subanalysis of Type I/II strictures in our series, the morbidity was 5%, mortality was 1.3%, hospital stay of average 6 days and restricture rate of 3.4% over a follow-up of 5 years.

Table 1: Endoscopic treatment of postcholecystectomy benign biliary stricture

| | N | Duration mo | Morbidity (%) | Mortality | Follow up | Good outcome | Rec stricture |
|----------------------------|----|-------------|---------------|-----------|-----------|--------------|---------------|
| Bergman ^[9] | 44 | 12-16 | 40 | - | 9 yrs | 80 | 20 |
| Costamagna ^[11] | 45 | 12 | 10 | 2% | 4 yrs | 89 | 10 |
| Davids ^[7] | 35 | 12 | 35 | - | 42 mo | 80 | 17 |
| Vitale ^[13] | 48 | 12 | 8 | 0 | 30 mo | 91 | 9 |

Table 2: Surgical treatment of postcholecystectomy benign biliary stricture

| | N | Type I/II (%) | Failure (%) | Mortality (%) | Follow-up |
|--------------------------|-----|---------------|-------------|---------------|-----------|
| Lillemoe ^[14] | 156 | 45 | 9.2 | 0.6 | 4.9 yrs |
| Walsh ^[15] | 144 | 50 | 11 | 4 | 5.2 yrs |
| Chapman ^[16] | 122 | 39 | 13 | 1.8 | 7.2 yrs |
| Sikora | 300 | 48 | 4.8 | 1.3 | 7.5 yrs |

Long-term stenting as recommended in most protocols is associated with significant complications in the form of stent migration and or fever, jaundice, pain and cholangitis leading to secondary biliary cirrhosis. Moreover, morphological changes in the form of narrowing of the ductal lumen, thick walls and increased grade of fibrosis and inflammation of the bile duct have been documented by us.^[17] Therefore, the ill effects of long-term stenting need to be documented by close follow-up in this group of patients.

Although, compared to surgery, endoscopic treatment has the advantage of being less 'invasive' but it is less effective, needs multiple hospital admissions, and is certainly not suitable for all patients. In patients with strictures affecting the region of biliary bifurcation, complete transections and in those with significant loss of length of bile duct with or without associated ischemia, endoscopic stenting has a high chance of failure. Endoscopic management is ideal for patients who have bile leaks from cystic duct stump or from small lateral injuries of the bile duct. Endoscopic treatment may also be feasible in the subgroup of patients with portal hypertension, severe associated medical diseases precluding surgery provided that the anatomy is conducive for the intervention.

There are no randomized controlled trials comparing surgical and endoscopic treatment of postoperative biliary strictures. Comparisons are difficult because of variable criteria for selecting patients, varying duration of follow-up, and absence of uniform criteria for defining successful treatment. In a retrospective study of 157 patients with postoperative biliary strictures, endoscopic stenting was compared with surgery.^[18] Intention-to-treat analysis showed that surgery provides better long-term outcome because patients with total obstruction are not amenable to endoscopic stenting. In a case control study of 42 patients with postcholecystectomy stricture, as compared to endoscopic treatment surgery gave better long-term results.^[8] Assessment of quality of life after bile duct injury has also shown that duration of treatment is an

important independent prognostic factor, with prolonged treatment, like repeated endoscopic stenting, having significant psychological impact.^[19]

In summary, it is fair to conclude that surgical repair is the "Gold standard" for patients with postcholecystectomy benign biliary stricture, especially so, for the subset of patients (Bismuth Type I/II) being considered for endoscopic therapy. In experienced centers the results of surgical repair are excellent with more than 90% success rate over long-term follow-up. Endoscopic therapy is certainly feasible in a subset of patients with favorable anatomy or those who are high risk for surgery due to associated medical conditions, with the caveat that prolonged duration of treatment and multiple interventions are the norm with long-term success rates ranging from 47 to 70%.

References

- Deziel DJ. Complications of cholecystectomy. Incidence, clinical manifestations, and diagnosis. *Surg Clin North Am* 1994;74:809-23.
- A prospective analysis of 1518 laparoscopic cholecystectomies. The Southern Surgeons Club. *N Engl J Med* 1991;324:1073-8.
- Wherry DC, Marohn MR, Malanoski MP, Hetz SP, Rich NM. An external audit of laparoscopic cholecystectomy in the steady state performed in medical treatment facilities of the Department of Defense. *Ann Surg* 1996;224:145-54.
- Adamsen S, Hansen OH, Funch-Jensen P, Schulze S, Stage JG, Wara P. Bile duct injury during laparoscopic cholecystectomy: A prospective nationwide series. *J Am Coll Surg* 1997;184:571-8.
- Windsor JA, Pong J. Laparoscopic biliary injury: More than a learning curve problem. *Aust N Z J Surg* 1998;68:186-9.
- Sikora SS, Pottakkat B, Srikanth G, Kumar A, Saxena R, Kapoor VK. Postcholecystectomy benign biliary strictures - long-term results. *Dig Surg* 2006; 23:304-12.
- Davids PH, Tanka AK, Rauws EA, van Gulik TM, van Leeuwen DJ, de Wit LT, *et al.* Benign biliary strictures. Surgery or endoscopy? *Ann Surg* 1993;217:237-43.
- Tocchi A, Mazzoni G, Liotta G, Costa G, Lepre L, Miccini M, *et al.* Management of benign biliary strictures: Biliary enteric anastomosis vs endoscopic stenting. *Arch Surg* 2000;135:153-7.
- Bergman JJ, Burgemeister L, Bruno MJ, Rauws EA, Gouma DJ, Tytgat GN, *et al.* Long-term follow-up after biliary stent placement for postoperative bile duct stenosis. *Gastrointest Endosc* 2001; 54:154-61.
- Kassab C, Prat F, Liguory C, Meduri B, Ducot B, Fritsch J, *et al.* Endoscopic management of post-laparoscopic cholecystectomy biliary strictures. Long-term outcome in a multicenter study. *Gastroenterol Clin Biol* 2006;30:124-9.
- Costamagna G, Pandolfi M, Mutignani M, Spada C, Perri V. Long-term results of endoscopic management of postoperative bile duct strictures with increasing numbers of stents. *Gastrointest Endosc* 2001; 54:162-8.
- Draganov P, Hoffman B, Marsh W, Cotton P, Cunningham J. Long-

- term outcome in patients with benign biliary strictures treated endoscopically with multiple stents. *Gastrointest Endosc* 2002; 55:680-6.
13. Vitale GC, Tran TC, Davis BR, Vitale M, Vitale D, Larson G. Endoscopic management of postcholecystectomy bile duct strictures. *J Am Coll Surg* 2008;206:918-23; discussion 924-5.
 14. Lillemoe KD, Melton GB, Cameron JL, Pitt HA, Campbell KA, Talamini MA, *et al.* Postoperative bile duct strictures: Management and outcome in the 1990s. *Ann Surg* 2000;232:430-41.
 15. Walsh RM, Henderson JM, Vogt DP, Brown N. Long-term outcome of biliary reconstruction for bile duct injuries from laparoscopic cholecystectomies. *Surgery* 2007;142:450-6; discussion 456-7.
 16. Chapman WC, Havelly A, Blumgart LH, Benjamin IS. Postcholecystectomy bile duct strictures: Management and outcome in 130 patients. *Arch Surg* 1995;130:597-602; discussion 602-4.
 17. Waghlikar GD, Sikora SS, Pandey R, Prasad KK, Kumar A, Saxena R, *et al.* Morphological changes in bile ducts following preoperative biliary stenting. *Indian J Gastroenterol* 2003;22:166-9.
 18. De Palma GD, Persico G, Sottile R, Puzziello A, Iuliano G, Salvati V, *et al.* Surgery or endoscopy for treatment of postcholecystectomy bile duct strictures? *Am J Surg* 2003;185:532-5.
 19. Boerma D, Rauws EA, Keuleman YC, Bergman JJ, Obertop H, Huibregtse K, *et al.* Impaired quality of life 5 years after bile duct injury during laparoscopic cholecystectomy. A prospective analysis. *Ann Surg* 2001;234:750-7.

How to cite this article: Sikora SS. Postcholecystectomy benign biliary stricture: Surgery is the gold standard. *J Dig Endosc* 2012;3:36-9.

Source of Support: Nil. **Conflict of Interest:** None declared.

Author Help: Reference checking facility

The manuscript system (www.journalonweb.com) allows the authors to check and verify the accuracy and style of references. The tool checks the references with PubMed as per a predefined style. Authors are encouraged to use this facility, before submitting articles to the journal.

- The style as well as bibliographic elements should be 100% accurate, to help get the references verified from the system. Even a single spelling error or addition of issue number/month of publication will lead to an error when verifying the reference.
- Example of a correct style
Sheahan P, O'leary G, Lee G, Fitzgibbon J. Cystic cervical metastases: Incidence and diagnosis using fine needle aspiration biopsy. *Otolaryngol Head Neck Surg* 2002;127:294-8.
- Only the references from journals indexed in PubMed will be checked.
- Enter each reference in new line, without a serial number.
- Add up to a maximum of 15 references at a time.
- If the reference is correct for its bibliographic elements and punctuations, it will be shown as CORRECT and a link to the correct article in PubMed will be given.
- If any of the bibliographic elements are missing, incorrect or extra (such as issue number), it will be shown as INCORRECT and link to possible articles in PubMed will be given.