

Computer-designed selective laser sintering surgical guide and immediate loading dental implants with definitive prosthesis in edentulous patient: A preliminary method

Giovanni Di Giacomo^{1,2}, Jorge Silva², Rodrigo Martines³, Sergio Ajzen¹

¹Department of Diagnostic Imaging, School of Medicine, Federal University of São Paulo, São Paulo, Brazil,

²Department of 3D Technologies, Center of Information Technology Renato Acher, Campinas, Brazil.

³Department of Dental Implant, Professional Improvement School, Paulista Dental Association, São Paulo, Brazil

Correspondence: Dr. Giovanni Di Giacomo
Email: giovannidi@uol.com.br

ABSTRACT

Objective: The aim of this study was to analyze a preliminary method of immediately loading dental implants and a definitive prosthesis based on the computer-aided design/computer-aided manufacturing systems, after 2 years of clinical follow-up. **Materials and Methods:** The study comprised one patient in good general health with edentulous maxilla. Cone beam computer tomography (CBCT) was performed using a radiographic template. The surgical plan was made using the digital imaging and communications in medicine protocol with ImplantViewer (version 1.9, Anne Solutions, Sao Paulo, SP, Brazil), the surgical planning software. These data were used to produce a selective laser sintering surgical template. A maxilla prototype was used to guide the prosthesis technician in producing the prosthesis. Eight dental implants and a definitive prosthesis were installed on the same day. A post-operative CBCT image was fused with the image of the surgical planning to calculate the deviation between the planned and the placed implants positions. Patient was followed for 2 years. **Results:** On average, the match between the planned and placed angular deviation was within $6.0 \pm 3.4^\circ$ and the difference in coronal deviation was 0.7 ± 0.3 mm. At the end of the follow-up, neither the implant nor the prosthesis was lost. **Conclusions:** Considering the limited samples number, it was possible to install the dental implants and a definitive prosthesis on the same day with success.

Key words: Computer-assisted surgery, dental implants, immediate loading dental implant

INTRODUCTION

Computer-aided design/computer-aided manufacturing (CAD/CAM) systems have been used with increasing frequency in implantology. The software joins prosthetic planning and bone anatomic disposal data^[1] (i.e., surgical planning is based on the previous prosthetic planning^[1]), which results in reduced surgical time and lessens the post-operative discomfort for the patient.^[2-4]

In the last few years, the use of immediate loading in dental implants associated with CAD/CAM systems has been a highly successful procedure and reported cumulative survival rates for implants and prostheses of 98.33% and 91.66%, respectively.^[5] One of the major contributors to the success of this procedure has been its greater level of dental implant primary stability.^[4]

The deviations observed in guided surgeries can be influenced by an association of different mistakes that

How to cite this article: Giacomo GD, Silva J, Martines R, Ajzen S. Computer-designed selective laser sintering surgical guide and immediate loading dental implants with definitive prosthesis in edentulous patient: A preliminary method. *Eur J Dent* 2014;8:100-6.

Copyright © 2014 Dental Investigations Society.

DOI: 10.4103/1305-7456.126257

can occur during any phase of the procedure, from image manipulation to the positioning of the guides during the surgery.^[1,5-12] Surgeons must be aware that angular and linear deviations are to be expected.^[13,14]

A prospective clinical study with 21 patients was undertaken to determine the surgical guide accuracy that could be obtained with a rapid prototype technique. The guides were produced based on virtual surgical planning using stereolithography technology. After the fusion of the pre- and post-operative images, a variation was observed of $4.9 \pm 2.36^\circ$ in angular deviation and 1.22 ± 0.85 mm in coronal deviation.^[10]

In another clinical study of 25 patients, the following observations were made: (1) computer-aided oral implant surgery resulted in a high rate (96%) of implant survival; and (2) deviations from planned implant positions existed in the coronal and apical portions of the implants and in the implant angulation. The mean deviations were < 2.0 mm in any direction and $< 8.0^\circ$.^[13]

The study evaluated the accuracy and complications that arose from using selective laser sintering (SLS) surgical guides for flapless dental implant placement and immediate definitive prosthesis installation. A total of 60 dental implants and 12 prostheses were installed in 12 patients and these patients were followed-up for 30 months. The mean (standard deviation) angular, coronal and apical deviations were 6.53 (4.31°), 1.35 (0.65) mm and 1.79 (1.01) mm, respectively. The complication rate was 34.4%. Hence, computer-aided dental implant surgery still requires improvement and should be considered to be in the developmental stage.^[5]

A systematic review of the accuracy of computerized templates, based on dental implant procedures, concluded that these techniques showed high implant survival rates ranging from 91% to 100%. However, a considerable number of techniques related to perioperative complications were observed. Preclinical and clinical studies have indicated a reasonable mean accuracy, with relatively high maximum deviations.^[15]

This study introduces a technique for immediate dental implant loading with definitive prostheses, using a CAD/CAM system.

MATERIALS AND METHODS

This study was approved by the Institutional Ethics Committee of Sao Paulo Hospital (no. 0833/06) and informed consent was obtained from the patients.

Clinical evaluation phase and surgical and prosthetic planning

Clinical, occlusal and panoramic radiographic evaluations were performed in a 65-year-old non-smoking female patient in good general health with edentulous maxilla. Patient presented with no exclusion criteria (i.e., radiotherapy, chemotherapy, chronic systemic diseases or bruxism). After an initial evaluation, a new denture was created and duplicated to produce a radiographic template, which was composed of 10% of high-density barium and 90% varnish. An inter-occlusal support was made to separate the maxillary arcs and to stabilize the template during the cone beam computer tomography (CBCT) scan (i-CAT™, Xoran Technologies, Ann Arbor, Michigan/Imaging Sciences International, Hatfield, PA, USA) [Figure 1]. The data were recorded using the digital imaging and communications in medicine (DICOM) protocol. The axial plan was adjusted parallel to the occlusal plane and overlapping sections measuring 1.0 mm in thickness were obtained. In dedicated surgical planning software, these DICOM files were opened on a personal computer to segment the structures, followed by soft-tissue removal and virtual implant placement. The positioning of the implants was based on images of the virtual dental arc, which were obtained using the radiographic template. Nine implants were virtually placed and the virtual surgical planning was recorded in.stl files [Figure 2].

Image manipulation phase and surgical guide production

The files were sent to the Information Technology Center Renato Acher, Science and Technology Ministry, Campinas, Brazil. Using CAD software, three files were created: The dental arc (white); virtual implants with their occlusal extensions (red) and bone tissue (brown). A fourth file was created from a three-dimensional (3D) scan of the maxilla (cast model). Association of the virtual implant extension and the bone tissue images was performed to build the virtual surgical guide [Figures 2 and 3].

Using SLS rapid prototyping technology (Sinterstation^R HiQ™, 3D Systems, Rock Hill, SC, USA), the prototypes of the templates and the maxilla were produced [Figure 4].

Prosthesis laboratory phase

For the prosthesis laboratory phase, another prototype was produced with the fusion of the gum ridge, the implant extension and the 3D images from the dental arc. This model was settled on an articulator [Figure 5], the vertical dimension was registered, the dental arc

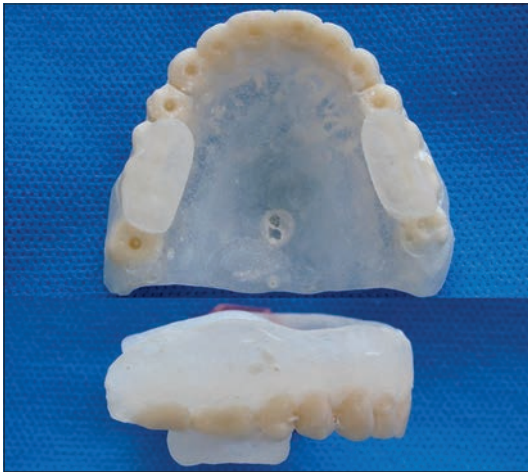

Figure 1: Radiographic template: Occlusal and lateral view

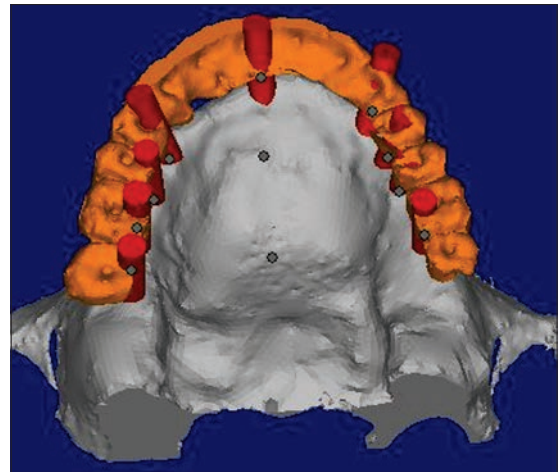


Figure 2: Surgical planning

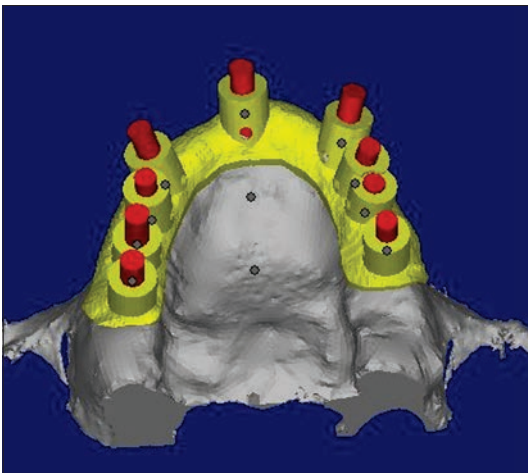


Figure 3: Virtual surgical guide

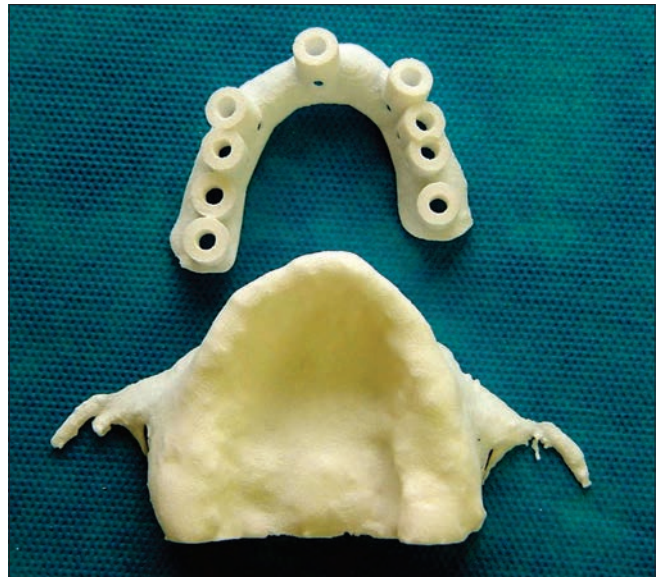


Figure 4: Prototype of guide and the maxilla

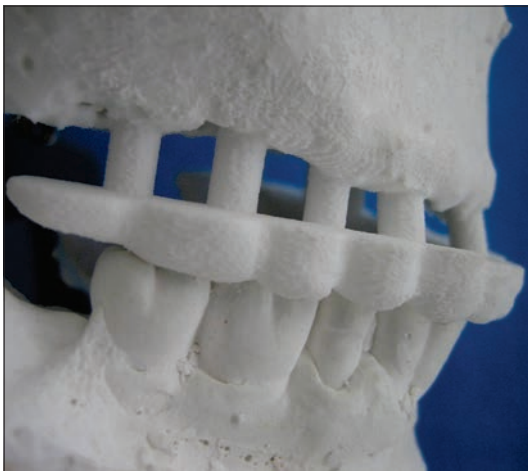

Figure 5: The model (prototype) of the maxilla in the articulator

was removed and the prosthesis technician built wax-up dental arc [Figure 6].

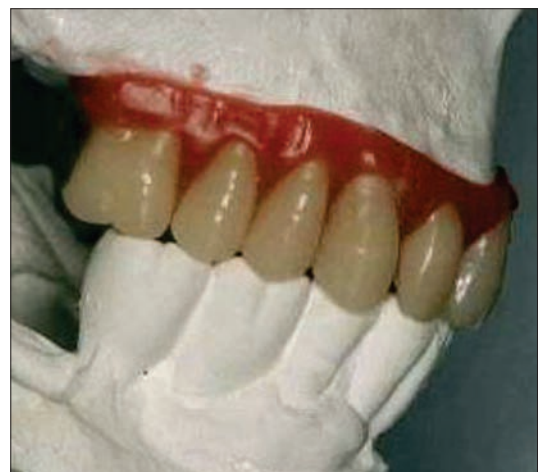

Figure 6: Wax-up of the dental arc in the articulator

Surgical phase

After local anesthesia, a mucoperiosteal flap was done. The guide was positioned [Figure 7] and the osteotomies were prepared using 2.0-mm drills [Figure 8]. Next, the inner 2.2-mm cylinders were removed and 2.8-mm drills (pilot and cylinder) were used. The template was removed and implants (Self-Tapping External Hex AS Technology, São Paulo, SP, Brazil) were placed, with diameters of 3.75 mm and 4.0 mm [Figure 9].

Eight implants were placed with insertion torque > 35 Newton-centimeters (N-cm). One implant, which was placed with 10 N-cm of torque, was removed. Then, the conical abutments (E-Fix, AS Technology, Sao Paulo, SP, Brazil) were placed (Pilar Microunit, AS Technology, São Paulo, SP, Brazil) with 20 N-cm of torque. Immediately after the dental implant placement, pickup copings were mounted, followed by impression with an individual tray and silicone material (XantoprenR VL Plus, Heraeus Kulzer, Sao Paulo, SP, Brazil). This model set was sent to a

prosthesis laboratory for laser joining of the metal cylinders (UCLA) and the titanium bar [Figure 10]. Then, the fitting evaluation of the framework was performed in the patient's mouth, with the dental arc partially varnished.

The prosthesis was fixed over the dental implants [Figure 11] after the 8 h surgery.

Two criteria were used to evaluate the protocol: Accuracy and clinical evaluation.

Accuracy evaluation

A new CBCT was obtained from the patient after the surgery. Using Rhinoceros software (version 4.0, McNeel, Seattle, WA, USA), 3D images of the initial surgery planning and the post-operative CBCT were fused to accurately evaluate the process [Figure 12]. The angular deviation was measured as the 3D angle between the longitudinal axes of the planned and placed implants. To determine the lateral deviation,

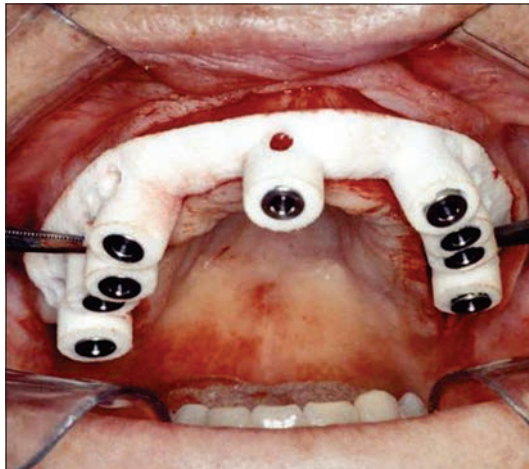


Figure 7: Guide in position

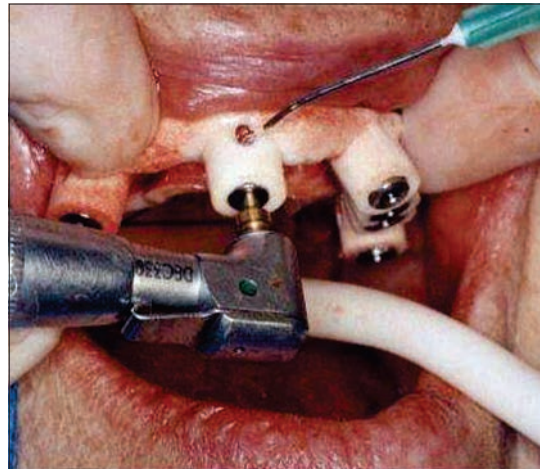


Figure 8: Drilling

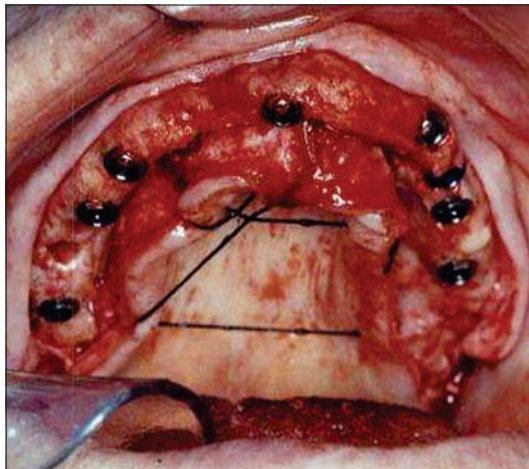


Figure 9: Dental implants placed



Figure 10: Laser joint details

we defined a reference plane that was perpendicular to the longitudinal axis of the planned implant and intersected the coronal (or apical) implant centers. The lateral deviation was calculated as the distance between the coronal (or apical) center of the planned implant and the intersection point of the longitudinal axis of the placed implant and the reference plane.^[5]

Clinical evaluation

After fixing the prosthesis over the dental implants, clinical evaluation performed every 6 months for 2 years. At the clinical evaluation, the prosthesis was removed to evaluate the implants, abutments and gum tissue conditions.

RESULTS

The average matches between the planned and placed implants positions were 0.68 ± 0.35 mm in the coronal position, 1.91 ± 0.94 mm in the apical positions and $6.01 \pm 3.44^\circ$ in the angle observed between the axes of the planned and placed implants Table 1.

A panoramic radiograph [Figure 13] was obtained 2 years post-surgery; the prosthesis was removed and it was possible to observe the stability of the abutments and implants. Soft-tissue inflammation was present in some peri-implant areas and the patient was refocused on a hygiene technique.

DISCUSSION

All processes used in this technique were based on the CBCT images and information about the disposal of bone and the prosthetic plan was available from the radiographic template. Images of the dental arc guided the positioning of the implants. Using this information, two prototypes were produced: The surgical guide and another guide to be used by the

prosthetic laboratory. All processes were based on a sequence of interdependent phases. Surgical guide use still leads to deviations from the plan. The following differences might be connected to the handling of

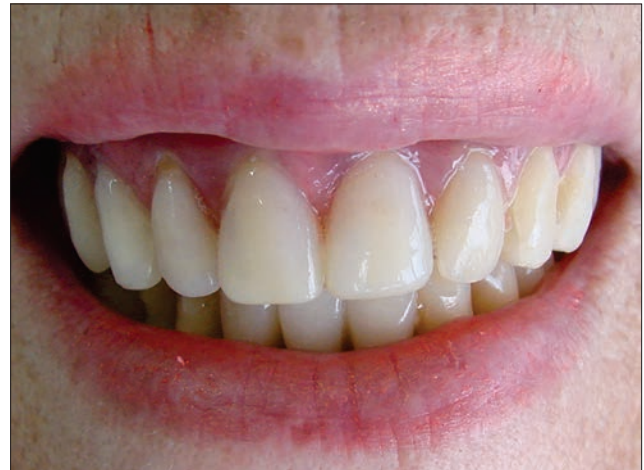

Figure 11: Prosthesis installed




Figure 12: Image of the placed implants in blue and the planned implants in red

Table 1: Deviation between the planned versus placed dental implant positions				
Deviations	N°	Coronal (mm)	Angular (°)	Apical (mm)
Patient 1	18	0.64	6.72	1.41
	14	0.58	2.09	1.75
	13	0.9	5.82	2.12
	11	0.23	10.82	3.45
	22	0.25	7.12	2.58
	23	1.16	1.65	0.89
	24	0.61	3.63	0.6
	27	1.09	10.22	2.5
Average	8	0.68	6.01	1.91
Standard deviation		0.35	3.44	0.94

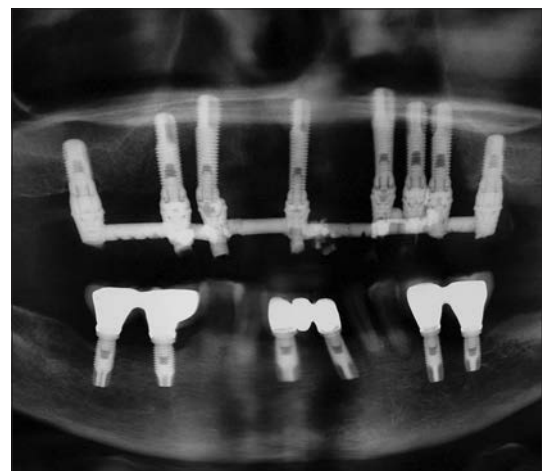


Figure 13: Panoramic radiograph, 2-year follow-up

the computer tomography: The positioning of the radiographic template, image segmentation, modeling of the images and prototype production, stability of the guide on the tissue or fitting of the metal sleeves.^[7,8]

The perception of the texture and ridge of the bone tissue was crucial for the good result; in this case, the tissue presented low resistance to the initial drilling. Therefore, we limited the drilling diameter to 2.8 mm for the 3.75 and 4.0 mm implants, which resulted in insertion torque greater than 35 N-cm. We believe that in the guided surgery, the failure rate decreases as experience increases. This change was attributed to the learning curve.^[16,17]

Note an important matter concerning the guide stability,^[1] in this clinical case, it involved the entire alveolar ridge, which resulted in good posterior and lateral stability, thereby providing confidence during the drilling process. Furthermore, the procedure can be more accurately with screw fixation.^[18]

The differences between the placed and planned implants positions could be resolved with a post-operative molding. The infrastructure of the prosthesis was produced based on the positioning of the placed implants and not on the virtual planning. With these procedures, the recovery time is longer; however, the result of the placement of the prosthesis is more predictable and reduces the tension on the placed implants,^[5] minimizing the occurrence of prosthetic complications that include substructure fracture^[19] and screw loosening.^[20]

One key for the success of the immediate loading technique might be using a rigid connection between the implants.^[21] Contrary to the study that used metal wires between the abutments,^[22] we chose a titanium bar with a 3.0-mm diameter, which was thicker, with the goal of a less flexible frame.

The simplification of this technique, the reduced treatment time and the possibility of using different implant systems made this process more versatile; it adapted to the necessities and preferences of the professionals involved.

Beyond the implant survival rate, the computer technology needs also present the practicality in clinical practice,^[23] that can be observed in this preliminary method.

Studies of CAD/CAM systems in implantology could lead to reduced costs, increased accuracy, reduced

surgical times and risks during surgery and decreased post-operative discomfort.^[5,7]

CONCLUSIONS

Considering the limited number of samples in this pilot study, the presented CAD/CAM system protocol could facilitate the same-day installation of implants and permanent prostheses.

REFERENCES

1. Di Giacomo GA, Cury PR, de Araujo NS, Sendyk WR, Sendyk CL. Clinical application of stereolithographic surgical guides for implant placement: Preliminary results. *J Periodontol* 2005;76:503-7.
2. van Steenberghe D, Glauser R, Blombäck U, Andersson M, Schutyser F, Pettersson A, *et al.* A computed tomographic scan-derived customized surgical template and fixed prosthesis for flapless surgery and immediate loading of implants in fully edentulous maxillae: A prospective multicenter study. *Clin Implant Dent Relat Res* 2005;7 Suppl 1:S111-20.
3. Arisan V, Karabuda CZ, Ozdemir T. Implant surgery using bone-and mucosa-supported stereolithographic guides in totally edentulous jaws: Surgical and post-operative outcomes of computer-aided vs. standard techniques. *Clin Oral Implants Res* 2010;21:980-8.
4. Esposito M, Grusovin MG, Willings M, Coulthard P, Worthington HV. The effectiveness of immediate, early, and conventional loading of dental implants: A Cochrane systematic review of randomized controlled clinical trials. *Int J Oral Maxillofac Implants* 2007;22:893-904.
5. Sanna AM, Molly L, van Steenberghe D. Immediately loaded CAD-CAM manufactured fixed complete dentures using flapless implant placement procedures: A cohort study of consecutive patients. *J Prosthet Dent* 2007;97:331-9.
6. Di Giacomo GA, da Silva JV, da Silva AM, Paschoal GH, Cury PR, Szarf G. Accuracy and complications of computer-designed selective laser sintering surgical guides for flapless dental implant placement and immediate definitive prosthesis installation. *J Periodontol* 2012;83:410-9.
7. Van Assche N, van Steenberghe D, Quirynen M, Jacobs R. Accuracy assessment of computer-assisted flapless implant placement in partial edentulism. *J Clin Periodontol* 2010;37:398-403.
8. Vercruyssen M, Jacobs R, Van Assche N, van Steenberghe D. The use of CT scan based planning for oral rehabilitation by means of implants and its transfer to the surgical field: A critical review on accuracy. *J Oral Rehabil* 2008;35:454-74.
9. Viegas VN, Dutra V, Pagnoncelli RM, de Oliveira MG. Transference of virtual planning and planning over biomedical prototypes for dental implant placement using guided surgery. *Clin Oral Implants Res* 2010;21:290-5.
10. Ozan O, Turkyilmaz I, Ersoy AE, McGlumphy EA, Rosenstiel SF. Clinical accuracy of 3 different types of computed tomography-derived stereolithographic surgical guides in implant placement. *J Oral Maxillofac Surg* 2009;67:394-401.
11. Ersoy AE, Turkyilmaz I, Ozan O, McGlumphy EA. Reliability of implant placement with stereolithographic surgical guides generated from computed tomography: Clinical data from 94 implants. *J Periodontol* 2008;79:1339-45.
12. Pettersson A, Kero T, Gillot L, Cannas B, Fäldt J, Söderberg R, *et al.* Accuracy of CAD/CAM-guided surgical template implant surgery on human cadavers: Part I. *J Prosthet Dent* 2010;103:334-42.
13. Pettersson A, Komiyama A, Hultin M, Näsström K, Klinge B. Accuracy of virtually planned and template guided implant surgery on edentate patients. *Clin Implant Dent Relat Res* 2012;14:527-37.
14. Valente F, Schirotti G, Sbrenna A. Accuracy of computer-aided oral implant surgery: A clinical and radiographic study. *Int J Oral Maxillofac Implants* 2009;24:234-42.
15. D'haese J, Van De Velde T, Komiyama A, Hultin M, De Bruyn H. Accuracy and complications using computer-designed stereolithographic surgical guides for oral rehabilitation by means of dental implants: A review of the literature. *Clin Implant Dent Relat Res* 2012;14:321-35.

16. Schneider D, Marquardt P, Zwahlen M, Jung RE. A systematic review on the accuracy and the clinical outcome of computer-guided template-based implant dentistry. *Clin Oral Implants Res* 2009;20 Suppl 4:73-86.
17. Campelo LD, Camara JR. Flapless implant surgery: A 10-year clinical retrospective analysis. *Int J Oral Maxillofac Implants* 2002;17:271-6.
18. Kinsel RP, Liss M. Retrospective analysis of 56 edentulous dental arches restored with 344 single-stage implants using an immediate loading fixed provisional protocol: Statistical predictors of implant failure. *Int J Oral Maxillofac Implants* 2007;22:823-30.
19. Arisan V, Karabuda ZC, Ozdemir T. Accuracy of two stereolithographic guide systems for computer-aided implant placement: A computed tomography-based clinical comparative study. *J Periodontol* 2010;81:43-51.
20. Vohra F, Al Fawaz A. Repair of a fractured implant overdenture gold bar: A clinical and laboratory technique report. *Eur J Dent* 2013;7:382-6.
21. Gokcen-Rohlig B, Yaltirik M, Ozer S, Tuncer ED, Evlioglu G. Survival and success of ITI implants and prostheses: Retrospective study of cases with 5-Year follow-up. *Eur J Dent* 2009;3:42-9.
22. Degidi M, Nardi D, Piattelli A. Prospective study with a 2-year follow-up on immediate implant loading in the edentulous mandible with a definitive restoration using intra-oral welding. *Clin Oral Implants Res* 2010;21:379-85.
23. Jung RE, Schneider D, Ganeles J, Wismeijer D, Zwahlen M, Hämmerle CH, *et al.* Computer technology applications in surgical implant dentistry: A systematic review. *Int J Oral Maxillofac Implants* 2009;24 Suppl: 92-109.

Access this article online	
<p>Quick Response Code:</p> 	<p>Website: www.eurjdent.com</p>
<p>Source of Support: Nil. Conflict of Interest: None declared</p>	