

# Efficiency of the Self Adjusting File, WaveOne, Reciproc, ProTaper and hand files in root canal debridement

K. Meltem Topcu<sup>1</sup>, Ertugrul Karatas<sup>1</sup>, Damla Ozsu<sup>1</sup>, Ibrahim Ersoy<sup>2</sup>

**Correspondence:** Dr. Ertugrul Karatas  
Email: dtertu@windowslive.com

<sup>1</sup>Department of Restorative Dentistry and Endodontics, Faculty of Dentistry, Ataturk University, Erzurum, Turkiye,

<sup>2</sup>Department of Restorative Dentistry and Endodontics, Faculty of Dentistry, Sifa University, Izmir, Turkiye

## ABSTRACT

**Objectives:** The aim of this study was to compare the canal debridement capabilities of three single file systems, ProTaper, and K-files in oval-shaped canals. **Materials and Methods:** Seventy-five extracted human mandibular central incisors with oval-shaped root canals were selected. A radiopaque contrast medium (Metapex; Meta Biomed Co. Ltd., Chungcheongbuk-do, Korea) was introduced into the canal systems and the self-adjusting file (SAF), WaveOne, Reciproc, ProTaper, and K-files were used for the instrumentation of the canals. The percentage of removed contrast medium was calculated using pre- and post-operative radiographs. **Results:** An overall comparison between the groups revealed that the hand file (HF) and SAF groups presented the lowest percentage of removed contrast medium, whereas the WaveOne group showed the highest percentage ( $P < 0.001$ ). The ProTaper group removed more contrast medium than the SAF and HF groups ( $P < 0.05$ ). **Conclusions:** None of the instruments was able to remove the contrast medium completely. WaveOne performed significantly better than other groups.

**Key words:** Metapex, Reciproc, root canal debridement, self-adjusting file, WaveOne

## INTRODUCTION

One of the most important stages in root canal treatment is the preparation of the root canal system, which includes the removal of vital and necrotic tissue, in addition to thorough debridement of the root canal. However, this stage is difficult due to the complex anatomy of the root canal system.<sup>[1]</sup> An oval-shaped root canal is defined as having a maximum diameter of up to 2 times greater than the minimum diameter, which poses a challenge in terms of thorough cleaning, shaping, and obturation.<sup>[2-4]</sup> Various instrumentation techniques have been used to prepare oval canals. However, the conventional hand files (HFs) and nickel-titanium (NiTi) rotary instruments leave parts of the root canal surface unprepared, especially in the case of oval-shaped root canals.<sup>[1,5,6]</sup>

The self-adjusting file (SAF) (ReDent Nova, Ra'anana, Israel) is believed to expand into long oval root canals and therefore carries out canal preparation by circumferentially removing a layer of dentin in oval as well as round canals.<sup>[7]</sup> WaveOne (Dentsply Maillefer, Ballaigues, Switzerland) and Reciproc (VDW GmbH Munich, Germany) files are two new methods that use a reciprocating motion in root canal preparation.

The aim of this study was to compare the debridement capabilities of a WaveOne file (Dentsply Maillefer, Ballaigues, Switzerland) and Reciproc (VDW GmbH, Munich, Germany) in oval-shaped canals with a SAF (ReDent-Nova Ltd., Reanana, Israel), a ProTaper rotary system (Dentsply Maillefer, Ballaigues, Switzerland), and a hand-filling (Mani Inc., Tochigi, Japan) technique. The null hypothesis shows that

**How to cite this article:** Topcu KM, Karatas E, Ozsu D, Ersoy I. Efficiency of the Self Adjusting File, WaveOne, Reciproc, ProTaper and hand files in root canal debridement. Eur J Dent 2014;8:326-9.

Copyright © 2014 Dental Investigations Society.

DOI: 10.4103/1305-7456.137636

there is no difference between the methods in the preparation of oval-shaped root canals.

## MATERIALS AND METHODS

Seventy-five freshly extracted intact human mandibular central incisors, each with a mature apex and a single canal were used for the study. Initial identification of the oval canal was performed radiographically by comparing the proximal and clinical views for each root. Canals with a buccolingual root canal dimension that was more than twice the mesiodistal dimension were selected. Only straight roots or those with a canal curvature of  $<10^\circ$  were included.

In this study, a method, which was used in a previous study was modified for the evaluation of root canal debridement.<sup>[8]</sup> For each tooth, a coronal access cavity was prepared using high-speed diamond burs. Gates Glidden drills #2 and #3 (Dentsply Maillefer, Ballaigues, Switzerland) were used in a low-speed contra-angle handpiece for the purpose of coronal flaring to a level of 2-3 mm below the cemento-enamel junction. After preparation, irrigation was performed with 2.5% NaOCl using a 27-gauge needle (Endo Eze; Ultradent Products Inc., South Jordan, UT) and a 2 mL syringe. Root canals showing a single oval orifice were instrumented with #10 K-files (Mani Inc., Tochigi, Japan) until the tip was just visible at the apex; the working length (WL) was 0.5 mm short of this length. Subsequently, a glide path was established with 10, 15, and 20 K-files using a lubricant (MD-ChelCream Meta Biomed Co. Ltd., Chungcheongbuk-do, Korea) as a lubricant, and 5 mL of 2.5% NaOCl was used to irrigate the canals between files. A final rinse of 5 mL sterile saline was then delivered. The canals were dried with paper points, and a radiopaque contrast medium (Metapex; Meta Biomed Co., Ltd., Chungcheongbuk-do, Korea) was introduced into the canal systems using a lentulo spiral. The teeth were numbered and a small groove was placed on the proximal surface of all specimens to facilitate standardized positioning of the tooth for radiographic imaging. Radiographs were taken at buccolingual and mesiodistal projections to verify complete filling of the root canal system. If there were any voids present, the contrast medium was reintroduced and radiographs were taken until those canal spaces were filled.

Teeth were randomly assigned to 5 groups ( $n = 15$ ) according to the instrumentation technique used.

### Hand file

Stainless steel K-files were used, and the canal was enlarged to a final apical size of #40.

### ProTaper

Root canal instrumentation was performed up to finishing file F4 in a sequence according to the manufacturer's guidelines. The ProTaper universal instruments were driven at 300 rpm with 2N/cm of torque using an X-Smart Motor (Dentsply, Maillefer, Ballaigues, Switzerland).

### Reciproc

R40 Reciproc files with a size of 40 and a taper of 0.06 over the first 3 mm were used in a reciprocating, slow, in- and out-pecking motion according to the manufacturer's instructions using the VDW Silver Reciproc (VDW GmbH, Munich, Germany). The instrument reached to the WL with 3 in- and out-pecking motions and a new instrument was used for each tooth.

### WaveOne

Teeth were instrumented using WaveOne primary files 40/0.06 according to the manufacturer's instructions that came with the VDW Silver Reciproc. The instrument reached to the WL with 3 in- and out-pecking motions and a new instrument was used for each tooth.

### Self-adjusting file

The SAF file was operated in each canal for 4 min with continuous irrigation. The file was used with a vibrating handpiece head (RDT3; ReDent-Nova Reanana, Israel) at 0.4 mm amplitude and 5000 vibrations/min. An in- and out-manual motion was continuously performed, and irrigation with sterile saline was applied through the hollow file throughout the 4 min of the operation. The irrigant was continuously provided by a Vatea peristaltic pump (ReDent-Nova Reanana, Israel) at a rate of 5 mL/min. A total of 20 mL sterile saline was used during instrumentation in each group and a new instrument was used for each tooth.

Seventy-five buccolingula radiographs were taken after instrumentation, and the pre- and post-operative radiographs were transferred to the computer (Adobe Photoshop CS5) [Figure 1]. Pre- and post-operative radiopaque areas were calculated from the apex to 10 mm for each tooth and the percentage of contrast medium removed was quantified.

One-way analysis of variance and Tukey's *post-hoc* tests were used to compare the percentage of contrast

medium removed in all groups at a confidence level of 95% ( $P = 0.05$ ). All statistical analyses were performed using IBM® SPSS® Statistics 20 software (IBM SPSS Inc., Chicago, USA).

## RESULTS

The percentage of contrast medium removed in all groups is shown in Figure 2. An overall comparison between groups revealed that the HF and SAF groups presented the lowest percentage of removed contrast medium, whereas the WaveOne group showed the highest ( $P < 0.001$ ). There were no significant differences between the ProTaper and Reciproc groups ( $P = 0.938$ ). Furthermore, the ProTaper group removed more contrast medium than the SAF and HF groups ( $P < 0.05$ ). The Reciproc group showed significant differences compared to the HF group only ( $P < 0.05$ ).

## DISCUSSION

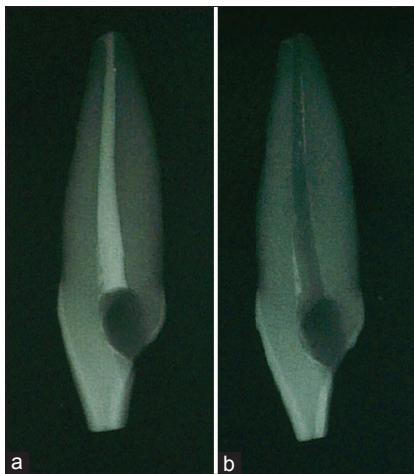
The aim of this study was to compare the canal debridement capabilities of three single file systems, ProTaper, and K-files in oval-shaped canals. The results indicate that none of the instruments could remove the contrast medium completely. This finding is similar to the findings in the previous studies.<sup>[9-11]</sup> Despite studies reporting that HF's are better than rotary files in preparing oval root canals, the present study demonstrates that the HF group presented the most unprepared areas on the canal walls.<sup>[12]</sup> The results obtained in those previous studies were probably due to the fact that H-files were used in the preparation stage.

In this study, the SAF showed better performance than the HF group; however, there was no statistically

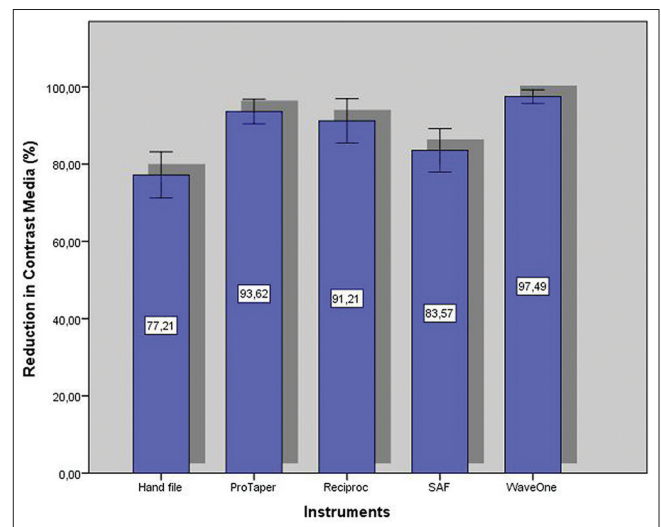
significant difference between them. The SAF file is composed of a hollow cylinder with a metal lattice, and its surface is treated to render it abrasive.<sup>[8]</sup> The shape of the SAF file and its back and forth gridding motion allow it to expand into the canal and remove a layer of dentin.<sup>[13]</sup> Ruckman *et al.*<sup>[8]</sup> have reported that in the 0-5 mm segment, the SAF removed more contrast medium than the HF's ( $P > 0.05$ ), and similarly, in this study, the SAF showed better performance than the HF group, although no significant difference.

In this study, the WaveOne, Reciproc, and ProTaper files removed more radiopaque medium from oval root canals than the SAF and HF's. Albrecht *et al.*<sup>[14]</sup> evaluated various sizes and tapers of rotary files and reported that an increased file taper leads to root canal debridement. In this study, WaveOne, Reciproc, ProTaper, and HF's were used with a taper of 40.08, 40.06, 40.06, and 40.02, respectively. Previous studies reported that the SAF has a taper similar in size to 40.02.<sup>[15,16]</sup> In this study, the better performances of WaveOne, Reciproc, and ProTaper files compared to the SAF and HF's may have been due to the fact that their tapers were higher.

The WaveOne files are produced with the M-Wire NiTi alloy, using a heat procedure carried out at varying temperatures.<sup>[17,18]</sup> The WaveOne system has a similar tip diameter to the ProTaper files, but WaveOne is used with a reciprocating motion, whereas ProTaper is used with a rotary motion.<sup>[18]</sup> Hilaly Eid and Wanees Amin<sup>[12]</sup> suggest that the reciprocating motion simulates a balanced force motion, and reported that circumferential filing



**Figure 1:** Example of pre- and post-operative images. (a) Metapex fill, verification. (b) Postoperative radiograph showing remaining Metapex



**Figure 2:** Comparison of Hand file, ProTaper, Reciproc, WaveOne and self-adjusting file in removal of contrast medium from oval-shaped root canals



removes more dentin than balanced force motion in oval root canals. Despite this previous study, the WaveOne group removed more contrast medium in this study than the ProTaper method ( $P > 0.05$ ); its higher taper and reverse cutting blade design may explain this result.

In this study, Metapex was used as a contrast medium due to its radiopacity and ease of placement, which facilitated a two-dimensional comparison of different file systems. Similarly, Ruckman *et al.*<sup>[8]</sup> compared the SAF file with hand and rotary files using Vitapex as a contrast medium. Although, this study obtained quantitative data, it is not as accurate as the data provided by micro-computed tomography, which allows three-dimensional analyses.<sup>[19,20]</sup>

During instrumentation with the SAF group, the Vatae irrigation system was used for 4 min, providing continuous irrigation at a rate of 5 mL/min; therefore, an irrigant quantity of 20 mL was used in the other groups to allow comparison with the SAF group. Pilot studies show that sodium hypochlorite dissolves Metapex, and for this reason, sterile saline solution was used for irrigation purposes.<sup>[8]</sup>

Preparation of the root canal system is one of the most important stages in root canal therapy, and in this study, oval-shaped canals were selected, which represent a challenge to any preparation system.<sup>[15,21-23]</sup> Within the limitations of this study, none of the preparation systems was able to instrument all the root dentin walls in the oval-shaped canals, and this result matches the results of previous studies.<sup>[9,11,24]</sup>

It can be concluded that the WaveOne and ProTaper systems exhibited better performance than the SAF and HFs in canal debridement in the oval-shaped root canals, with significant differences between the groups. On this basis, the null hypothesis that there is no difference between the methods in the preparation of oval-shaped root canals must be rejected. Micro-computed tomography studies are recommended to assess further the effectiveness of these instruments in root canal debridement.

## REFERENCES

- Peters OA. Current challenges and concepts in the preparation of root canal systems: A review. *J Endod* 2004;30:559-67.
- Jou YT, Karabucak B, Levin J, Liu D. Endodontic working width: Current concepts and techniques. *Dent Clin North Am* 2004;48:323-35.
- Wu MK, Wessellink PR. A primary observation on the preparation and obturation of oval canals. *Int Endod J* 2001;34:137-41.
- De-Deus G, Reis C, Beznos D, de Abranches AM, Coutinho-Filho T, Paciornik S. Limited ability of three commonly used thermoplasticized gutta-percha techniques in filling oval-shaped canals. *J Endod* 2008;34:1401-5.
- Marchesan MA, Arruda MP, Silva-Sousa YT, Saquy PC, Pecora JD, Sousa-Neto MD. Morphometrical analysis of cleaning capacity using nickel-titanium rotary instrumentation associated with irrigating solutions in mesio-distal flattened root canals. *J Appl Oral Sci* 2003;11:55-9.
- Taha NA, Ozawa T, Messer HH. Comparison of three techniques for preparing oval-shaped root canals. *J Endod* 2010;36:532-5.
- Peters OA, Boessler C, Paqué F. Root canal preparation with a novel nickel-titanium instrument evaluated with micro-computed tomography: Canal surface preparation over time. *J Endod* 2010;36:1068-72.
- Ruckman JE, Whitten B, Sedgley CM, Svec T. Comparison of the self-adjusting file with rotary and hand instrumentation in long-oval-shaped root canals. *J Endod* 2013;39:92-5.
- Versiani MA, Leoni GB, Steier L, De-Deus G, Tassani S, Pécora JD, *et al.* Micro-computed tomography study of oval-shaped canals prepared with the self-adjusting file, Reciproc, WaveOne, and ProTaper universal systems. *J Endod* 2013;39:1060-6.
- Peters OA, Barbakow F. Effects of irrigation on debris and smear layer on canal walls prepared by two rotary techniques: A scanning electron microscopic study. *J Endod* 2000;26:6-10.
- Ahlquist M, Henningsson O, Hulthen K, Ohlin J. The effectiveness of manual and rotary techniques in the cleaning of root canals: A scanning electron microscopy study. *Int Endod J* 2001;34:533-7.
- Hilaly Eid GE, Wanees Amin SA. Changes in diameter, cross-sectional area, and extent of canal-wall touching on using 3 instrumentation techniques in long-oval canals. *Oral Surg Oral Med Oral Pathol Oral Radiol Endod* 2011;112:688-95.
- Metzger Z, Teperovich E, Zary R, Cohen R, Hof R. The self-adjusting file (SAF). Part 1: Respecting the root canal anatomy - A new concept of endodontic files and its implementation. *J Endod* 2010;36:679-90.
- Albrecht LJ, Baumgartner JC, Marshall JG. Evaluation of apical debris removal using various sizes and tapers of ProFile GT files. *J Endod* 2004;30:425-8.
- Versiani MA, Pécora JD, de Sousa-Neto MD. Flat-oval root canal preparation with self-adjusting file instrument: A micro-computed tomography study. *J Endod* 2011;37:1002-7.
- Metzger Z, Zary R, Cohen R, Teperovich E, Paqué F. The quality of root canal preparation and root canal obturation in canals treated with rotary versus self-adjusting files: A three-dimensional micro-computed tomographic study. *J Endod* 2010;36:1569-73.
- Johnson E, Lloyd A, Kuttler S, Namerow K. Comparison between a novel nickel-titanium alloy and 508 nitinol on the cyclic fatigue life of ProFile 25/.04 rotary instruments. *J Endod* 2008;34:1406-9.
- Berutti E, Chiandussi G, Paolino DS, Scotti N, Cantatore G, Castellucci A, *et al.* Canal shaping with WaveOne Primary reciprocating files and ProTaper system: A comparative study. *J Endod* 2012;38:505-9.
- Bergmans L, Van Cleynenbreugel J, Wevers M, Lambrechts P. A methodology for quantitative evaluation of root canal instrumentation using microcomputed tomography. *Int Endod J* 2001;34:390-8.
- Peters OA, Laib A, Rügsegger P, Barbakow F. Three-dimensional analysis of root canal geometry by high-resolution computed tomography. *J Dent Res* 2000;79:1405-9.
- Schilder H. Cleaning and shaping the root canal. *Dent Clin North Am* 1974;18:269-96.
- De-Deus G, Barino B, Zamolyi RQ, Souza E, Fonseca A Jr, Fidel S, *et al.* Suboptimal debridement quality produced by the single-file F2 ProTaper technique in oval-shaped canals. *J Endod* 2010;36:1897-900.
- Paqué F, Peters OA. Micro-computed tomography evaluation of the preparation of long oval root canals in mandibular molars with the self-adjusting file. *J Endod* 2011;37:517-21.
- Weiger R, ElAyouti A, Löst C. Efficiency of hand and rotary instruments in shaping oval root canals. *J Endod* 2002;28:580-3.

### Access this article online

#### Quick Response Code:



Website:  
www.eurjdent.com

Source of Support: Nil.  
Conflict of Interest: None declared