

# Primary failure of eruption combined with bilateral transmigration of mandibular canines, transposition, torus palatinus, and class III incisor relationship: A rare case report

Salma Babiker Idris Elhag<sup>1</sup>, Ashraf Sidig Idris Abdulghani<sup>2</sup>

**Correspondence:** Dr. Salma Babiker Idris Elhag  
Email: Salmababiker2013@gmail.com

<sup>1</sup>Department of Orthodontics, Faculty of Dentistry, University of Khartoum, Khartoum, Sudan,  
<sup>2</sup>Department of Oral and Maxillofacial Surgery, Faculty of Dentistry, University of Khartoum, Khartoum, Sudan

## ABSTRACT

Eruption disorders are numerous varying from delayed to complete failure of eruption. Primary failure of eruption (PFE) is a rare condition that involves arrested eruption of teeth with the absence of local or general contributory factors. Another rare and clinically challenging phenomenon is canine transmigration which is the intra-osseous movement of impacted canines across the midline. This report presents the first case of combined failure of eruption of multiple teeth with bilateral mandibular canine transmigration, transposition of upper canine and the first premolar, torus palatinus, and class III incisor relationship in a 33-year-old asymptomatic and nonsyndromic female patient.

**Key words:** Canine transmigration, impaction, primary failure of eruption

## INTRODUCTION

Eruption disorders are frequently encountered in dental practice; these include ectopic eruption, impaction, over-eruption, infra-occlusion, transmigration, and failure of eruption. There are two types of failure of eruption; (1) mechanical failure of eruption due to ankylosis or obstruction of the eruption pathway by hard or soft tissue, or (2) primary failure of eruption (PFE) which is failure of the eruptive mechanism of the tooth. Proffit and Vig<sup>[1]</sup> described primary or idiopathic failure of eruption as a condition in which failure of full or partial eruption of nonankylosed teeth is attributed to the disturbance in the eruption process with a lack of mechanical interferences or other recognizable disorders. As an outcome to the absence of teeth in the posterior part of the dental arch, a posterior open-bite results, which does not respond to orthodontic treatment, complicating the overall management.<sup>[1]</sup>

Transmigration of teeth is a rare disorder defined as the pre-eruptive intra-osseous migration of a tooth

across the midline of the jaw. Javid<sup>[2]</sup> suggested that a canine should be classified as transmigrated when more than half of the length of the tooth had passed the midline. These transmigrated canines can either erupt ectopically at the midline or on the opposite side of the arch, or they just can remain asymptotically impacted which is the more common outcome.<sup>[3]</sup>

The first case of canine transmigration reported in the literature was in 1951,<sup>[4]</sup> since then the number of reported transmigrated canines has increased and well exceeded the 127 cases reported by Mupparapu.<sup>[5]</sup> It was

This is an open access article distributed under the terms of the Creative Commons Attribution-NonCommercial-ShareAlike 3.0 License, which allows others to remix, tweak, and build upon the work non-commercially, as long as the author is credited and the new creations are licensed under the identical terms.

**For reprints contact:** reprints@medknow.com

**How to cite this article:** Elhag SB, Abdulghani AS. Primary failure of eruption combined with bilateral transmigration of mandibular canines, transposition, torus palatinus, and class III incisor relationship: A rare case report. *Eur J Dent* 2015;9:594-8.

**DOI:** 10.4103/1305-7456.172628

previously believed that the incidence of transmigration occurred distinctively in mandibular canines, this is now refuted as several cases of maxillary canine transmigration have been reported.<sup>[6,7]</sup>

In view of the fact that unilateral transmigration of mandibular canines is considered a rare phenomenon, the occurrence of bilateral transmigration of mandibular canines is regarded even rarer. Aktan *et al.*<sup>[8]</sup> observed that only 9% of transmigrated mandibular canines were bilateral while the rest were unilateral. To date, the number of cases reported in the literature with bilateral mandibular canine transmigration has reached only 17 cases.<sup>[9]</sup>

Both anomalies, PFE and bilateral canine transmigration are challenging to treat separately, and even more challenging when combined together in a single patient. We report the first case that combines PFE, bilateral mandibular canine transmigration, transposition, torus palatinus, and class III incisor relationship.

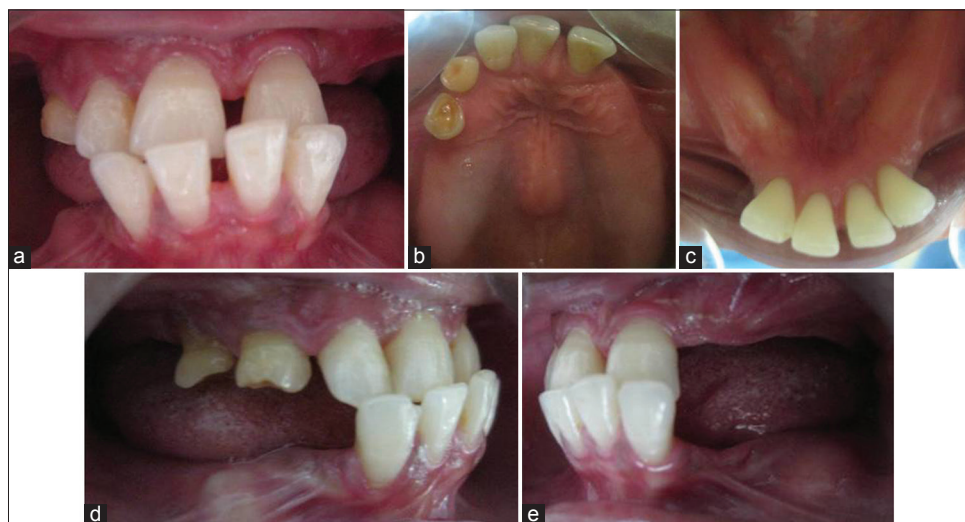## CASE REPORT

A 33-year-old female patient presented to the prosthodontic department requesting a denture to be made due to missing posterior teeth. Upon revealing that she had never extracted any of her posterior teeth, a panoramic radiograph was required on which the presence of all of her missing teeth was revealed, she was then referred to the orthodontic department for further evaluation. Her past medical history was

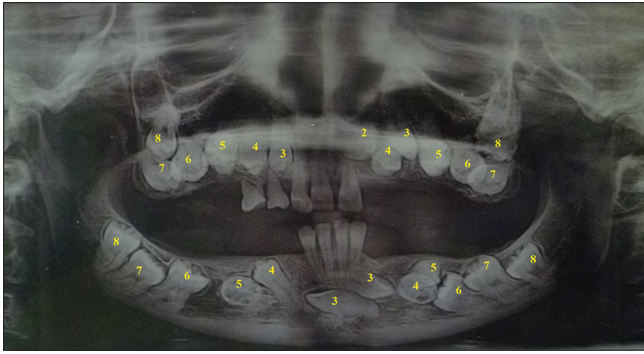
completely normal with no history of radiation or unusual drug therapy. Her family history was also normal with none of the family members having features of unerupted teeth.

Investigations were carried out to exclude any associated syndromes; thyroid function tests, parathormone levels, hormone assays, serum calcium, and phosphorous levels. The results of the investigations were within normal limits. Intra-oral examination [Figure 1] revealed 2 retained deciduous teeth 54 and 55. The only permanent teeth present were 11, 12, 21, and all 4 lower incisors. The anatomy of erupted teeth was normal. There was grade 1 mobility of the lower incisors in a buccolingual direction. A torus palatinus existed and bulging related to the unerupted teeth with no signs of pain and crackling. A class III incisor relationship with deep bite and bilateral posterior open-bite were present. Examination of mandibular movements revealed no displacements excluding the presence of pseudo class III malocclusion.

Panoramic radiograph [Figure 2] revealed two retained deciduous teeth, 13 unerupted permanent teeth in the maxilla and 12 unerupted permanent teeth in the mandible. A total of 25 unerupted teeth: 13, 14, 15, 16, 17, 18, 22, 23, 24, 25, 26, 27, 28, 33, 34, 35, 36, 37, 38, 43, 44, 45, 46, 47, 48. The upper left lateral incisor was located above the root apex of the upper left central incisor. The upper left canine and the first premolar were in transposition. However, the lower canines were horizontally impacted below the



**Figure 1:** (a) Intraoral frontal photograph showing class III incisor relationship with erupted upper permanent central incisors, upper right lateral incisor and lower incisors. (b) Intraoral occlusal photograph of maxillary dental arch showing erupted 11, 12, 21, retained upper right D and E and torus palatinus. (c) Intraoral occlusal photograph of mandibular dental arch showing erupted 31, 32, 41 and 42. (d) Intraoral photograph showing posterior open-bite on the right side and bulging in the lower ridge. (e) Intraoral photograph showing posterior open-bite on the left side and bulging in the lower ridge



**Figure 2:** Panoramic radiograph showing 25 unerupted permanent teeth, transposition of upper left canine and the first premolar with mandibular canines horizontally impacted beneath the root apices of the lower central incisors and transmigrated across the midline

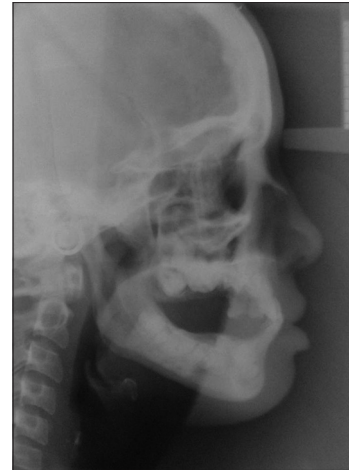apices of the lower incisors and have transmigrated across the midline, with the right canine lying above the left canine. Root development was complete for all unerupted permanent teeth except 44 and 38. The mesial root of 46 appeared to be dilacerated. The 34, 35, and 45 were labially inclined. Moreover, the lower molars on both sides were near to the inferior border of the mandible.

The presence of class III incisor relationship entailed investigation of the skeletal and dental factors that contributed to this malocclusion, therefore, a cephalometric radiograph was requested, which revealed normal skeletal features, increased proclination of lower incisors [Figure 3 and Table 1].

**DISCUSSION**

On reviewing the literature, this is the first case that combines both failure of eruption and bilateral canine transmigration. Most of the reported cases either report failure of eruption or transmigration.<sup>[1-5,9-15]</sup> Moreover, the patient also presented with torus palatinus and anterior crossbites, which were not previously reported in the literature, ultimately adding bizarre features to this case.

Recent studies have shown that PFE is largely an inherited anomaly and that mutations in PTH1R genes explain several familial cases of PFE.<sup>[16]</sup> A number of known human syndromes give a clear evidence of the genetic origin of the eruption defect which manifests as part of the clinical features of the syndrome. These syndromes include cleidocranial dysplasia, Osteoglophonic dysplasia, Osteopetrosis, Rutherford syndrome, and GAPO syndrome [growth retardation, alopecia, pseudoanodontia (failure of tooth eruption), and progressive optic Atrophy].<sup>[17]</sup>



**Figure 3:** Cephalometric radiograph revealing increased lower incisor proclination (L1-MP), protrusion of lower lip (LL-E), reduced labiomental angle and posterior open-bite

**Table 1: Pretreatment cephalometric analysis of skeletal, dental and soft tissue parameters**

Measurement	Normal range	Pretreatment reading
SNA	81°±3°	81°
SNB	79°±3°	80°
ANB	3°±2°	1°
U1-MxP	109°±6°	116°
L1-MnP	93°±6°	104°
U1-L1	133°±10°	113°
MMPA	27°±4°	26°
LFH %	55±2%	55.7%
LL-E	-2 mm	+3.5 mm
NLA	85°-105°	102°
LMA	130°	105°

SNA: Relationship of maxilla to cranial base, SNB: Relationship of mandible to cranial base, ANB: Relationship of maxilla to mandible, U1-MxP: Upper incisor to maxillary plane, L1-MnP: Lower incisor to mandibular plane, U1-L1: Interincisal angle, MMPA: Maxillary mandibular plane angle, LFH: Lower facial height, LL-E: Lower lip to esthetic plane, NLA: Nasiolabial angle, LMA: Labiomental angle

Nevertheless, Proffit and Vig<sup>[1]</sup> observed that their patients did not have similarly affected close relatives, and none had any apparent medical problems or associated syndrome.

Proffit and Vig<sup>[1]</sup> concluded that the characteristics of PFE involve (1) more commonly affected posterior teeth than anterior; (2) partial or complete failure of involved teeth; (3) both deciduous and permanent molars may be affected; (4) involvement may be unilateral or bilateral; (5) affected permanent teeth are likely to become ankylosed; (6) application of orthodontic force in an effort to extrude the teeth leads to their ankylosis (7) isolated cases and the absence of affected family members with this condition. Most of the features presented in this patient were in line with the characteristics suggested by Proffit and Vig.<sup>[1]</sup>

Disturbances of canine eruption are suggested to be under strong genetic control having shown to affect some family members. Some believe that ectopic canines show signs of a multifactorial inheritance pattern with high phenotypic variance and low penetrance.<sup>[18]</sup> Studies have shown the involvement of the Msx 1 gene in the developmental position of tooth buds, consequently, mutations in this gene can lead to disturbances in tooth positions. Moreover, an association between Pax 9 transcription factor and repositioning of tooth buds on the mesenchymal level has been established.<sup>[18]</sup>

Mupparapu *et al.*<sup>[19]</sup> proposed a classification for bilateral mandibular canine transmigration [Table 2]. In this patient the radiographic appearance of the transmigrated canines were in accordance with Type III subtype A, in which both mandibular canines had transmigrated across the midline, having a long-axis inclination of about 90°, and were positioned within the symphysis region, one above the other.

PFE presents an extremely challenging condition for orthodontic treatment planning. Teeth with PFE do not respond to orthodontic extrusive mechanics and become ankylosed when subjected to orthodontic force. In view of the fact that an ankylosed tooth is considered as a method for absolute orthodontic anchorage, an effort to pull down a tooth which ankyloses soon after force is applied often results in intrusion of the normal teeth. This worsens the situation by converting an isolated posterior open-bite into a more general lateral open-bite. Surgical procedures such as distraction osteogenesis or segmental osteotomy are useful treatment options

to move unerupted teeth into occlusion; however, their use in routine practice is limited due to the associated complications of high risks of damaging vital structures. Moreover, the position of the nonerupting teeth may preclude surgery to bring the teeth into occlusion. Hence, prosthetic rehabilitation is the only viable treatment option in these patients.<sup>[1]</sup>

Regarding the transmigrated mandibular canines, the proposed treatment options are surgical removal, auto-transplantation, surgical exposure with orthodontic alignment and observation. Surgical removal is the preferred treatment approach for migrated canines. As for transplantation, it can be considered if the mandibular incisors are in a normal position and there is sufficient space for the transmigrated canines. Surgical exposure and orthodontic alignment can be carried out if it is feasible to bring the teeth into normal position. However, it will be mechanically impossible to bring them into place if the crown of such a tooth migrates past the opposite incisor area or if the apex is seen to have migrated past the apex of the adjacent lateral incisor. At last, observation of symptomless transmigrated canines might be the best and simplest solution with periodical successive radiographs taken for these patients.<sup>[15]</sup>

## CONCLUSION

This report presents the first case of PFE combined with bilateral transmigration of mandibular canines, transposition of upper canine and the first premolar, torus palatinus, and class III incisor relationship. Both dental anomalies; PFE and bilateral canine transmigration are extremely rare and even more rare when occurring

**Table 2: Mupparapu's<sup>[19]</sup> proposed classification of bilateral mandibular canine transmigration**

Type	Description
Type I	Mandibular canines transmigrate across the midline, and the final position is around the midsymphyseal region with most of the crown and root portions on the opposite side of the midsagittal plane. The long-axis inclination of less than 45 degrees to the midsagittal plane
Subtype A	Only 1 canine completely crosses the midline and the other canine is just at the midline, or both partially cross the midline.
Subtype B	Both canines completely cross the midline.
Type II	Mandibular canines transmigrate across the midline, and the final position of the canines is anywhere between the midline and the canine region of the opposite side with a long-axis inclination of 45 to 90 degrees to the midsagittal plane
Subtype A	Only 1 canine completely crosses the midline and the other canine is just at the midline, or both canines partially cross the midline.
Subtype B	Both canines completely cross the midline.
Type III	Mandibular canines transmigrate across the midline having a long-axis inclination of about 90 degrees. Essentially, the teeth are horizontally positioned within the body of the mandible. The final position of both transmigratory canines may vary anywhere from the midsymphyseal region to the opposite canine region or beyond
Subtype A	Canines are positioned within the symphysis region, one above the other.
Subtype B	Canines are within the body of the mandible but occupy a distinct and separate position on opposite sides beyond the midsymphyseal region, far from their ideal position within the arch.

together, making treatment planning and management very challenging for the dental practitioner. There is little understanding of both conditions because they are not well presented in textbooks, due to little number of documented cases. Further documentation of these anomalies will lead to improvement and better understanding of these rare conditions.

### Financial support and sponsorship

Nil.

### Conflicts of interest

There are no conflicts of interest.

## REFERENCES

1. Proffit WR, Vig KW. Primary failure of eruption: A possible cause of posterior open-bite. *Am J Orthod* 1981;80:173-90.
2. Javid B. Transmigration of impacted mandibular cuspids. *Int J Oral Surg* 1985;14:547-9.
3. Kufteci MM, Shapira Y, Nahlieli O. A case report. Bilateral transmigration of impacted mandibular canines. *J Am Dent Assoc* 1995;126:1022-4.
4. Bluestone LI. The impacted mandibular bicuspid and canine: Indications for removal and surgical considerations. *Dent Items Interest* 1951;73:341-55.
5. Mupparapu M. Patterns of intra-osseous transmigration and ectopic eruption of mandibular canines: Review of literature and report of nine additional cases. *Dentomaxillofac Radiol* 2002;31:355-60.
6. Aydin U, Yilmaz HH. Transmigration of impacted canines. *Dentomaxillofac Radiol* 2003;32:198-200.
7. Aras MH, Büyükkurt MC, Yolcu U, Ertas U, Dayi E. Transmigrant maxillary canines. *Oral Surg Oral Med Oral Pathol Oral Radiol Endod* 2008;105:e48-52.
8. Aktan AM, Kara S, Akgunlu F, Isman E, Malkoc S. Unusual cases of the transmigrated mandibular canines: Report of 4 cases. *Eur J Dent* 2008;2:122-6.
9. Garg A, Agarwal S, Agarwal S, Mittal S, Singh P. Pattern of bilateral transmigration of impacted mandibular canines: A radiographic study of 3 cases. *J Evid Based Med Healthc* 2015;2:921-8.
10. Aruna U, Annamalai PR, Nayar S, Bhuminathan S. Primary failure of eruption- a case report with cone beam computerized tomographic imaging. *J Clin Diagn Res* 2014;8:ZD14-6.
11. Tanaka E, Kawazoe A, Nakamura S, Ito G, Hirose N, Tanne Y, *et al.* An adolescent patient with multiple impacted teeth. *Angle Orthod* 2008;78:1110-8.
12. Yildirim D, Yilmaz HH, Aydin U. Multiple impacted permanent and deciduous teeth. *Dentomaxillofac Radiol* 2004;33:133-5.
13. Bahl R, Singla J, Gupta M, Malhotra A. Abberantly placed impacted mandibular canine. *Contemp Clin Dent* 2013;4:217-9.
14. Auluck A, Nagpal A, Setty S, Pai KM, Sunny J. Transmigration of impacted mandibular canines – Report of 4 cases. *J Can Dent Assoc* 2006;72:249-52.
15. Camilleri S, Scerri E. Transmigration of mandibular canines – A review of the literature and a report of five cases. *Angle Orthod* 2003;73:753-62.
16. Frazier-Bowers SA, Simmons D, Wright JT, Proffit WR, Ackerman JL. Primary failure of eruption and PTH1R: The importance of a genetic diagnosis for orthodontic treatment planning. *Am J Orthod Dentofacial Orthop* 2010;137:160.e1-7.
17. Ahmad S, Bister D, Cobourne MT. The clinical features and aetiological basis of primary eruption failure. *Eur J Orthod* 2006;28:535-40.
18. Cakan DG, Ulkur F, Taner T. The genetic basis of dental anomalies and its relation to orthodontics. *Eur J Dent* 2013;7 Suppl 1:S143-7.
19. Mupparapu M, Auluck A, Suhaz S, Pai KM, Nagpal A. Patterns of intraosseous transmigration and ectopic eruption of bilaterally transmigrating mandibular canines: Radiographic study and proposed classification. *Quintessence Int* 2007;38:821-8.

#### Access this article online

##### Quick Response Code:



##### Website:

[www.eurjdent.com](http://www.eurjdent.com)