

Clear double layer Bioplast feeding plate for neonates with cleft palate

R. Burcu Nur Yilmaz¹, Meltem Mutlu¹, Derya Germec-Cakan¹

Correspondence: Dr. R. Burcu Nur Yilmaz
Email: drburcunur@gmail.com

¹Department of Orthodontics, Faculty of Dentistry,
Yeditepe University, Istanbul, Turkiye

ABSTRACT

An infant with cleft palate was referred to cleft clinic of the Orthodontic Department. The mother was concerned to feed the child because of the escape of milk from the nose. Intraoral examination revealed a large palatal cleft extending from hard to soft palate involving uvula. The impression was taken and dental cast obtained. A 3 mm soft and afterward a 1 mm hard Bioplast plate was pressed using Biostar device (Scheu-Dental GmbH, Iserlohn, Germany) on the model. Finally, a hole was prepared on the anterior part to put a thread through it. The infant tolerated the plate immediately and encounters no difficulties during feeding. The inlaying soft Bioplast plates eliminate the risk of tissue irritation, whereas the covering hard Bioplast plate supplies endurance. The fabrication of the clear Bioplast feeding plate is easy and less time-consuming compared with acrylic plates and may be recommended in crowded and overloaded cleft centers.

Key words: Bioplast feeding plate, cleft palate, infancy

INTRODUCTION

Cleft lip and palate (CLP) is the second most common major congenital anomaly in the Turkish population.^[1] The incidence is approximately 0.6% and more frequently recorded in Black Sea, South Eastern Anatolia, and Aegean region of Turkey.^[2]

CLP has a complex genetic and environmental etiology associated with dental anomalies.^[3,4] Infants with CLP have esthetic and functional problems. Infants with only cleft palate have not an atypical facial appearance but also functional problems, especially with feeding. In fact, the first highlighted topic of parents of infants with CLP after birth is how to feed their baby.^[5] Recent studies suggested that the abnormal facial appearance not affected the mother-child relationship.^[6,7] However, the longer feeding period and the disruption of feeding rhythm due to emission through the nose may lead to frustration of the mother.^[8]

In infants with cleft palate the anatomical obstruction between the oral and nasal cavity is not present, and feeding is a really hard job for the parents: Negative pressure required for sucking cannot be created, nasal regurgitation, and burping due to air intake during deglutition and choking make the feeding

more problematic.^[9,10] The parents are frequently in “psychosocial emergency,” in other words in a period of severe emotional crisis, and the anxiety of inability of adequate feeding the infant is not welcomed.^[11-13]

Several specialists are involved in the management of CLP patients and work as a team. The orthodontist is one of the first specialists contacting with the infant as soon as possible after birth. The infants with cleft palate get maxillary feeding plates (obturators) in orthodontic clinics. Traditionally, the plate is made of clear acrylic using conventional methods. The fabrication of such a plate is time-consuming and soft tissue injuries are frequently observed due to the rigidity of this material.^[14,15] Therefore, the objective of this case report is to present a quick and easy method

This is an open access article distributed under the terms of the Creative Commons Attribution-NonCommercial-ShareAlike 3.0 License, which allows others to remix, tweak, and build upon the work non-commercially, as long as the author is credited and the new creations are licensed under the identical terms.

For reprints contact: reprints@medknow.com

How to cite this article: Yilmaz RB, Mutlu M, Germec-Cakan D. Clear double layer Bioplast feeding plate for neonates with cleft palate. *Eur J Dent* 2015;9:610-3.

DOI: 10.4103/1305-7456.172629

to fabricate a feeding plate of double layer Bioplast material in a patient with an isolated soft and hard palate cleft.

CASE REPORT

A 7-day-old male infant with cleft palate was referred to the cleft clinic. The mother was concerned to feed the child because of the escape of milk from the nose. In addition, the milk intake was not satisfying the pediatrician. The intraoral evaluation revealed a large palatal cleft extending from hard to soft palate involving uvula [Figure 1]. The impression was taken in the operating room with C-silicone material (Zetaplus®, Zhermack, Bedia Polesine, Italy) under the supervision of the general anesthetist. Afterward, dental plaster cast models were obtained. A 3 mm Bioplast clear plate (soft plate) was pressed on the model using the Biostar device (Scheu-Dental GmbH, Iserlohn, Germany) [Figure 2a and b]. After trimming the edges of the soft plate, it was placed again on the cast and 1 mm Biocryl C Rose transparent plate (hard plate) was pressed. The edges of the plate were again trimmed so that the hard plate covering was 1 mm shorter than the soft plate. After final polishing, a hole was drilled on the anterior part [Figure 3a]. A thread was applied through the hole to one finger of the mother to prevent any emergencies [Figure 3b]. Approximately, 1 h after the impression taking procedure, the Bioplast clear feeding plate was delivered to the infant. After the last control of the borders of the plate, the feeding process was started. The infant adapted immediately without any problems. The mother was educated about cleaning, insertion, and removal of the appliance. Two days later, an additional appointment was arranged to evaluate any complaints with using the feeding plate. The intraoral evaluation revealed no soft tissue irritations. The infant was followed up periodically every month. The mother mentioned that the nutrition intake and weight gain was found adequate by the pediatrician.

DISCUSSION

Management of patients with cleft is a longstanding period starting at the birth and not ending until skeletal maturity.^[16] Specialists from different disciplines such as pediatrics, plastic and reconstructive surgery, maxillofacial surgery, orthodontics, genetics, ear-nose-throat, psychology, and speech therapy are involved in the treatment. The orthodontist is involved in the treatment team at an early period infancy.^[17]

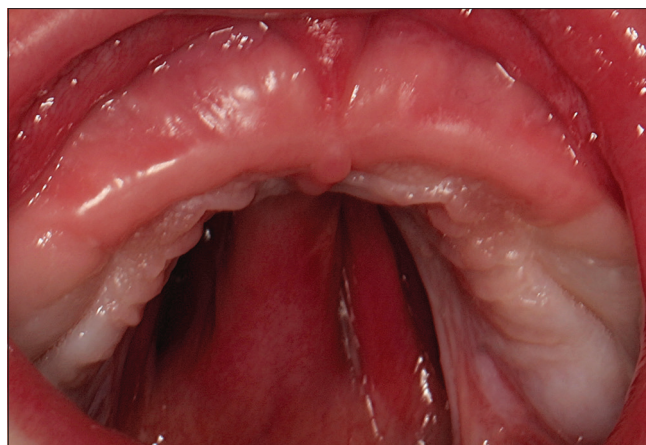


Figure 1: Intraoral photograph presenting a large palatal cleft, extending from hard to soft palate involving uvula

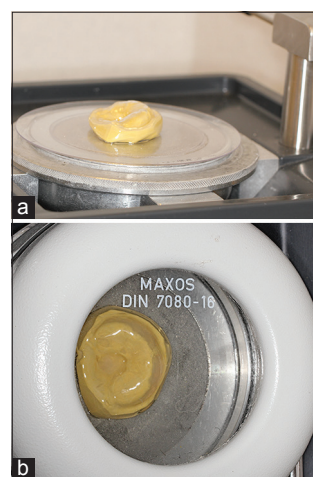


Figure 2: Fabrication of feeding plate using Biostar device (Scheu-Dental GmbH, Iserlohn, Germany), (a) during, and (b) after pressing process of Bioplast plate

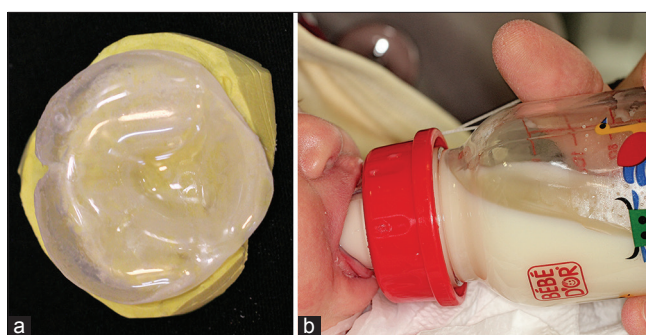


Figure 3: Feeding plate after (a) final polishing and a hole drilling on anterior part, (b) a thread was applied through the hole to attach to one finger of the mother to prevent any emergencies during feeding

The infants with CLP get presurgical orthopedic therapy in the first months, whereas infants with cleft palate are treated with feeding obturators/plates. Feeding plates are only preferred in cases that will benefit from it. For example, in cases with small dimensional, notch-like, and on soft palate located

clefts, information of the upright feeding position may be more helpful for the parents instead of serving a plate.^[18] Feeding plates are only used in cases with large clefts involving the hard palate. The advantages of such plates were described as facilitation of feeding, normalization of tongue position, the guidance of maxillary growth, and prevention of collapse of alveolar segments and also improvement of the psychology of parents.^[9]

Our cleft clinic, as a part of the orthodontic department, is a crowded and workload clinic dealing with approximately 100 infants pro year. The majority of the patient population has complete CLP. These patients get nasoalveolar molding therapy to enhance esthetic and function. After the fabrication of the intraoral plate, the patient was followed up with weekly appointments by two specialists until the lip surgery at approximately 3–4 months of age. The intraoral plate has to be used 24 h/day except the cleaning period. The estimated follow-up visits in an infant with a unilateral cleft is approximately 13–14 times.^[18] In these appointments, modifications rather than new appliance fabrication were performed.^[16,19] On the other hand, in cases with isolated palatal clefts, feeding plates are preferred to enhance the feeding activity. The feeding plate is used only during the feeding activity. After the fabrication of the first plate, the patients are followed at monthly intervals until the palatal surgery at approximately 1-year of age. In approximately every third appointment, the plates were renewed because of the growth of the infant. In summary, in cases with cleft palate approximately 3–4 appliances are fabricated.

Over years, acrylic materials were used for fabrications of these plates in our clinics.^[14] However, acrylic resin has disadvantages such as: (1) Time consuming, (2) complicated fabrication, and (3) prone to soft tissue irritation, and therefore not well-tolerated by the infant. In crowded and workload cleft centers the time to fabricate such plates is of essential importance. Therefore, the aim of the presented case report was to present a quick, easy method to fabricate a feeding plate, which also not irritates the soft tissue resulting in a well adaptation by the infant.

Bioplast material was preferred in the fabrication of feeding plates by Erkan *et al.*^[11] They used such a plate to obstruct the soft palate cleft in a patient with unilateral CLP. They suggested that if the bulb of the appliances set in the cleft is fabricated from 1 mm

Bioplast clear soft plates, the adaptation is excellent, and the movements are synchronized with functions. However, in the present case the aim by Bioplast soft plate was to prevent soft tissue irritation and not to obstruct the cleft. Intraoral soft tissue complications are not rare during the presurgical orthopedic treatment period. Uneven flanges or unrelieved areas of the inner surface of the plate may cause to ulcerations.^[15] In the present case report, 3 mm soft Bioplast plate was used as an inner layer to prevent any soft tissue irritations. In addition, the hard Bioplast plate was removed 1 mm above the borders of the feeding plate, to obtain the only contact between the soft Bioplast plate and soft tissue. The hard Bioplast plate enhance the endurance of the plate, indeed no breakage was encountered.

The present case report showed a new approach to fabricate feeding plates using Bioplast material in infants with cleft palate. Traditionally presurgical orthopedic treatment appliances fabricated of acrylic are preferred in patients with CLP. The aim of these appliances is first to align the alveolar segments by adding of and removing of soft and hard acrylic and secondly to perform nasal molding. The most advantage of Bioplast feeding plate is that it speeds the fabrication time. Probably the plate for nasoalveolar molding can be fabricated from Bioplast material. However, the nasal stent coverage and also the modifications may need soft acrylic usage. Consequently, if Bioplast material is also advantageous in infants with CLP is questionable and need forthcoming research. Overall, this is a case report and studies about the performance, time consumption, and comfort are also required to take this method into routine management.

CONCLUSION

The fabrication of a feeding plate of double layer clear Bioplast material for infants with cleft palate is advantageous. The inlaying soft Bioplast plates eliminate the risk of tissue irritation, whereas the covering hard Bioplast plate supplies endurance. Therefore, the Bioplast feeding plate was handy for the mother and also well-tolerated by the infant. Overall, the fabrication of the clear Bioplast feeding plate is easy and less time-consuming compared with acrylic plates and may be recommended in crowded and overloaded cleft centers.

Financial support and sponsorship

Nil.

Conflicts of interest

There are no conflicts of interest.

REFERENCES

- Tomatir AG, Demirhan H, Sorkun HC, Köksal A, Ozerdem F, Cilengir N. Major congenital anomalies: A five-year retrospective regional study in Turkey. *Genet Mol Res* 2009;8:19-27.
- Nur RB, İlhan D, Fişekçioğlu E, Oktay İ, Arun T. Prevalence of orthodontic malocclusion and evaluation criteria in 7 geographic regions of Turkey. *Turk J Orthod* 2014;26:154-61.
- Cakan DG, Ulkur F, Taner T. The genetic basis of dental anomalies and its relation to orthodontics. *Eur J Dent* 2013;7 Suppl 1:S143-7.
- Subasioglu A, Savas S, Kucukyilmaz E, Kesim S, Yagci A, Dundar M. Genetic background of supernumerary teeth. *Eur J Dent* 2015;9:153-8.
- Chuacharoen R, Ritthagol W, Hunsrisakhun J, Nilmanat K. Felt needs of parents who have a 0- to 3-month-old child with a cleft lip and palate. *Cleft Palate Craniofac J* 2009;46:252-7.
- Speltz ML, Arnsden GC, Clarren SS. Effects of craniofacial birth defects on maternal functioning postinfancy. *J Pediatr Psychol* 1990;15:177-96.
- Maris CL, Endriga MC, Speltz ML, Jones K, DeKlyen M. Are infants with orofacial clefts at risk for insecure mother-child attachments? *Cleft Palate Craniofac J* 2000;37:257-65.
- Pruzinsky T. Social and psychological effects of major craniofacial deformity. *Cleft Palate Craniofac J* 1992;29:578-84.
- Grabber TM, Vanarsdall RL, Vig KW. *Orthodontics: Current Principles and Techniques*. 4th ed. St. Louis, MO: Elsevier Mosby; 2005. p. 1097-121.
- Osuji OO. Preparation of feeding obturators for infants with cleft lip and palate. *J Clin Pediatr Dent* 1995;19:211-4.
- Erkan M, Karaçay S, Atay A, Günay Y. A modified feeding plate for a newborn with cleft palate. *Cleft Palate Craniofac J* 2013;50:109-12.
- Dar H, Winter ST, Tal Y. Families of children with cleft lips and palates: Concerns and counseling. *Dev Med Child Neurol* 1974;16:513-7.
- Nur RB, Germeç-Çakan D, Türkyılmaz Uyar E, Arun T. Evaluation of causes and levels of anxiety in mothers of infants with cleft lip and palate. *Clin Dent Res* 2014;38:20-30.
- Kuttenberger J, Ohmer JN, Polska E. Initial counseling for cleft lip and palate: Parents' evaluation, needs and expectations. *Int J Oral Maxillofac Surg* 2010;39:214-20.
- Germeç Çakan D, Nur B, Sayınsu K, Arun T. Guidance to orthodontic clinics of infants with cleft lip and palate (Dudak Damak Yarıklı Bebeklerin Ortodonti Kliniklerine Yönlendirilmesi). 7 Tepe Klinik 2009;2:21-7.
- Santiago PE, Barry H. Grayson role of the craniofacial orthodontist on the craniofacial and cleft lip and palate team. *Semin Orthod* 2009;15:225-43.
- Canady JW, Means ME, Wayne I, Thompson SA, Richman LC. Continuity of care: University of Iowa Cleft Lip/Palate Interdisciplinary Team. *Cleft Palate Craniofac J* 1997;34:443-6.
- Turner L, Jacobsen C, Humenczuk M, Singhal VK, Moore D, Bell H. The effects of lactation education and a prosthetic obturator appliance on feeding efficiency in infants with cleft lip and palate. *Cleft Palate Craniofac J* 2001;38:519-24.
- Grayson BH, Cutting CB. Presurgical nasoalveolar orthopedic molding in primary correction of the nose, lip, and alveolus of infants born with unilateral and bilateral clefts. *Cleft Palate Craniofac J* 2001;38:193-8.

Access this article online

Quick Response Code:



Website:
www.eurjdent.com