

# An unusually large aggressive adenomatoid odontogenic tumor of maxilla involving the third molar: A clinical case report

Vikas Dhupar<sup>1</sup>, Francis Akkara<sup>1</sup>, Pulkit Khandelwal<sup>2</sup>

**Correspondence:** Dr. Pulkit Khandelwal  
Email: khandelwal.pulkit22@gmail.com

<sup>1</sup>Department of Oral and Maxillofacial Surgery,  
Goa Dental College and Hospital, Bambolim, Goa, India,  
<sup>2</sup>Department of Oral and Maxillofacial Surgery, Pacific  
Dental College and Hospital, Udaipur, Rajasthan, India

## ABSTRACT

Adenomatoid odontogenic tumor (AOT) is a rare tumor comprising only 3% of all odontogenic tumors. It is a benign, encapsulated, noninvasive, nonaggressive, slowly growing odontogenic lesion associated with an impacted tooth. These lesions may go unnoticed for years. The usual treatment is enucleation and curettage, and the lesion does not recur. Here, we present a rare case of an unusually large aggressive AOT of maxilla associated with impacted third molar. The authors also discuss clinical, radiographic, histopathologic, and therapeutic features of the case. Subtotal maxillectomy with simultaneous reconstruction of the surgical defect with temporalis myofascial flap was planned and carried out.

**Key words:** Benign, impacted tooth, odontogenic, tumor

## INTRODUCTION

Adenomatoid odontogenic tumor (AOT) is a benign, slow-growing, and noninvasive odontogenic lesion associated with an impacted tooth. It represents only 3% of all odontogenic tumors.<sup>[1]</sup> The presence of so-called unique “duct-like structures” under microscope imparts the tumor a glandular, i.e., adenomatoid appearance. The tumor is also known as “Two Third’s Tumor” because about 2/3<sup>rd</sup> cases occur in maxilla, about 2/3<sup>rd</sup> cases are diagnosed in young females during the second decade, 2/3<sup>rd</sup> cases are associated with an impacted tooth and in 2/3<sup>rd</sup> cases, impacted tooth is canine.<sup>[2]</sup>

We present a case of unusually large aggressive AOT in the maxilla associated with impacted third molar.

## CASE REPORT

A 19-year-old male reported with a chief complaint of painless mass over the left side of face and upper left back tooth region since 6 months. There was no history of any facial trauma. Medical history was nonsignificant. Initially, pea-sized and asymptomatic swelling appeared in upper left back tooth region. Three months later, swelling also appeared below left eye, initially pea-sized. There was marked increase in the size of swelling to its present size. He gave h/o exfoliation of multiple teeth from the same region within these 6 months.

On examination, solitary, smooth, roughly spherical-shaped swelling was present on the left side

This is an open access article distributed under the terms of the Creative Commons Attribution-NonCommercial-ShareAlike 3.0 License, which allows others to remix, tweak, and build upon the work non-commercially, as long as the author is credited and the new creations are licensed under the identical terms.

**For reprints contact:** reprints@medknow.com

**How to cite this article:** Dhupar V, Akkara F, Khandelwal P. An unusually large aggressive adenomatoid odontogenic tumor of maxilla involving the third molar: A clinical case report. Eur J Dent 2016;10:277-80.

**DOI:** 10.4103/1305-7456.178308

### Access this article online

Quick Response Code:



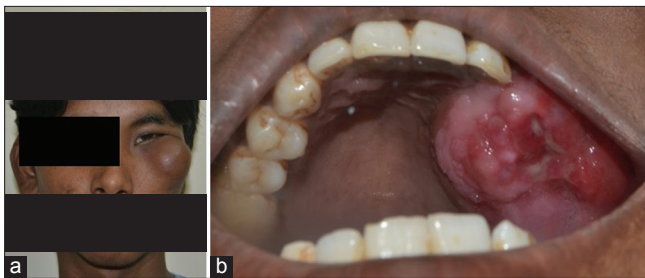
**Website:**  
www.eurjdent.com

of face below eye. Swelling extends from infraorbital region until malar prominence and from medial to lateral corner of left eye measuring approximately 5.0 cm × 5.0 cm in maximum dimensions. Overlying skin was normal. No sign of neurological deficit was present. There was marked obliteration of palpebral fissure of the left eye [Figure 1a]. Intraorally, there was a solitary roughly oval-shaped growth in the left maxillary region, obliterating the buccal vestibule. Growth was extending from canine region till retromolar area along alveolar ridge measuring approximately 7 cm × 4 cm. Overlying mucosa was erythematous, edematous, and inflamed. Both extraorally and intraorally, swelling was firm, noncompressible, nonfluctuant, nontender, nonreducible, and nonpulsatile. Cortical expansion of the maxillary alveolus was palpable. The teeth from canine till the third molar were missing. Incisors were mobile [Figure 1b]. A provisional diagnosis of ameloblastoma was considered.

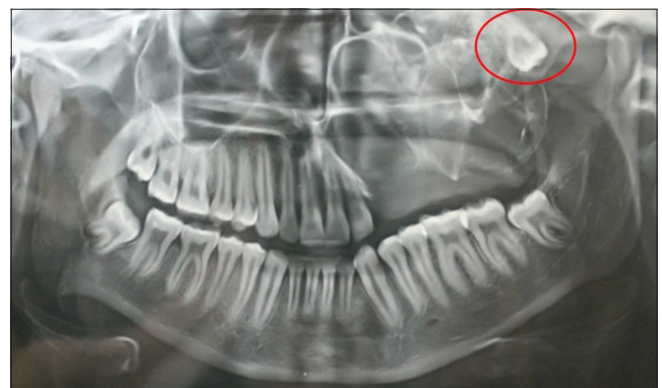Orthopantomogram revealed a huge, diffuse radiolucent lesion extending throughout left maxilla from canine till retromolar region. The lesion was

associated with an impacted permanent upper left third molar, which was found to be present below floor of the orbit. There was no resorption of root of incisors [Figure 2]. Computed tomography scan [Figure 3a-c] demonstrated a large cystic expansile radiolucent lesion with flecks of calcification of varying sizes. The buccal and palatal bony expansion was remarkable, and resorption of bone with perforation was evident. Maxillary sinus was completely opaque. On the basis of these radiological findings, AOT and Pindborg tumor were also considered as differential diagnosis. Incisional biopsy was then performed. Based on histopathological findings, a final diagnosis of AOT was made. The treatment plan was formulated and explained to the patient. Informed consent was taken.

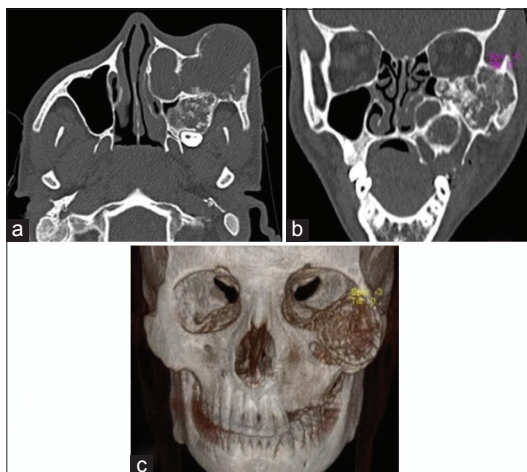
Using modified Weber-Ferguson incision, the tumor mass was exposed [Figure 4a]. Having accessed the tumor extraorally as well as intraorally, subtotal maxillectomy was performed, and the involved teeth were also removed [Figure 4b]. Excised specimen was sent for histopathological examination [Figure 4c].



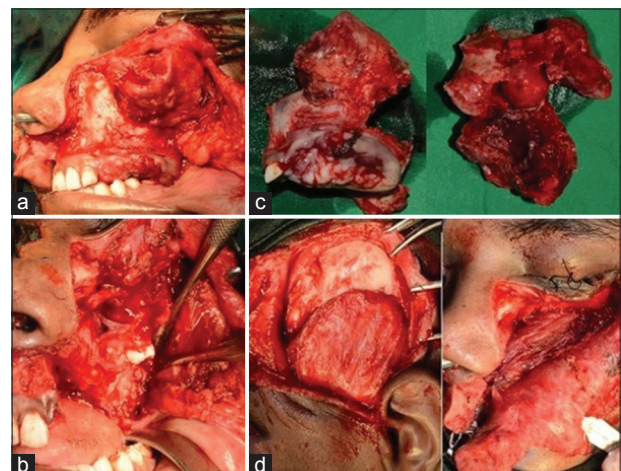
**Figure 1:** (a) Preoperative extraoral photograph shows swelling over the face. (b) Intraoral photograph showing lesion involving palate, alveolar ridge, and buccal vestibule



**Figure 2:** Orthopantomogram showing a large radiolucent lesion involving left maxilla, and impacted upper left third molar teeth displaced below floor of orbit by the lesion (red circle)



**Figure 3:** (a-c) Computed tomography scan revealing the expansile radiolucent lesion with few radio-opaque flakes. There is remarkable bony expansion and thinning and discontinuity of the palatal and buccal cortices. Maxillary sinus is completely opaque



**Figure 4:** (a-d) Operative photographs



The surgical defect was simultaneously reconstructed using temporalis myofascial flap [Figure 4d]. Healing was uneventful. Six months after surgery, computed tomogram was done which revealed complete eradication of the lesion [Figure 5a-c]. There was no evidence of any recurrence 1 year after the surgery [Figure 6a and b].

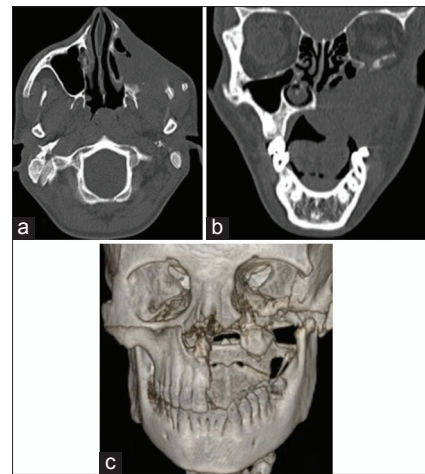
Histological examination revealed a partially cyst-like cavity lined with the fibrous capsule. Rounded and rosette-like aggregates of odontogenic epithelial cells with sparse areas of eosinophilic material could be visualized. The histopathological findings were consistent with that of AOT [Figure 7].

## DISCUSSION

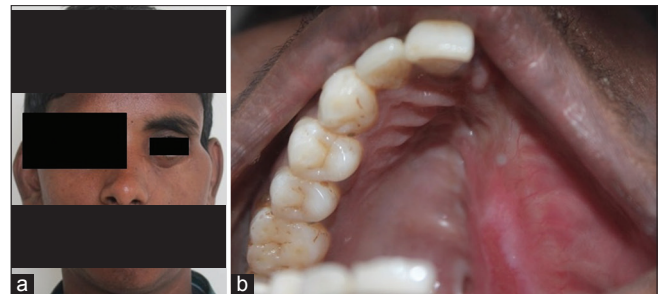
AOT has three clinicopathological variants, namely intraosseous follicular (73%), intraosseous extrafollicular (24%), and peripheral (3%). The intraosseous follicular type is associated with an impacted tooth as in our case, whereas the intraosseous extrafollicular type has no association with an impacted tooth and the peripheral variant is soft tissue component, attached to the gingival structures. The lesion often leads to the expansion of the involved bone and the displacement of the adjacent teeth. Owing to the slow growing and painless nature of the tumor, the patients tolerate the swelling for a long duration, sometimes years until it produces an obvious esthetic deformity.<sup>[3]</sup> It may rarely show aggressive nature such as gaining unusually large size or extending into the intracranial space.<sup>[4]</sup>

Radiographically, the lesion often demonstrates as a unilocular radiolucency associated with an impacted tooth. In certain cases, small radiopaque spots (calcifications) may be seen.<sup>[5]</sup> Differential diagnosis of AOT includes dentigerous cyst, calcifying odontogenic cyst (COC), calcifying odontogenic tumor (COT) (Pindborg tumor), and odontogenic keratocyst. Fine calcifications seen radiographically differentiate an AOT from dentigerous cyst and odontogenic keratocyst. Displacement of teeth often occurs without root resorption.<sup>[2,6]</sup> Radiolucency with multiple radiopaque foci (particularly when the radiolucency surrounds a portion of the root or entire tooth) is suggestive of an AOT rather than a COC/COT.<sup>[7,8]</sup>

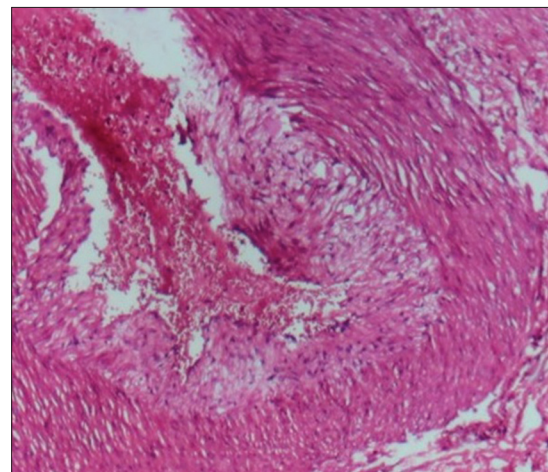
Histologically, AOT is mostly surrounded by a well-developed fibrous connective tissue capsule. The tumor is usually composed of spindle-shaped or



**Figure 5:** (a-c) Six months postoperative computed tomogram shows normal healing and no signs of recurrence



**Figure 6:** (a) One year follow-up photograph. (b) One year follow-up intraoral photograph with normal healing



**Figure 7:** The characteristic rounded and rosette form lined with a single layer of polarised cuboidal or columnar epithelial cells giving it the adenomatoid appearance (H and E, 400)

polygonal cells forming sheets, rosettes or whorled masses in a sparse connective tissue stroma. The amorphous eosinophilic material is present between the epithelial cells as well as in the center of these rosette-like structures. The nuclei of epithelial cells are polarized away from the central lumen.<sup>[2]</sup>

AOT usually measures within 1–3 cm in diameter.<sup>[9]</sup> Very rare cases of large AOTs are described in literature. The large size of this lesion has been attributed to a higher growth rate in younger patients and a delay in seeking treatment.<sup>[10]</sup> The treatment usually consists of enucleation and curettage.<sup>[11]</sup> However, in our case, the lesion was extremely large in size and expansile. Therefore, subtotal maxillectomy with simultaneous reconstruction of surgical defect with temporalis myofascial flap was planned and carried out.

## CONCLUSION

Here, a rare case of AOT of the maxilla is reported. The case presented is rare in occurrence because of certain atypical features such as unusual large size, aggressive behavior, the involvement of maxillary third molar, third molar present below floor of orbit, significant bony expansion, and cortical perforation. Under general anesthesia, the lesion was excised. There was no recurrence in 1 year follow-up.

## Declaration of patient consent

The authors certify that they have obtained all appropriate patient consent forms. In the form the patient(s) has/have given his/her/their consent for his/her/their images and other clinical information to be reported in the journal. The patients understand that their names and initials will not be published and due efforts will be made to conceal their identity, but anonymity cannot be guaranteed.

## Financial support and sponsorship

Nil.

## Conflicts of interest

There are no conflicts of interest.

## REFERENCES

1. Arotiba GT, Arotiba JT, Olaitan AA, Ajayi OF. The adenomatoid odontogenic tumor: An analysis of 57 cases in a black African population. *J Oral Maxillofac Surg* 1997;55:146-8.
2. Vasudevan K, Kumar S, Vijayasamundeeswari, Vigneswari S. Adenomatoid odontogenic tumor, an uncommon tumor. *Contemp Clin Dent* 2012;3:245-7.
3. Olgaç V, Köseoglu BG, Kasapoglu C. Adenomatoid odontogenic tumor: A report of an unusual maxillary lesion. *Quintessence Int* 2003;34:686-8.
4. Narayanan VS, Naidu G, Ragavendra R, Mhaske-Jedhe S, Haldar M. Adenomatoid odontogenic tumor of the mandible with unusual radiographic features: A case report. *Imaging Sci Dent* 2013;43:111-5.
5. Nonaka CF, Souza LB, Quinderé LB. Adenomatoid odontogenic tumour associated with dentigerous cyst – Unusual case report. *Rev Bras Otorrinolaringol* 2007;73:135-7.
6. Mehkri S, Rajkumar GC, Nagesh KS, Manjunath GS. Bilateral adenomatoid odontogenic tumour of the maxilla in a 2-year-old female – The report of a rare case and review of the literature. *Dentomaxillofac Radiol* 2012;41:342-8.
7. Chindasombatjaroen J, Poomsawat S, Kakimoto N, Shimamoto H. Calcifying cystic odontogenic tumor and adenomatoid odontogenic tumor: Radiographic evaluation. *Oral Surg Oral Med Oral Pathol Oral Radiol* 2012;114:796-803.
8. Agarwal A, Giri KY, Alam S. The interrelationship of adenomatoid odontogenic tumour and dentigerous cyst: A report of a rare case and review of the literature. *Case Rep Pathol* 2012;2012:358609.
9. Philipsen HP, Srisuwan T, Reichart PA. Adenomatoid odontogenic tumor mimicking a periapical (radicular) cyst: A case report. *Oral Surg Oral Med Oral Pathol Oral Radiol Endod* 2002;94:246-8.
10. Mohamed A, Singh AS, Raubenheimer EJ, Bouckaert MM. Adenomatoid odontogenic tumour: Review of the literature and an analysis of 33 cases from South Africa. *Int J Oral Maxillofac Surg* 2010;39:843-6.
11. Shetty K, Vastardis S, Giannini P. Management of an unusually large adenomatoid odontogenic tumor. *Oral Oncol* 2005;41:316-8.