

Prevalence of C-shaped mandibular molars in the Portuguese population evaluated by cone-beam computed tomography

Jorge N. R. Martins¹, António Mata^{2,3,4}, Duarte Marques^{4,5}, João Caramês⁶

¹Department of Endodontics, Implantology Institute, Lisbon, Portugal,

²Department of Biology, New York University, New York, USA,

³Department of Oral Biology, School of Dental Medicine, Lisbon University, Lisbon, Portugal,

⁴Oral Biology and Biochemistry Group, Biomedical and Oral Sciences Research Unit (FCT Unit 4062)- Evidence Based Dentistry Center, Lisbon University, Lisbon, Portugal,

⁵Department of Anatomy and Physiology, School of Dental Medicine, Lisbon University, Lisbon, Portugal,

⁶Department of Implantology, School of Dental Medicine, Lisbon University, Lisbon, Portugal

Correspondence: Dr. Jorge N. R. Martins

Email: jnr_martins@yahoo.com.br

ABSTRACT

Objective: The purpose of this study was to evaluate the prevalence of first and second C-shaped mandibular molars in a Western European population of Portuguese Caucasians. **Materials and Methods:** Patients having both routine panoramic radiograph and presurgical cone-beam computed tomography (CBCT) exams were selected. The CBCT examination was performed at five different axial levels and the mandibular molars were classified as C-shape according to the Fan criteria. Differences between genders, age groups, left and right side, type of tooth, and root concavity side were determined. The molars were classified as nonfused roots (NFRI-II), FRI-III, or single root with single canal (SS) groups, using the panoramic radiograph. The prevalence of C-shaped anatomy was calculated to each group. **Results:** A total of 1783 teeth (695 first molars and 1088 second molars) from 792 patients were included in the study. The prevalence of C-shaped configurations was 0.6% and 8.5% to mandibular first and second molars, respectively. The differences between gender, teeth, and root concavity direction were considered statistically significant ($P < 0.05$). The FR had a significantly higher rate of C-shapes when compared to NFR ($P < 0.05$). Intrarater reliability was 93.6%. **Conclusions:** The FR radiographic appearance may be considered a predictor of this anatomy. Second mandibular molars and females had a higher incidence ratio. Apparently, the mandibular C-shaped anatomy is more common in the population of this study than that has been previously reported for the European population.

Key words: Cone-beam computed tomography, C-shaped root canal, dental morphology, mandibular molars, panoramic radiography

This is an open access article distributed under the terms of the Creative Commons Attribution-NonCommercial-ShareAlike 3.0 License, which allows others to remix, tweak, and build upon the work non-commercially, as long as the author is credited and the new creations are licensed under the identical terms.

For reprints contact: reprints@medknow.com

How to cite this article: Martins JN, Mata A, Marques D, Caramês J. Prevalence of C-shaped mandibular molars in the Portuguese population evaluated by cone-beam computed tomography. Eur J Dent 2016;10:529-35.

DOI: 10.4103/1305-7456.195175

Access this article online

Quick Response Code:



Website:
www.eurjdent.com

INTRODUCTION

The C-shaped root canal configuration was first introduced by Cooke and Cox.^[1] This anatomic variation has been associated with a possible failure of Hertwig's epithelial root sheath development. Namely, during the embryonic stage of the tooth formation, an anatomy with fused root (FR) canals, complex fins, and interconnecting webs is created.

Even though the C-shaped root canal configuration is a clinical condition, more associated to mandibular second molars,^[2] it has also been associated with other groups of teeth.^[2] This anatomic characteristic is highly important as is more difficult to manage, namely, to clean, shape, and obturate.

The prevalence of C-shaped mandibular second molar root canal configuration has been studied worldwide.^[2,3] It is well accepted that there is a higher prevalence of this morphology in Asia when compared with other studied regions.^[2] However, accordingly to Kato *et al.*'s systematic review,^[2] no study is available in the Western European region. Some authors state that there is an ethnic influence on the prevalence of these configurations.^[3,4] Moreover, in the Caucasian population, there is a lower incidence ratio of C-shaped mandibular molars.^[3] Clinical studies analyzing specific ethnic groups are scarce and many of them have several different ethnicities included.^[5,6] The studies regarding the C-shaped mandibular first molars are rare and until now there is no study available in Europe.^[5]

The main purpose of this cross-sectional study was to investigate the prevalence of C-shaped mandibular first and second molars anatomy among a specific Western European population, using cone-beam computed tomography (CBCT). The secondary purpose was to search in the panoramic radiographs any feature related to the CBCT that could be a predictor of a C-shaped anatomy.

MATERIALS AND METHODS

Sample population

The Ethical Committee of Implantology Institute in Lisbon, Portugal, approved the research protocol of the present study. CBCT scans and panoramic radiographs, taken from patients receiving treatments, were analyzed and evaluated retrospectively from May 2014 to November 2014. The radiographs were

taken for diagnosis purposes and treatment planning. The CBCT scans were performed only before implant surgery procedures in patients that required that specific treatment. Both exams were performed in a Planmeca scanner (Planmeca Promax, Planmeca, Finland) as per instructions of the manufacturer and analyzed using computer visualization software (Planmeca Romexis, Planmeca, Finland). The panoramic radiographs were taken at 68 kV and 13 mA with a 16 s exposure time. The CBCT exam images were obtained at a 0.2 mm voxel size, 80 kV and 15 mA for 12 s and were reconstructed to be 0.6 mm thick slice.

Patients who had both panoramic radiographs and CBCT scans performed between May 2011 and May 2014 were selected for this study. Moreover, only mature first and second mandibular molars detected in both exams were included in the analyzed sample.

Exclusion criteria

Teeth with previous root canal treatment or superimposed artifact images that prevented a correct radiographic evaluation were excluded from the study.

The same evaluator, with a 3 months interval, performed the evaluation of both CBCT and panoramic radiographs. The evaluator was blinded regarding the CBCT and panoramic radiographic correspondence.

Cone-beam computer tomography analysis

The CBCT evaluation was performed by observing the axial cross-section images at five levels of the root canal system: 2 mm under the canal orifice ("coronal"), 2 mm above the anatomic apex ("apical"), middle distance from canal orifice and anatomic apex ("middle"), middle distance between "coronal" and "middle" (1/3), and middle distance between "middle" and "apical" (2/3) [Figure 1]. The teeth were classified as mandibular C-shaped molars accordingly to the classification proposed by Fan *et al.*^[7] Only the teeth that had simultaneously the following three characteristics were classified as C-shaped molars: FR, the presence of a longitudinal groove on lingual or buccal surface of the root and at least one axial cross-section of the canal belonging to the C1, C2, or C3 configuration. The axial cross-section classification used was also the one proposed by Fan *et al.*,^[7] which is a modification of Melton *et al.*'s method.^[8] This classification has five categories: An interrupted C-shaped canal (C1), a discontinuous C-shaped canal with a semicolon shape with the angles α and β having

no $<60^\circ$ (C2), two or three separated canals with both angles α and β having $<60^\circ$ (C3), single round or oval canal (C4), and no canal lumen (C5) [Figures 2 and 3]. The Planmeca Romexis "Measure Angle" tool was used to analyze the cases that required the angle measurement.

Panoramic radiographic analysis

The teeth evaluated by radiograph were classified into six groups: Non-FR (NFR) with two divergent or parallel roots (NFR1), NFR with two convergent roots (NFR2), conical FR with mesial and distal root canals merging at the apical level (FRI), conical FR with both mesial and distal canals following their own independent track to the apex (FR2), conical FR with a distal root canal curving toward a radiolucent line when running to the apex and a longer mesial canal following his own path to the apex (FR3), and a single root with a single canal (SS) [Figure 4]. The first five categories were presented by Sinanoglu and Helvacioğlu-Yigit,^[9] which is a modification of Fan radiographic classification,^[10] the sixth group was added by our team in this investigation.

Statistical analysis

All teeth were classified, according to their anatomy, by both CBCT and radiographic analysis. The collected data were introduced in SPSS software (IBM SPSS Statistics for Windows, Version 22.0. Armonk, NY, USA) and analyzed. The primary outcome was the prevalence of C-shape configuration. Predictive variables were gender, left and right side, type of tooth, age group, and root concavity side. The proportion (prevalence) of C-shapes in each radiographic configuration and differences between radiographic groups was calculated and expressed with a 95% confidence interval (CI). The Z-test for proportions was used to analyze the differences in independent groups. To all compared groups, $P < 0.05$ was considered statistically significant. The first 107 teeth included in the study were analyzed twice by the same observer with 1 month time interval and were used to calibrate the observer and to calculate the intraobserver reliability with the Cohen kappa test.

RESULTS

Study sample

A total of 1783 mandibular molars (695 mandibular first molars and 1088 mandibular second molars) from 792 patients (303 males and 489 females) with a mean age of 51 years were included in this study. It was

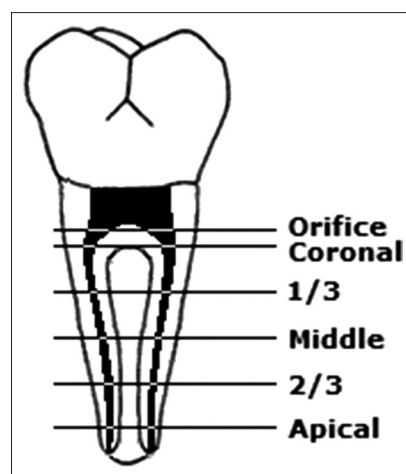


Figure 1: Axial cross-sections levels analyzed using cone-beam computed tomography

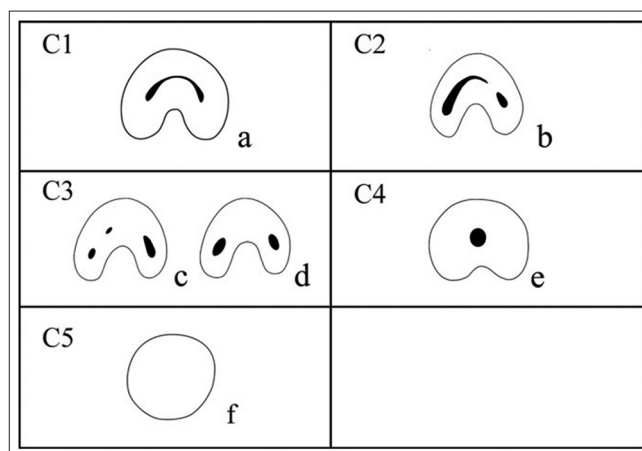


Figure 2: Axial cross-section classification of mandibular molars C-shapes^[7]

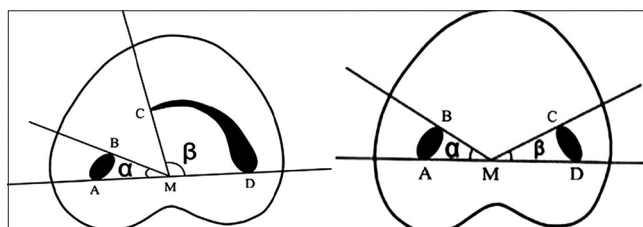


Figure 3: Angles measurements to differentiate cross-section C2 from C3^[7]

possible to find 97 C-shaped molars in the analyzed sample. Only the cases found in the second lower molars were taken into consideration in the difference between group analyzes.

The intrarater reliability, calculated with a kappa Cohen coefficient for the first 107 teeth screened in the study and was very high with a value of 93.6% and an asymptotic standard error of $\pm 6.3\%$.

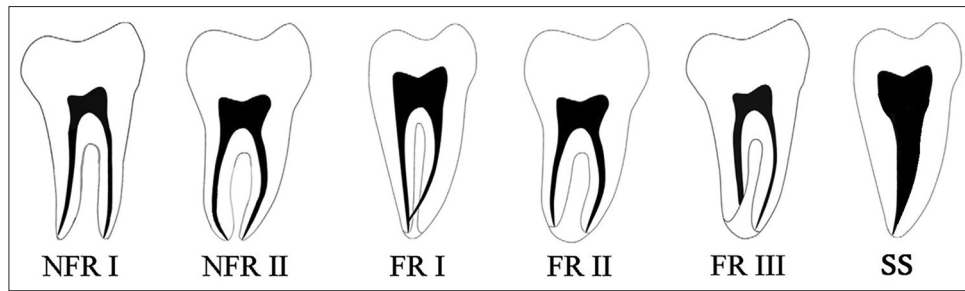


Figure 4: Radiographic root configurations^[9]

Prevalence of C-shapes according to gender

Sixteen C-shaped second molars were from males ($n = 398$) corresponding to a prevalence of 4.0% (2.09–5.93% CI 95%) and 77 were from females ($n = 690$) corresponding to a prevalence of 11.2% (8.85–13.55% CI 95%). The difference between genders was considered statistically significant at $P < 0.05$.

Prevalence of C-shapes according to left and right side

From the total of 93 mandibular C-shaped second molars, 42 were from tooth #37 (left side) ($n = 550$) representing a prevalence of 7.6% (5.39–9.81% CI 95%) and 51 were from tooth #47 (right side) ($n = 538$) with a prevalence of 9.5% (7.02–11.98% CI 95%). The difference between groups was considered statistically nonsignificant at $P < 0.05$.

Prevalence of C-shapes according to tooth

Regarding the type of tooth, 4 cases were identified in the first mandibular molars ($n = 695$) [Figure 5] with a prevalence of 0.6% (0.03–1.17% CI 95), and 93 cases were found in the second mandibular molars ($n = 1088$) representing a prevalence of 8.5% (6.84–10.16% CI 95%). The difference between teeth was considered statistically significant at $P < 0.05$.

Prevalence of C-shapes according to age group

The higher prevalence of C-shaped anatomy was found among the 45–54 years group with 11.1% (7.23–14.97% CI 95%) while the lowest rate was found in the 65–74 years group with a prevalence of 5.3% (1.19–9.41% CI 95). No case was found in the 85–94 years group ($n = 4$). The full prevalence list of each age group is shown in Table 1. Excluding the differences with 85–94 years group, which had an extremely low sample size, the only significant difference was between 45–54 and 65–74 years groups ($P < 0.05$).

Prevalence of C-shapes according to root concavity direction

The root concavity was turned toward lingual in 73 cases, representing a prevalence of 6.7% (5.21–8.19% CI

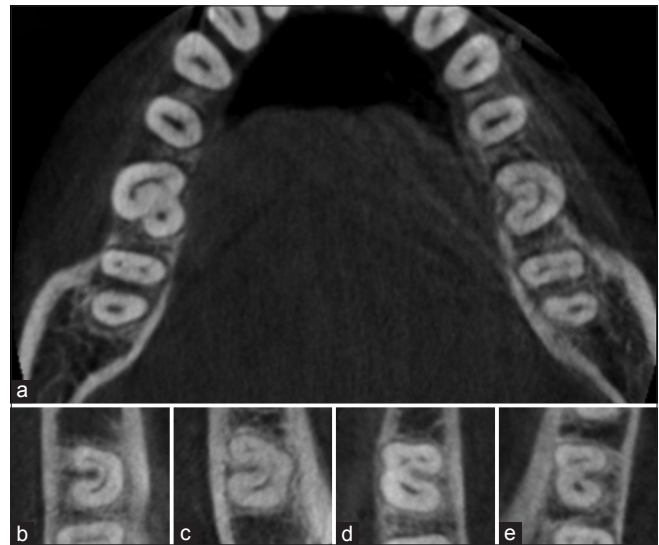


Figure 5: Some examples of the C-shapes found. (a) Two C-shaped mandibular first molars found. Both present a C1 type at the 1/3 axial cross-section level. Tooth #30 also presents an extra distolingual root, which may be understood as a radix entomolaris. (b) C1 type molar. (c) C2 type molar. (d) C3a type molar. (e) C3b type molar

95%) of C-shaped second molars with a lingual groove, and only 20 cases with a groove turned to buccal, which means a prevalence of 1.8% (1.01–2.59% CI 95). The difference between groove sides was considered statistically significant at $P < 0.05$. If we take into consideration only the C-shaped molars as sample, the groove is turned toward lingual in 78% of the cases.

Types of C-shape configurations on each axial level

When analyzing only the mandibular second molar, the most common type of C-shaped configuration to all axial levels is C3. In the present study, this type represents 38.1% on all analyzed axial levels, followed by C2 with 23.4% and only than C1 with 21.1%. The percentage of each C-shaped type on each axial cross-section level is shown in Table 2.

Prevalence of C-shapes according to radiographic configuration

NFR configurations identified in the panoramic radiograph presented a low ratio of C-shaped second

Table 1: Prevalence of C-shaped mandibular second molars according to age group

	Mandibular second molar C-shape		Total
	No	Yes	
Age group (years)			
15-24			
Count	49	5	54
% within age group	90.7	9.3	100.0
25-34			
Count	140	14	154
% within age group	90.9	9.1	100.0
35-44			
Count	221	18	239
% within age group	92.5	7.5	100.0
45-54			
Count	225	28	253
% within age group	88.9	11.1	100.0
55-64			
Count	217	19	236
% within age group	91.9	8.1	100.0
65-74			
Count	108	6	114
% within age group	94.7	5.3	100.0
75-84			
Count	31	3	34
% within age group	91.2	8.8	100.0
85-94			
Count	4	0	4
% within age group	100.0	0.0	100.0
Total			
Count	995	93	1088
% within age group	91.5	8.5	100.0

molars (data crossed with CBCT results) while all FR presented a higher one. FRI had a prevalence of 50.9% (37.44–64.36% CI 95%), FRII had 42.5% (33.39–51.61% CI 95%), and FRIII had 36.4% (7.97–64.83%). The full prevalence list to each radiographic group is shown in Table 3. Both NFRI and NFRII had a significant difference to all the other radiographic groups ($P < 0.05$). None of the FR groups (FRI, FRII, and FRIII) had difference between them ($P > 0.05$).

DISCUSSION

The methodologies used to study the mandibular C-shaped morphologies and prevalence rates have changed over the years. Nakayama and Toda,^[11] in the early 1940s, performed tooth sections to analyze these clinical conditions. From there, other methodologies such as clearing,^[12] radiographic,^[13] Spiral CT,^[14] CBCT,^[15] and micro-CT (μ CT)^[7] analysis have been used. Although all methodologies have their own benefits and defects, the only available technique that allows a good resolution of three-dimension images of *in vivo* studies is the CBCT technology. The μ CT and clearing techniques allow a high-detail study on the morphologic characteristics of these teeth; however, since both are *ex vivo* techniques, they may not be the ideal to perform a prevalence study, a type of research where CBCT may be more recommended. The nominal voxel resolution of the CBCT devices varies from 0.400 mm to 0.076 mm, and according to Scarfe *et al.*,^[16] the minimum voxel size used in

Table 2: Types of C-shaped configuration to each axial cross-section level on the mandibular second molar

C-shape	Coronal	Axial 1/3	Cross Middle	Sections 2/3	Apical	Total
Configuration						
C1						
Count	33	22	17	17	9	98
% within cross-section	35.5	23.6	18.3	18.3	9.7	21.1
C2						
Count	26	33	25	20	5	109
% within cross-section	27.9	35.5	26.8	21.5	5.4	23.4
C3						
Count	33	37	47	39	21	177
% within cross-section	35.5	38.1	50.5	41.9	22.6	38.1
C4						
Count	1	1	4	17	57	80
% within cross-section	1.1	1.1	4.3	18.3	61.3	17.2
C5						
Count	0	0	0	0	1	1
% within cross-section	0	0	0	0	1.1	0.2
Total						
Count	93	93	93	93	93	465
% within cross-section	100	100	100	100	100	100

Table 3: Prevalence of C-shaped mandibular second molars according to radiographic configuration

	Mandibular second molar C-shape		Total
	No	Yes	
Radiographic configuration			
NFR I			
Count	579	1	580
% within radiographic configuration	99.8	0.2	100.0
NFR II			
Count	301	13	314
% within radiographic configuration	95.9	4.1	100.0
FRI			
Count	26	27	53
% within radiographic configuration	49.1	50.9	100.0
FR II			
Count	65	48	113
% within radiographic configuration	57.5	42.5	100.0
FR III			
Count	7	4	11
% within radiographic configuration	63.6	36.4	100.0
Single canal			
Count	17	0	17
% within radiographic configuration	100.0	0.0	100.0
Total			
Count	995	93	1088
% within radiographic configuration	91.5	8.5	100.0

NFR: Nonfused root, FR: Fused root

endodontics should not exceed the 0.200 mm size. The voxel size used to study the C-shaped molars ranged from 0.125 mm^[15,17] to 0.250 mm.^[9,18] The 0.200 mm voxel size has already been successfully used to study C-shaped molars in previous investigations^[19] and is the size selected in the present study. In this research, the classification as a C-shaped anatomy was made according to the Fan criteria, a rigorous classification based on the axial shape analysis that has been recently used in several studies,^[9,15,18] allowing a perfect comparison between the researched populations. Due to the lack of homogeneity between studies, mainly regarding the criteria on defining a “C-shape” and the methodologies employed (radiographs, tooth sections, clearing, CBCT, Spiral CT, and μ CT), this comparison between populations is a very difficult task.

However, and independently from the heterogeneity of the studies, the prevalence of C-shaped mandibular second molars varies according to the region of the globe and is apparently higher in Asia. The incidence rate in the Chinese and Korean populations may reach 38.6%^[15] and 44.6%^[4] although lower rates for both populations have also been presented.^[20-22]

In the Middle East, prevalence of 7.2% and 10.6% for Iranian^[23] and Saudi Arabian populations^[24] has been reported. In North Africa, the Sudanese population may have an incidence rate of 10.0%.^[25] No study, before this investigation, was available in European region using three-dimensional images. The only European prevalence study found in a recent systematic review^[2] comes from Greece,^[13] in the Southeastern Europe, which presents an incidence rate of 4.8% using solely radiographic analysis. However, it has been stated that root canal anatomy^[26] and, in particular, C-shaped configurations are not easy to be seen using this radiographic approach,^[2] and the criteria used to define C-shape was very different from the one selected to this study, or to the other available studies in different geographic locations.

Our study suggests the existence of significant differences in the prevalence of C-shapes between genders. These findings are corroborated by other studies even though they do not report statistically significant differences.^[15,18] No differences have been found between molars in the left and right side of the mandible. These results are also in agreement with a similar work in a Chinese population.^[15] Regarding the age groups, no differences were found except when comparing 45–54 and 65–74 age groups. These results are also corroborated by similar studies in Chinese^[15] and Turkish^[18] populations. The deepest root groove is turned toward lingual in 78% of the cases in the Portuguese population, a finding that is in line with a previous study from Korea.^[4]

The most common type of C-shaped configuration in all studied levels was the C3, a finding that is in agreement with a research in the Turkish population.^[18]

Regarding the presence of this anatomy in the mandibular first molar, the available information is restricted to two studies, one from South America^[19] and another from Asia.^[27] Both investigations present the C-shaped morphology in the mandibular first molar as an uncommon occurrence, an idea that is corroborated with our findings in the European region.

The preoperative radiographic analysis has been well documented as an important step to diagnosis and treatment planning. It has been stated that FR on mandibular molars, observed radiographically, may be a strong sign of the presence of a C-shaped anatomy.^[9,10,13]

Our study seems to confirm this suggestion since all fused groups (FRI, FRII, and FRIII) have a significantly higher prevalence of these morphologies than the NFRI, NFRII. Indeed, the higher limit of the 95% CI was higher than 50% to any of the fused groups regarding the prevalence of C-shapes, which may indicate a considerable relation between radiographic FR and the presence of C-shaped anatomy.

One of the main problems of performing large sample size prevalence studies comparing CBCTs and panoramic radiographs has to expose a large number of patients to radiation and the risks associated. We were able to avoid that by accessing an already patterned existing radiographic database, not having to unnecessary expose any patient.

CONCLUSIONS

Although it has been stated that the prevalence of mandibular C-shaped anatomy in European populations is rare, the results of the present study do not corroborate with previous published data. In a Portuguese population, the overall prevalence of C-shaped configurations on mandibular second molars is 8.5%. There are significant differences ($P < 0.05$) between teeth and root concavity direction. Females are expected to present a higher ratio of C-shaped mandibular second molars. There is also a higher incidence rate of this anatomy in FR types, which may be seen as a radiographic feature that may predict a C-shaped anatomy.

Financial support and sponsorship

Nil.

Conflicts of interest

There are no conflicts of interest.

REFERENCES

- Cooke HG 3rd, Cox FL. C-shaped canal configurations in mandibular molars. *J Am Dent Assoc* 1979;99:836-9.
- Kato A, Ziegler A, Higuchi N, Nakata K, Nakamura H, Ohno N. Aetiology, incidence and morphology of the C-shaped root canal system and its impact on clinical endodontics. *Int Endod J* 2014;47:1012-33.
- Jafarzadeh H, Wu YN. The C-shaped root canal configuration: A review. *J Endod* 2007;33:517-23.
- Jin GC, Lee SJ, Roh BD. Anatomical study of C-shaped canals in mandibular second molars by analysis of computed tomography. *J Endod* 2006;32:10-3.
- Weine FS. The C-shaped mandibular second molar: Incidence and other considerations. *Members of the Arizona Endodontic Association. J Endod* 1998;24:372-375.
- Manning SA. Root canal anatomy of mandibular second molars. Part II. C-shaped canals. *Int Endod J* 1990;23:40-5.
- Fan B, Cheung GS, Fan M, Gutmann JL, Bian Z. C-shaped canal system in mandibular second molars: Part I – Anatomical features. *J Endod* 2004;30:899-903.
- Melton DC, Krell KV, Fuller MW. Anatomical and histological features of C-shaped canals in mandibular second molars. *J Endod* 1991;17:384-8.
- Sinanoglu A, Helvacioğlu-Yigit D. Analysis of C-shaped canals by panoramic radiography and cone-beam computed tomography: Root-type specificity by longitudinal distribution. *J Endod* 2014;40:917-21.
- Fan B, Cheung GS, Fan M, Gutmann JL, Fan W. C-shaped canal system in mandibular second molars: Part II – Radiographic features. *J Endod* 2004;30:904-8.
- Nakayama A, Toda Y. Clinical observation of gutter shaped root canal. *Kokubyo Gakkai Zasshi* 1941;15:118-23.
- Gulabivala K, Opasanon A, Ng YL, Alavi A. Root and canal morphology of Thai mandibular molars. *Int Endod J* 2002;35:56-62.
- Lambrianidis T, Lyroudia K, Pandelidou O, Nicolaou A. Evaluation of periapical radiographs in the recognition of C-shaped mandibular second molars. *Int Endod J* 2001;34:458-62.
- Cimilli H, Cimilli T, Mumcu G, Kartal N, Wesselink P. Spiral computed tomographic demonstration of C-shaped canals in mandibular second molars. *Dentomaxillofac Radiol* 2005;34:164-7.
- Zheng Q, Zhang L, Zhou X, Wang Q, Wang Y, Tang L, *et al.* C-shaped root canal system in mandibular second molars in a Chinese population evaluated by cone-beam computed tomography. *Int Endod J* 2011;44:857-62.
- Scarfe WC, Levin MD, Gane D, Farman AG. Use of cone beam computed tomography in endodontics. *Int J Dent* 2009;2009:634567.
- Zhang R, Wang H, Tian YY, Yu X, Hu T, Dummer PM. Use of cone-beam computed tomography to evaluate root and canal morphology of mandibular molars in Chinese individuals. *Int Endod J* 2011;44:990-9.
- Helvacioğlu-Yigit D, Sinanoglu A. Use of cone-beam computed tomography to evaluate C-shaped root canal systems in mandibular second molars in a Turkish subpopulation: A retrospective study. *Int Endod J* 2013;46:1032-8.
- Silva EJ, Nejaim Y, Silva AV, Haiter-Neto F, Cohenca N. Evaluation of root canal configuration of mandibular molars in a Brazilian population by using cone-beam computed tomography: An *in vivo* study. *J Endod* 2013;39:849-52.
- Yang ZP, Yang SF, Lin YC, Shay JC, Chi CY. C-shaped root canals in mandibular second molars in a Chinese population. *Endod Dent Traumatol* 1988;4:160-3.
- Seo MS, Park DS. C-shaped root canals of mandibular second molars in a Korean population: Clinical observation and *in vitro* analysis. *Int Endod J* 2004;37:139-44.
- Park JB, Kim N, Park S, Kim Y, Ko Y. Evaluation of root anatomy of permanent mandibular premolars and molars in a Korean population with cone-beam computed tomography. *Eur J Dent* 2013;7:94-101.
- Rahimi S, Shahi S, Lotfi M, Zand V, Abdolrahimi M, Es'haghi R. Root canal configuration and the prevalence of C-shaped canals in mandibular second molars in an Iranian population. *J Oral Sci* 2008;50:9-13.
- Al-Fouzan KS. C-shaped root canals in mandibular second molars in a Saudi Arabian population. *Int Endod J* 2002;35:499-504.
- Ahmed HA, Abu-bakr NH, Yahia NA, Ibrahim YE. Root and canal morphology of permanent mandibular molars in a Sudanese population. *Int Endod J* 2007;40:766-71.
- Nur BG, Ok E, Altunsoy M, Aglarci OS, Colak M, Gungor E. Evaluation of the root and canal morphology of mandibular permanent molars in a south-eastern Turkish population using cone-beam computed tomography. *Eur J Dent* 2014;8:154-9.
- Nie YK, Baker WZ, Alam MK. The occurrence of C-shaped root canal in Malaysian population. *Bangladesh J Med Sci* 2013;12:286-90.