

Case report

Technetium-99m-methylene Diphosphonate Uptake in Hepatic Necrosis Secondary to Respiratory Failure

Madhuri Shimpi Mahajan, Negi S. Digamber, Rajkumar Sharma

Department of Nuclear Medicine, Saral Diagnostics, Pitam Pura, New Delhi, India

Abstract

Tc-99m methylene diphosphonate (MDP) bone scintigraphy has long been used for the evaluation of benign as well as malignant skeletal conditions. However, non-osseous tracer uptake on a bone scan is an unusual finding. On one hand, there is a need for awareness of the pathophysiologic basis underlying such uptake, as it may be of critical clinical relevance in the evaluation of the patient. On the other hand, some alterations in biodistribution may be of little clinical significance, but have deleterious consequences on the quality of the bone study. Recognition of these abnormalities will reduce errors and provide important clinical information. We described a case of 57-year-old male patient with history of carcinoma base of tongue, where a 99mTc-MDP bone Scintigraphy was performed for metastasis survey. It revealed avascular necrosis of head of right femur. In addition incidentally demonstrated diffuse increased pathologic uptake of Tc-99m-MDP in the liver and multiple foci in bilateral lungs. This article reviews several possible reasons for such diffuse hepatic uptake. In the present case diffuse hepatic necrosis secondary to respiratory failure due to bilateral miliary pulmonary metastasis is considered to be the cause of the diffuse liver uptake of 99mTc-MDP.

Keywords: Diffuse liver uptake, extraosseous uptake, Tc-99m methylene diphosphonate bone scan

Introduction

Bone scan commonly used to detect bone metastasis, sometimes provides additional useful information other than bone lesions. The extraosseous uptake is often an unexpected finding on the bone scan. Recognition of specific mechanisms and familiarity with the appearance of soft-tissue abnormalities on skeletal scintigrams reduces the possibility of confusion and enhances the diagnostic value of the study. Unfortunately, the exact mechanism in many instances is yet to be completely understood. The authors present a case of carcinoma base of tongue, where a 99mTc-methylene diphosphonate (MDP) bone Scintigraphy performed for distant metastasis survey, which revealed avascular necrosis of head of right femur. Incidentally demonstrated intense diffuse hepatic and

multiple foci of uptake in bilateral lungs. This article reviews several possible reasons for such diffuse hepatic uptake.

Case Report

The present case is about a 57-year-old male k/c/o carcinoma of base of tongue presented with difficulty in walking since 15 days. History of local radiotherapy received 5-6 months back. On examination, he was bedridden, cachexic and breathless. Hemoglobin, mean cell volume, calcium, phosphorus, parathyroid hormone and alkaline phosphatase levels were normal. There was no history of iron dextran injection or chemotherapy in past.

99mTc-MDP bone Scintigraphy performed for skeletal metastasis survey. Tc-99m MDP (740 MBq) was administered intravenously and whole body imaging was performed after an interval of 4 h. Images demonstrated absent tracer uptake in the head of right femur [Figures 1 and 2b], suggestive of necrosis. In addition, images demonstrated intense diffuse hepatic uptake and multiple foci in bilateral lungs (suggestive of metastasis) [Figures 1

Access this article online

Quick Response Code:



Website:
www.wjnm.org

DOI:
10.4103/1450-1147.136736

Address for correspondence:

Dr. Madhuri Shimpi Mahajan, Department of Nuclear Medicine, Saral Advanced Diagnostics, E-1073, Saraswati Vihar, Pitam Pura, New Delhi - 110 034, India. E-mail: docmadhurim@gmail.com

and 2a]. Plain computed tomography (CT) chest [Figure 3] and abdomen [Figures 4 and 5] had done for correlation, which revealed bilateral, multiple pulmonary nodules however liver did not show any metastatic/abnormal foci. Our radiopharmaceutical quality control records showed that the aluminum concentration was well below 10 ppm and no radiocolloid formation was noted. Labeling efficiency was 99%.

Liver and renal function tests carried out on next day were deranged. The patient died in 2 days after bone scan.

Discussion

Radionuclide bone scanning is a sensitive technique for detecting changes in bone metabolism. It is commonly employed in the detection of skeletal metastases in various malignancies. Extrasosseous uptake of ^{99m}Tc-MDP is occasionally seen on bone scans.^[1] Common sites include the kidneys and the urinary bladder (normal tracer excretion), the breasts, the uterus (physiologic activity), thyroid, stomach (unlabeled tracer), primary and metastatic tumors, benign tumors, inflammatory conditions of soft-tissues, scars, injection sites, infarction, burns, wounds and so on.^[1]

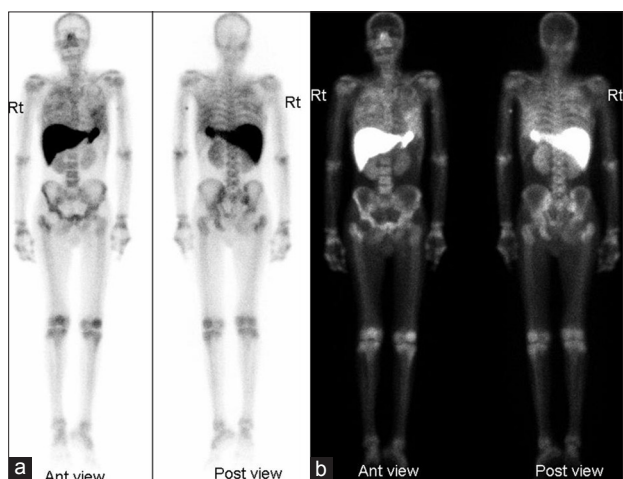


Figure 1: 99m-Tc methylene diphosphonate whole body scan images in (a) inverse and (b) linear color profile: Showing absent tracer uptake in the head of right femur. Diffuse tracer uptake in the liver and foci of heterogeneous tracer uptake in both lungs

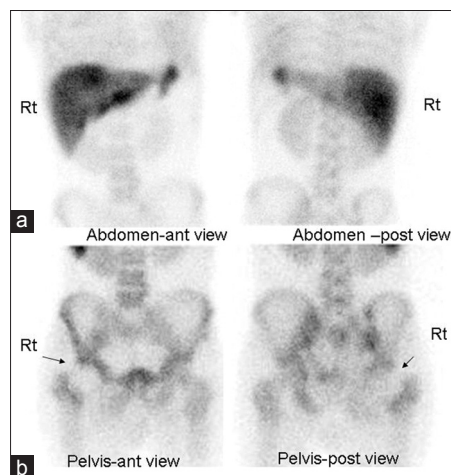


Figure 2: 99m-Tc methylene diphosphonate bone scan static images (a) abdomen: Diffuse tracer uptake seen in the liver and (b) pelvis: Absent tracer uptake in the head of right femur (arrow)

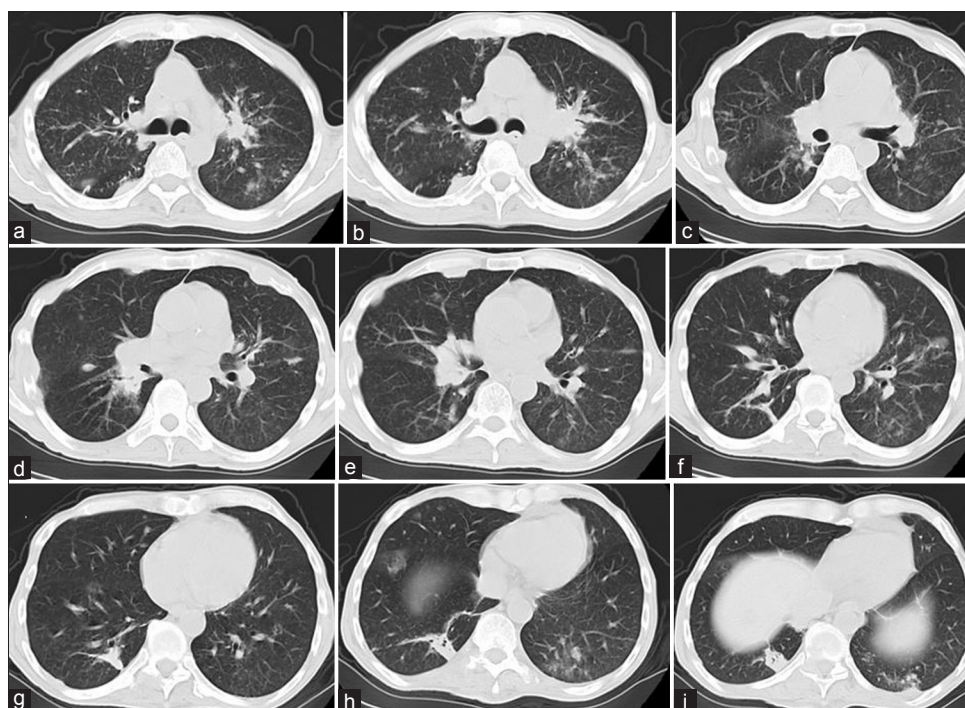


Figure 3: Transverse reconstruction of chest computed tomography scan: Showing bilateral multiple pulmonary nodules

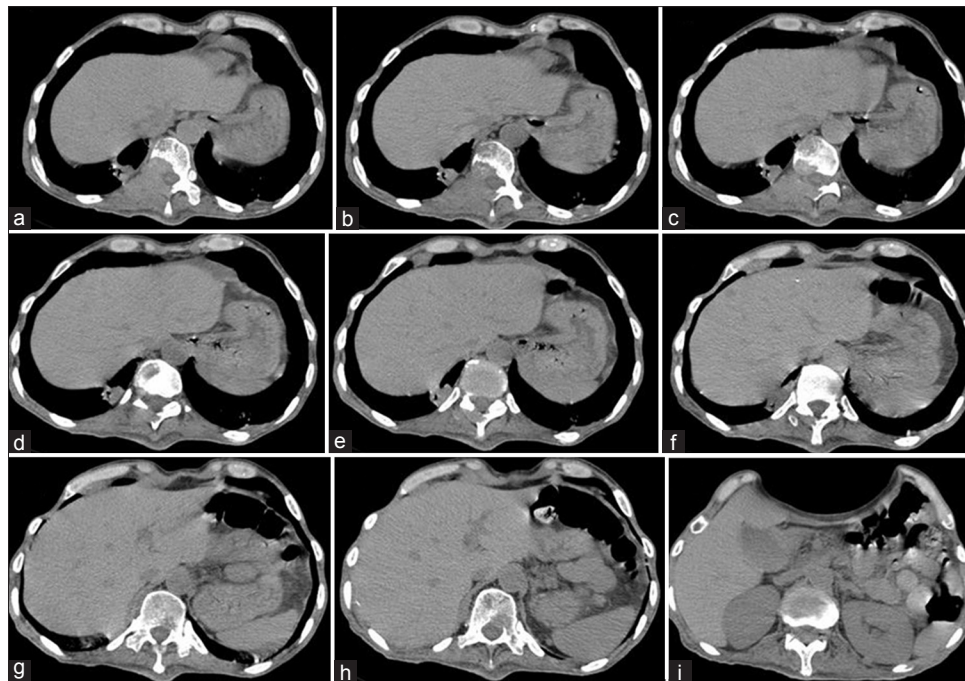


Figure 4: Transverse reconstruction of abdominal computed tomography scan (abdomen window): No pathological abnormality was diagnosed in the liver

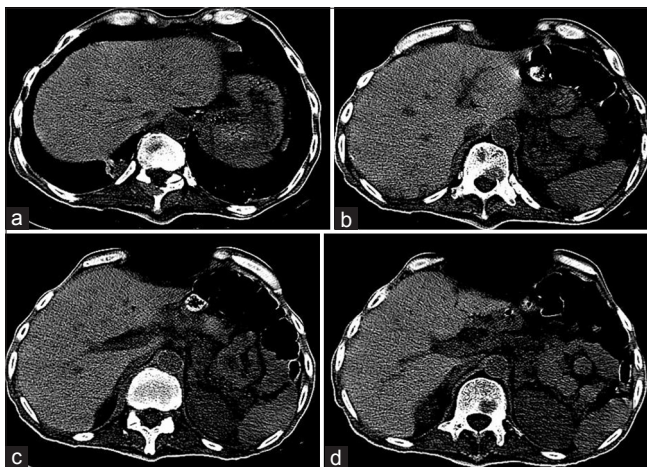


Figure 5: Transverse reconstruction of abdominal computed tomography scan (liver window): No pathological abnormality was diagnosed in the liver

There is a need to recognize the pathophysiological basis underlying such an uptake. This uptake in soft-tissue is believed to be due to chemisorption of Tc-99m MDP on the surface of calcium salts, including hydroxyapatite crystals.^[2] Probable mechanisms of increased soft-tissue calcium deposition are as follows:^[2]

- Increased ectopic osteoblastic activity
- Metastatic calcification
- Metastases from osteoid forming primary tumors
- Increase in calcium binding tissue cations (e.g., iron, magnesium)
- Dystrophic calcification (e.g., necrosis, hypoxia, tumor, amyloid).

Many of the reported instances of tumor uptake of MDP involves tissues with areas of necrosis that are prone to pathologic calcification and heterotopic bone formation.^[3] Hence it is possible, that an increased concentration of calcium ions is present in tumor cell, or at least in the dead or degenerating areas of the tumor. Metastatic calcification is soft-tissue deposition of ^{99m}Tc-MDP due to hypercalcaemia. It can be seen with increased secretion of parathormone, destruction of bone, vitamin-D related disorders, renal failure, aluminum intoxication secondary to chronic dialysis and milk-alkali syndrome. Extra-skeletal uptake on bone scan, in cases of renal failure, has been demonstrated due to failure of excretion of the radiopharmaceuticals through the kidneys. Splenic accumulation of the bone agent has been seen in the sickle-cell disease, assumed to be the result of splenic infarction and subsequent calcification.^[4] The undetected presence of amyloidosis also shows abnormal distribution of tracer when it involves the soft-tissues.^[5] Hepatic and other ectopic soft-tissue calcifications can also be seen following orthotopic liver transplantation, attributed to hyperparathyroidism, calcium administration during and after surgery, renal failure, acid-base change and citrate in fresh frozen plasma.^[6]

Hepatic uptake has been observed in patients undergoing bone scintigraphy and focal uptake is more frequent than diffuse hepatic activity. Focal tracer uptake is usually seen in the case of hepatic metastasis, whereas intense and diffuse liver uptake of the tracer has been

reported in case of severe hepatic necrosis^[7] which could be due to Budd-Chiari syndrome, amphotericin B toxicity, cocaine hepatotoxicity, ischemic hepatopathy, patients treated with high-dose methotrexate, epirubicin, cytotoxic antibiotic treatment, hemotherapy and rarely hypoxic hepatitis/necrosis^[8] as a complication of respiratory failure.

Faulty radiopharmaceutical preparations like formation of a Tc-99m colloid complex may be the cause of reticuloendothelial tissue uptake.^[9] In our case, hepatic Tc-99m-MDP uptake was evident but spleen uptake was not seen and bone scans performed on other patients on that day did not show any non-osseous uptake. Radiopharmacy quality control results of the 99mTc-MDP were reviewed and found to be normal. Other reason for diffuse hepatic uptake is residual radioactivity from 99mTc sulfur colloid used the previous day for a liver scan and misadministration of the radiopharmaceutical like 67Ga citrate or 111In labeled white blood cells. Our patient did not receive any radioisotope injection on previous day and misadministration was also excluded out.

Several cases of diffuse hepatic uptake on bone scan following an intravenous injection of iron colloid solutions have been reported. It is hypothesized that a Tc-99m iron-colloid complex is formed through transchelation of the MDP, yielding a compound with different organ affinity, which is taken up in the Kupffer cells of the liver.^[10] This does not appear to be the cause in our patient.

In our patient metastatic liver disease was virtually ruled out on the basis of a normal liver as demonstrated by CT scan. There was no history of liver transplantation. Our patient showed mild to moderate elevation of serum transaminase and lactate dehydrogenase tested after bone scintigraphy, which might reflect hepatic damage, leading to liver uptake of Tc-99m MDP. In our patient, the diffuse hepatic uptake of 99mTc-MDP was probably due to rarely seen hepatic hypoxic necrosis resulted from respiratory failure caused by bilateral miliary pulmonary metastasis was considered. Supporting finding was necrosis of head of right femur seen on bone scan, might be cause by the same pathology that is hypoxic ischemic necrosis. It seemed the only explanation because other common causes of diffuse liver uptake of MDP such as a prior 99mTc-sulfur colloid scan, faulty radiopharmaceutical preparation, misadministration, prior chemotherapy and hyperparathyroidism were excluded. Our patient died 2 days after bone Scintigraphy, may be due to posthypoxic multiorgan failure. Proper performance and interpretation of images depends on a sound understanding pathophysiologic basis

of the examination which may be of critical clinical relevance in the evaluation of the patient, which we have reviewed here. A high index of suspicion is the most important diagnostic aid that can prevent nuclear medicine physicians from overlooking the unusual cause of extraskeletal MDP tracer uptake. This case once again illustrates the value of scrutinizing the soft-tissues pathology on Scintigraphy, not visible on CT.

Acknowledgments

We would like to thank Dr. Ravi Gupta, CEO, Saral Diagnostics, Delhi, India and Dr. Chandrashekhar Debnath, Anaesthetist, Saral Diagnostics, Delhi, India for their continuous encouragement.

References

1. Zuckier LS, Freeman LM. Nonosseous, nonurologic uptake on bone scintigraphy: Atlas and analysis. *Semin Nucl Med* 2010;40:242-56.
2. Ergün EL, Kiratli PO, Günay EC, Erbaş B. A report on the incidence of intestinal 99mTc-methylene diphosphonate uptake of bone scans and a review of the literature. *Nucl Med Commun* 2006;27:877-85.
3. Fred HL, Eiband JM, Collins LC. Calcifications in intra-abdominal and retroperitoneal metastases: Review of the roentgenographic features. *Am J Roentgenol Radium Ther Nucl Med* 1964;91:138-48.
4. Goy W, Crowe WJ. Splenic accumulation of 99mTc-diphosphonate in a patient with sickle cell disease: Case report. *J Nucl Med* 1976;17:108-9.
5. Alavi A (ed). Worsley DR, Lentle BC (presentation and discussion). Uptake of Technetium-99m MDP in primary amyloidosis with a review of the mechanisms of soft tissue localization of bone seeking radiopharmaceuticals. *J Nucl Med*. 1993;34:1612.-1615.
6. Munoz SJ, Nagelberg SB, Green PJ, Angstadt JD, Yang SL, Jarrell BE, et al. Ectopic soft tissue calcium deposition following liver transplantation. *Hepatology* 1988;8:476-83.
7. Lin KH, Shih BF. Diffuse liver uptake of technetium-99m-MDP bone scan due to hepatotoxicity secondary to methotrexate therapy. *Ann Nucl Med Sci* 2005;18:111-5.
8. Shih WJ, Coupal J. Diffuse and intense Tc - HMDP localization in the liver due to hypoxia secondary to respiratory failure. *Clin Nucl Med* 1994;19:116-20.
9. MacDonald J. Idiopathic hepatic uptake of (99m) Tc methylene diphosphonate: A case report. *J Nucl Med Technol* 2001;29:32-6.
10. Park CH, Kim HS, Shin HY, Kim HC. Hepatic uptake of Tc-99m MDP on bone scintigraphy from intravenous iron therapy (Blutal). *Clin Nucl Med* 1997;22:762-4.

How to cite this article: Mahajan MS, Digamber NS, Sharma R. Technetium-99m-methylene Diphosphonate Uptake in Hepatic Necrosis Secondary to Respiratory Failure. *World J Nucl Med* 2013;12:116-9.

Source of Support: Nil, **Conflict of Interest:** None declared.