

## Original article

# Prevalence of Detecting Unknown Cerebral Metastases in Fluorodeoxyglucose Positron Emission Tomography/Computed Tomography and its Potential Clinical Impact

Boom Ting Kung, T. K. Auyong, C. M. Tong

Department of Radiology, Pong Ding Yuen Clinical PET/CT Centre and Nuclear Medicine Unit, Queen Elizabeth Hospital, Jordan, Kowloon, Hong Kong, China

## Abstract

To determine the prevalence of incidental finding of unknown cerebral metastases and explore the clinical impact of detecting unknown brain metastases among individuals underwent whole body fluorine 18 fluorodeoxyglucose (FDG) positron emission tomography/computed tomography (PET/CT) with brain included in field of view. A retrospective review of 1876 patients who underwent whole body PET/CT examination in our clinical PET center for oncological evaluation from January 2009 to September 2009 was performed. The total number and prevalence of unknown brain metastases detected by PET/CT were calculated. Patients diagnosed with cerebral metastases by PET/CT were further analyzed via the electronic patient record system for relevant clinical and radiological findings. Positive predictive value of PET/CT for the diagnosis of cerebral metastases was calculated with reference to contrast enhanced magnetic resonance imaging (MRI) or contrast enhanced CT. Of the 1876 subjects, 71 patients (3.8%) were diagnosed with cerebral metastases by PET/CT. 31 patients were already diagnosed with brain metastases before PET/CT. Among the 40 patients with unknown brain metastasis, 24 (60.0%) underwent either MRI ( $n=5$ ) or CT ( $n=19$ ) after PET/CT, of which 17 patients were confirmed with cerebral metastases. The true positive rate was 70.8% (17/24), while the false positive rate of PET/CT was 29.2% (7/24). Nearly 94.1% (16/17) patients with confirmed cerebral metastases on MRI or CT had subsequent change in management. Among the remaining 16 patients with positive findings of cerebral metastases without further radiological correlation, 43.8% (7/16) patients had change in management after PET/CT. A total of 57.5% (23/40) patients had change in management after PET/CT. The point prevalence of detecting unknown cerebral metastases by PET/CT was 2.1% (40/1876). 94.1% patients with newly diagnosed brain metastases confirmed with either MRI or CT received immediate treatment for cerebral metastasis in this retrospective study. PET/CT demonstrated significant clinical impact by identifying cerebral lesions with mass effect and hence that timely treatment was offered.

**Keywords:** Brain, cerebral metastases, fluorodeoxyglucose positron emission tomography/computed tomography, nonsmall cell lung cancer, prevalence

## Introduction

Accurate detection of brain metastases is crucial for prognosis, staging and choices of subsequent

therapy.<sup>[1,2]</sup> As a screening test for detection of brain metastases in oncology patients, fluorodeoxyglucose positron-emission tomography (FDG PET) is insensitive, particularly poor for small lesions due to limited spatial resolution of PET. Brain lesions can also be potentially masked by intense FDG uptake in brain parenchyma.<sup>[3]</sup> In one early study comprised of more than one thousand patients with various malignancies, incidental detection of cerebral metastases was only found in 0.4% of patients,<sup>[4]</sup> using FDG PET without hybrid computed tomography (CT) component. As a consequence, PET/CT is performed from skull base to

### Access this article online

#### Quick Response Code:



#### Website:

www.wjnm.org

#### DOI:

10.4103/1450-1147.139141

#### Address for correspondence:

Dr. Boom Ting Kung, Pong Ding Yuen Clinical PET/CT Centre and Nuclear Medicine Unit, Queen Elizabeth Hospital, 30 Gascoigne Road, Jordan, Kowloon, Hong Kong, China. E-mail: btkung425@gmail.com

upper thigh only in some PET centers without inclusion of brain.

With technological advances, hybrid positron-emission tomography (PET)/computed tomography scanner has assumed a more crucial role that it has been suggested as first line imaging modality for staging, restaging as well as treatment response assessment in several types of malignancies.<sup>[1]</sup> In our PET center, we always include brain as a routine protocol. We aim to identify not only the sizeable cerebral metastases, but metastases with midline shift or mass effect. As the potential benefit for including brain into PET/CT protocol has not been genuinely established, we perform this retrospective study to assess the prevalence of detecting previously unknown cerebral metastases by PET/CT. Clinical impact of identifying previously unknown cerebral metastases by PET/CT is also retrospectively reviewed.

## Patients and Methods

A retrospective review of 1876 individual patients who underwent whole body PET/CT examination (from vertex to mid-thigh) in our PET center, from Jan 2009 to September 2009 was performed.

The total number and prevalence of previously unknown brain metastases detected by PET/CT were calculated. Positive brain metastasis was diagnosed by the attending nuclear medicine physicians based on either the abnormal PET or CT findings. Abnormal PET findings included increased or decreased FDG metabolism. Abnormal CT findings included hyperdense or hypodense lesion associated with perifocal edema, as well as other clinically significant findings such as midline shift, cerebral herniations or hydrocephalus. Patients diagnosed with cerebral metastases by PET/CT were further analyzed via the electronic patient record system for relevant clinical and radiological findings. With reference to contrast enhanced magnetic resonance imaging (MRI) or contrast enhanced CT, positive predictive value of PET/CT for the diagnosis of cerebral metastases was calculated.

Concerning our PET/CT protocol, all patients were fasted for at least 6 h before 370 MBq of FDG was injected intravenously. Scanning was initiated 60 min after administration. Patients were allowed to breathe normally. Images were taken from the vertex to the proximal thigh with PET/CT scanner (Discovery LS, GE Healthcare) with a spatial resolution 6.6 mm in the center of the field of view. Image acquisition was performed with 3 min per bed position. Low dose CT was performed for attenuation correction and lesion localization. No intravenous contrast was given. The obtained images were reconstructed using ordered

subset expectation maximization iterative reconstruction algorithm, yielding axial, sagittal, and coronal slices. Z axis filter was used and a total of two iterations were performed. Dedicated 3D brain PET/CT imaging was acquired in equivocal cases. In the 3D brain imaging, 10 min per bed position was performed using 3D hanning filter. Fourier rebinning with filtered back projection was performed. Regions of interests were drawn for FDG uptake quantification on visible lesions with increased uptake, and the maximum standardized uptake value was semiquantitatively analyzed.

## Results

Of the 1876 subjects, 71 patients (3.8%) were diagnosed with cerebral metastases by PET/CT. 31 patients were already diagnosed with brain metastases before PET/CT. The remaining 40 (2.1%) patients with previously undiagnosed cerebral metastases were further reviewed. Among them, 24 (60.0%) underwent either MRI ( $n = 5$ ) or CT ( $n = 19$ ) after PET/CT. A total of 17 patients were confirmed with cerebral metastases, 4 patients had cerebral infarct and the remaining 3 patients had normal radiological findings. The true positive rate was 70.8% (17/24), while the false positive rate of PET/CT was 29.2% (7/24). About 40.0% of patients (16/40) did not receive further radiological correlation due to definite diagnosis by PET/CT.

Concerning its clinical impact, 94.1% (16/17) patients with confirmed cerebral metastases on MRI or CT had subsequent change in management. Among the 16 individuals with subsequent treatment for cerebral metastasis, 10 patients underwent whole brain radiation therapy (WBRT), 2 patients underwent craniotomy and 4 patients received intravenous steroid treatment. Only 1 patient had no change in management due to poor clinical condition.

Among the 16 patients with positive PET/CT findings of cerebral metastases without further radiological correlation, 43.8% (7/16) patients had change in management after PET/CT. Among the 7 individuals, 6 patients underwent WBRT and 1 patient underwent craniotomy. For the remaining 9 patients without change in management, 2 patients defaulted clinical follow-up, 2 patients refused further treatment for cerebral metastasis, 4 patient had poor clinical condition and 1 patient died within 24 h after PET/CT exam. In summary, a total of 57.5% (23/40) patients had change in management after PET/CT.

Among the 40 patients with newly diagnosed cerebral metastases in PET/CT, 25 patients had primary bronchogenic carcinoma, 7 patients had breast carcinoma, 3 patients had carcinoma of colon, 1 patient had

nasopharyngeal carcinoma, 1 patient had carcinoma of hypopharynx, 1 patient had prostate cancer, 1 patient had gastrointestinal stromal tumor, and 1 patient suffered from diffuse large B cell lymphoma. Within the study period, our PET center performed 327 CA lung cases, 317 CA colon cases and 275 CA breast cases. They accounted for 17.4% (327/1876), 16.9% (317/1876) and 14.7% (275/1876) of total PET/CT cases performed respectively. Among the 17 patients with confirmed cerebral metastases on MRI or CT, 82.3% (14/17) patients suffered from primary bronchogenic carcinoma.

## **Discussion**

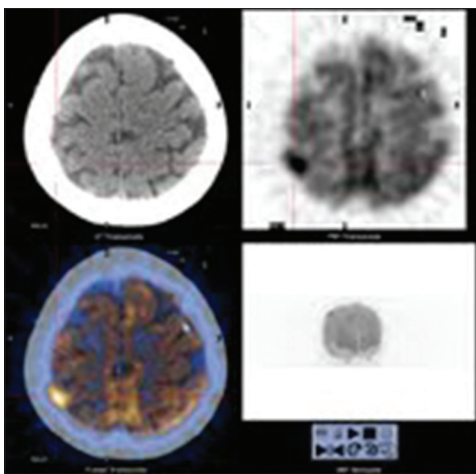
With improved survival rates in oncology patients due to advances in cancer therapy, rising incidence of brain metastases is noted in the past decade. CT and MRI remain the major radiological modalities for assessment of cerebral metastases. Contrast-enhanced MRI is regarded as the gold standard imaging concerning detection of cerebral metastasis. Compared to contrast-enhanced CT, it has higher image contrast, lack of partial volume effects and bone artifacts, as well as an inherently better soft tissue contrast resolution. In addition, MRI has better ability to identify small-sized and more number of cerebral metastases compared with contrast-enhanced CT.<sup>[5]</sup> In contrast, there are many studies that challenge the ability of FDG PET in detecting cerebral metastases. We design this study as we want to know if FDG PET/CT, with the assistance of hybrid low dose CT, can effectively detect sizeable cerebral metastases, particular those lesions with mass effect that patients can benefit from immediate treatment.

Admittedly, FDG PET is insensitive as a screening test for detection of brain metastases in oncology patients. In our study, the point prevalence of detecting unknown cerebral metastases by PET/CT was 2.1%. The hybrid PET/CT scanner, with the help of low dose CT, improved the detection rate of cerebral metastases compared with FDG PET alone (0.4% as illustrated in the introduction). Most importantly, the low dose CT helps to pick up cerebral deposits with significant mass effect. Most of our patients with brain metastases showed significant perifocal edema. Cerebral metastasis with mass effect can be life-threatening or lead to significant clinical morbidity. Immediate treatment can effectively reduce perifocal edema and minimize clinical morbidity and mortality. In this retrospective study, more than 90% patients with newly diagnosed brain metastases confirmed with either MRI or CT received immediate treatment for cerebral deposits. PET/CT demonstrated great clinical impact by identifying cerebral lesions with mass effect, so that timely treatment could be offered and hopefully improved the clinical morbidity.

Brain metastases are commonly encountered in patients with primary cancer of the lung, breast and colon. Among all types of malignancy, lung cancer has the highest frequency of cerebral metastases.<sup>[6,7]</sup> About 60% of brain metastases without known primary site are metastatic deposits from lung cancer.<sup>[8,9]</sup> According to a large scale study comprised of 975 surgically treated early-stage nonsmall cell lung cancer (NSCLC) patients, the 5 years actuarial risk of brain metastases was 10%. The risk of developing brain metastases after definitive treatment for locally-advanced NSCLC was approximately 30–50%.<sup>[10]</sup> For small cell lung cancer (SCLC), up to 10% patients can have brain metastases at the time of diagnosis.<sup>[11]</sup> In our study, of those patients with newly diagnosed cerebral metastases by PET/CT, 62.5% (25/40) patients suffered from primary bronchogenic carcinoma. During the study period, it accounted for only 17.4% (327/1876) of the total referrals. Our findings concur with the generally accepted fact that the most common primary site of metastatic brain lesion is lung cancer.<sup>[12]</sup>

In our study, 24 out of 25 lung cancer patients with newly diagnosed cerebral metastases belonged to NSCLC, while only one patient suffered from SCLC. Among the 24 NSCLC patients, 19 patients had hypermetabolic brain metastases while 5 patients had hypometabolic brain metastases. We found that brain metastases from NSCLC were mostly hypermetabolic rather than hypometabolic compared with the adjacent brain parenchyma. Our findings concur with other larger-scale study that NSCLC was more commonly associated with hypermetabolic rather than hypometabolic metastatic brain lesion.<sup>[13]</sup> On the other hand, FDG hypometabolism has been reported in brain metastases from both SCLC and NSCLC.<sup>[13,14]</sup> The two types of cancers had different biological and clinical characteristics.<sup>[15]</sup> Since we have only one SCLC patient (who had hypermetabolic brain metastasis), more SCLC cases are required for further comparison of metabolic behavior between the two groups of lung cancer.

In our study, among the 17 patients suffered from cerebral metastases subsequently confirmed with either MRI or CT, 13 patients received additional dedicated 3D brain PET imaging. Currently, routine whole-body 3D image acquisition was widely used for most of the latest PET/CT machine, in contrast to our older-generation PET/CT, which only enabled whole-body 2D image acquisition. In dedicated brain series, patient was instructed to lower their arms so as to avoid artefact from the raised arm position as in routine oncological protocol. It has higher sensitivity with better signal-to-noise ratio and lesion detection performance [Figure 1]. It is worthy to further explore if dedicated brain series should be routinely performed



**Figure 1:** 81 year old female with right lower lobe lung cancer.

Dedicated brain positron emission tomography/computed tomography series showed FDG avid brain metastasis at right high parietal region, maximum standardized uptake value up to 13.0

in patients undergo whole body PET/CT examination, particularly in those suffered from bronchogenic carcinoma.

This study had several limitations. First, dedicated 3D brain imaging was not performed in most of our patients underwent routine oncology protocols, which hampered the diagnostic accuracy for detection of cerebral metastases. Second, intravenous contrast material was not given in most of our patients in our routine protocol. Some studies showed that contrast-enhanced CT was more accurate for diagnosing cerebral metastases than unenhanced CT.<sup>[16,17]</sup> Moreover, with the low dose CT used in our oncology PET/CT protocol, it should be reminded that the diagnostic accuracy of CT in this study is worse compared with that of diagnostic CT brain. Lastly, CT and MRI findings, instead of histopathological confirmation, were regarded as the reference standard in this study. Histopathological confirmation would not be achieved in all suspected cases and hence other disease entities could be wrongly regarded as cerebral metastases.

## Conclusion

The point prevalence of detecting unknown cerebral metastases by PET/CT was 2.1%. 94.1% patients with newly diagnosed brain metastases confirmed with either MRI or CT received immediate treatment for cerebral metastasis in this retrospective study. PET/CT demonstrated significant clinical impact by identifying cerebral lesions with mass effect, so that timely treatment could be offered. Inclusion of brain within the field of view in PET/CT may be useful for evaluation of sizable cerebral metastases, particularly in patients suffered from primary bronchogenic carcinoma.

## References

1. Antoch G, Vogt FM, Freudenberg LS, Nazaradeh F, Goehde SC, Barkhausen J, *et al.* Whole-body dual-modality PET/CT and whole-body MRI for tumor staging in oncology. *JAMA* 2003;290:3199-206.
2. Young RF. Radiosurgery for the treatment of brain metastases. *Semin Surg Oncol* 1998;14:70-8.
3. Kim YS, Kondziolka D, Flickinger JC, Lunsford LD. Stereotactic radiosurgery for patients with nonsmall cell lung carcinoma metastatic to the brain. *Cancer* 1997;80:2075-83.
4. Ludwig V, Komori T, Kolb D, Martin WH, Sandler MP, Delbeke D. Cerebral lesions incidentally detected on 2-deoxy-2-[18F] fluoro-D-glucose positron emission tomography images of patients evaluated for body malignancies. *Mol Imaging Biol* 2002;4:359-62.
5. Suzuki K, Yamamoto M, Hasegawa Y, Ando M, Shima K, Sako C, *et al.* Magnetic resonance imaging and computed tomography in the diagnoses of brain metastases of lung cancer. *Lung Cancer* 2004;46:357-60.
6. Schouten LJ, Rutten J, Huvneers HA, Twijnstra A. Incidence of brain metastases in a cohort of patients with carcinoma of the breast, colon, kidney, and lung and melanoma. *Cancer* 2002;94:2698-705.
7. Barnholtz-Sloan JS, Sloan AE, Davis FG, Vigneaun FD, Lai P, Sawaya RE. Incidence proportions of brain metastases in patients diagnosed (1973 to 2001) in the Metropolitan Detroit Cancer Surveillance System. *J Clin Oncol* 2004;22:2865-72.
8. Knights EM Jr. Metastatic tumors of the brain and their relation to primary and secondary pulmonary cancer. *Cancer* 1954;7:259-65.
9. Cairncross JG, Kim JH, Posner JB. Radiation therapy for brain metastases. *Ann Neurol* 1980;7:529-41.
10. Boyd JA, Hubbs JL, Hollis DR, Kirkpatrick JP, Kim DW, Marks LB, *et al.* The actuarial incidence of brain metastases in 975 patients undergoing surgery for early-stage lung cancer. *J Clin Oncol* 2008;26 No 15S (May 20 Suppl), 2008:8094.
11. Giannone L, Johnson DH, Hande KR, Greco FA. Favorable prognosis of brain metastases in small cell lung cancer. *Ann Intern Med* 1987;106:386-9.
12. Crowley MJ, O'Brien DF. Epidemiology of tumours of the central nervous system in Ireland. *Ir Med J* 1993;86:87-8.
13. Lee HY, Chung JK, Jeong JM, Lee DS, Kim DG, Jung HW, *et al.* Comparison of FDG-PET findings of brain metastasis from non-small-cell lung cancer and small-cell lung cancer. *Ann Nucl Med* 2008;22:281-6.
14. Kamel EM, Zwahlen D, Wyss MT, Stumpe KD, von Schulthess GK, Steinert HC. Whole-body (18) F-FDG PET improves the management of patients with small cell lung cancer. *J Nucl Med* 2003;44:1911-7.
15. Delbaldo C, Le Péchoux C, Le Chevalier T. Combined modality treatment of lung cancer (NSCLC and SCLC). *Cancer Chemother Biol Response Modif* 2002;20:677-95.
16. Butler AR, Kricheff II. Non-contrast CT scanning: Limited value in suspected brain tumor. *Radiology* 1978;126:689-93.
17. Davis JM, Davis KR, Newhouse J, Pfister RC. Expanded high iodine dose in computed cranial tomography: A preliminary report. *Radiology* 1979;131:373-80.

**How to cite this article:** Kung BT, Auyong TK, Tong CM. Prevalence of Detecting Unknown Cerebral Metastases in Fluorodeoxyglucose Positron Emission Tomography/Computed Tomography and its Potential Clinical Impact. *World J Nucl Med* 2014;13:108-11.

**Source of Support:** Nil, **Conflict of Interest:** None declared