

## Case report

# Bilateral Diffuse Fluorodeoxyglucose Uptake in Thyroid Gland Diagnosed by Fluorodeoxyglucose-Positron Emission Tomography/Computed Tomography

Aung Zaw Win, Carina Mari Aparici<sup>1</sup>

Departments of Radiology, Nuclear Medicine Section, San Francisco Veteran Affairs Medical Center, <sup>1</sup>UCSF, San Francisco, CA, USA

## Abstract

Our patient is a female who was first diagnosed with breast cancer at the age of 23. A follow-up fluorodeoxyglucose-positron emission tomography/computed tomography (FDG-PET/CT) at age 44 revealed diffuse high FDG uptake in an enlarged thyroid gland. Fine-needle aspiration (FNA) of the thyroid mass revealed estrogen receptor/progesterone receptor negative, human epidermal growth factor receptor 2+ breast cancer. To the best of our knowledge, this is the first case to report breast cancer metastasis to the thyroid in a diffuse pattern on FDG-PET/CT. Bilateral diffuse uptake of FDG in thyroid is the most commonly associated with benign conditions. However, FNA biopsies need to be done to rule out metastatic disease in thyroid lesions with diffuse high FDG uptake, especially for patients with history of cancer.

**Keywords:** Breast cancer, diffuse, fluorodeoxyglucose-positron emission tomography/computed tomography, metastasis, thyroid

## Introduction

Positron emission tomography (PET) is a functional imaging modality, extensively used in the diagnosis, staging and surveillance of patients with neoplastic diseases. 18F-fluorodeoxyglucose (FDG) is a glucose analogue, and its accumulation within cells reflects glycolytic metabolism. Many malignancies metabolize glucose at a much higher rate than normal tissue. The most common site of breast cancer metastasis include: Bone, liver, lung, and brain.<sup>[1]</sup> Immunohistochemical markers associated with breast cancer metastasis to thyroid include MGB2, carcinoembryonic antigen,

estrogen receptor (ER), progesterone receptor (PR), and human epidermal growth factor receptor 2 (HER2).<sup>[1]</sup> Most often, breast neoplasms metastasize to the thyroid gland through the hematogenous route. Abnormal FDG uptake in thyroid is usually detected during initial diagnosis or re-staging of tumors from elsewhere in the body. Primary tumors of the thyroid are more common than metastases. The incidence of secondary malignancies in the thyroid is as low as 0.05%.<sup>[2]</sup> Thyroid metastases are uncommon in standard clinical practice, and most metastases are discovered only at autopsy.<sup>[3]</sup> In their study Papi *et al.* they found that thyroid metastasis from a given primary tumor histotype varies widely, depending on ethnic/demographic and epidemiological differences in major cancer types in the different populations.<sup>[4]</sup> It is not always easy to correctly diagnose thyroid metastasis from primary thyroid cancer. In clinical cases, the most common type of secondary metastasis to thyroid is renal carcinoma.<sup>[3]</sup>

### Access this article online

#### Quick Response Code:



Website:  
www.wjnm.org

DOI:  
10.4103/1450-1147.139147

#### Address for correspondence:

Dr. Aung Zaw Win, Department of Radiology, Division of Nuclear Medicine, San Francisco Veteran Affairs Medical Center, 4150 Clement Street, San Francisco, CA 94121, USA. E-mail: aungzwin@gmail.com

## Case Report

Our patient is a 44-year-old woman who was first diagnosed with breast cancer at age 23 and underwent subsequent left mastectomy. The HER2+ tumor was about 5 cm and 14 out of 20 axillary lymph nodes were positive. Then, she received radiation therapy and four cycles of cyclophosphamide, doxorubicin, and fluorouracil. 1 year later, she had autologous bone marrow transplantation with stem cell rescue and had four cycles of cyclophosphamide, thiotepa and mitoxantrone, followed by radiation therapy. 5 years later, she had a prophylactic right mastectomy. 1 year after, a left supraclavicular node was found to be positive for ER+, PR- breast cancer metastasis. Bone scan showed metastasis in the right scapula. Despite the treatment with docetaxel, the left supraclavicular node grew in size. As a result, the treatment was changed to vinorelbine and trastuzumab and continued for 2 more years. No disease was evident after 2 years, so she was maintained on tamoxifen and zoledronate for 10 years. Genetic testing was negative for p53, BRCA1, BRCA2, MLH1, MSH2, MSH6, PMS2, and EPCAM.

Last year, our patient developed a cough, and noted shortness of breath, while climbing stairs. She went to urgent care, and a chest X-ray showed an enlarged heart. Computed tomography (CT) scan revealed a large pericardial effusion, small bilateral pleural effusions, and pulmonary edema. Cytology of the pericardial effusion was consistent with breast cancer. She was discharged with tamoxifen and shortly afterwards, she began to experience difficulty writing, and occasional episodes of right hand twitching. Magnetic resonance imaging of the brain showed cystic and solid enhancing masses suspicious for metastases. As a next step in management, the patient had FDG-PET/CT exam and it showed intensely hypermetabolic bilateral cervical, mediastinal, and hilar nodes, as well as diffuse heterogeneous involvement of the enlarged thyroid gland, all of which are suspicious for malignancy [Figure 1]. Fine-needle aspiration (FNA) biopsy of the thyroid mass revealed ER/PR-, HER2+ metastatic breast cancer. The patient underwent radiation therapy and the tumor responded well to treatment [Figure 2].

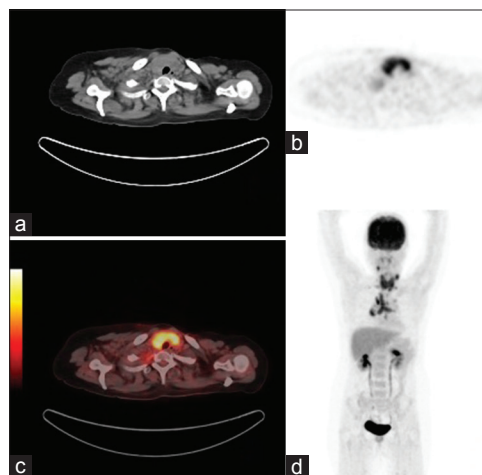
## Discussion

To our knowledge, this is the first case to report the breast cancer metastasis to the thyroid presenting in a diffuse uptake pattern on FDG-PET/CT. This is also the 1<sup>st</sup> time reporting of the spread of breast cancer to thyroid, heart, and pericardium and right scapular locations in the same patient. In addition, there was wide spread metastasis to the brain, bone, lymph nodes, and the lungs. Similar to the thyroid metastasis, metastasis to the pericardium can

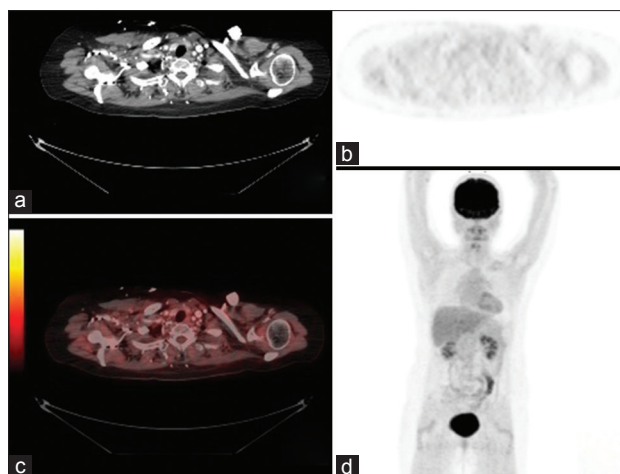
be clinically silent, usually found in patients over 60 and can be diagnosed in advanced stages of breast cancer.<sup>[5]</sup> Breast cancers tend to metastasize to the pericardium by lymphatic route.<sup>[5]</sup> Reports of breast cancer metastasizing to the scapula are rare.<sup>[6]</sup> There is a predilection for the brain by HER2+ tumor cells and HER2 expression is also responsible for distant recurrence.<sup>[7]</sup> Furthermore, young age and ER negativity are also associated with increased risk for brain metastasis.<sup>[7]</sup>

Our patient developed thyroid metastasis 21 years after initial diagnosis. The involvement of the thyroid can be at the same time or from a few months to 22 years after the diagnosis of the primary breast tumor.<sup>[8]</sup> Metastatic disease involving the thyroid is usually observed in elderly individuals in their sixth and seventh decades of life.<sup>[9]</sup> Our patient is 44 and she is the youngest patient reported for breast cancer metastasis to thyroid. Thyroid metastases are usually diagnosed in advanced stages of breast cancer. Metastases to the thyroid gland does not depend on histological type of the breast carcinoma.<sup>[1]</sup> In the thyroid, breast cancers usually present as single or multiple nodules. Papi *et al.* in their study have reported that a palpable thyroid nodule was found in 72% of patients with metastasis to thyroid.<sup>[4]</sup> In our patients, there was absence of nodules.

Nontoxic goiter (an enlarged thyroid) is more than twice as common in the breast cancer patients. Most commonly, patients reported the feeling of pressure and enlarged neck circumference. Therefore, some patients with metastatic lesions present with hoarseness, dysphagia,



**Figure 1:** Fluorodeoxyglucose-positron emission tomography/computed tomography (FDG-PET/CT) images of the patient at the time of re-staging 21 years after initial diagnosis of breast cancer. (a) CT image showing a diffusely enlarged thyroid gland (b) FDG image showing bilateral, diffuse, intensely hypermetabolic FDG uptake in the thyroid gland (c) hybrid PET/CT fusion images at the level of the thyroid gland (d) Maximum intensity projection image showing intensely hypermetabolic breast cancer metastasis to the thyroid gland, bilateral cervical, mediastinal and hilar lymph nodes



**Figure 2:** Fluorodeoxyglucose-positron emission tomography/computed tomography (FDG-PET/CT) images of the same patient after treatment, showing treatment response. (a) CT image at the level of the thyroid shows significant decrease in size from the prior exam (b) FDG image at the level of the thyroid showing normal mild diffuse FDG activity (c) Hybrid PET/CT fusion image at the level of the thyroid (d) MIP image showing normal thyroid biodistribution and treatment response

stridor and dyspnea, but respiratory problems are less frequent symptoms and occur mostly when the disease develops quickly. Shortness of breath in our case was out of proportion to echo findings (EF 67%) and it may be due to a combination of thyroid enlargement, pulmonary and pericardial effusions.

Thyroid and breast cancer sometimes occur in the same patient and a relationship between breast and thyroid carcinoma exists.<sup>[2]</sup> Mutations in the PTEN gene predisposes to both breast and thyroid cancer in a syndrome known as Cowden disease, an autosomal dominant disorder.<sup>[2]</sup> Hence, our case offered several diagnostic possibilities: Primary thyroid neoplasm, benign thyroid disease and breast cancer metastasis. Even though, our patient had breast cancer at age 23, the absence of breast or thyroid cancers in the family history ruled out Cowden disease. As a result, we were left with benign thyroid disease or secondary metastasis and the diffuse pattern of FDG uptake favored a benign condition before the FNA biopsy.

Most often, benign thyroid diseases such as Hashimoto's thyroiditis is found in patients with breast cancer. The finding of diffusely increased uptake in the thyroid gland is primarily associated with chronic autoimmune thyroiditis, with or without the presence of hypothyroidism.<sup>[10]</sup> Our patient had no history of thyroid disorders. Kim *et al.* found that young age, bilateral primary breast cancer, and radiotherapy are each independently associated with the development of diffuse thyroid FDG uptake.<sup>[11]</sup> Diffuse uptake chronic thyroiditis is not associated with ER and PR status in breast cancer.<sup>[10]</sup> The biopsy result showed ER

and PR negativity in our patient. Rothman *et al.* stated that diffuse thyroid FDG uptake is not indicative of lesions of malignant potential.<sup>[12]</sup> Diffuse uptake can also be found in a normal thyroid. A focal thyroid lesion with significant uptake is likely to be malignant whereas diffuse increased uptake in the thyroid glands favors several thyroidal disorders, which include chronic thyroiditis, Graves' disease, diffuse goiter, and multinodular goiter.<sup>[13]</sup> The risk of malignancy was as high as 63.6% in thyroid lesions with focal uptake.<sup>[14]</sup> From the literature review, all other cases of breast cancer metastasis to thyroid had focal uptake.<sup>[15,16]</sup>

Yet, in our case, metastatic breast cancer presented as diffuse FDG uptake. Activated lymphocytes show enhanced glucose metabolism in chronic thyroiditis. Fibroblast infiltration also leads to uptake of 18F-FDG in patients with chronic thyroiditis.<sup>[10]</sup> In Grave's disease, the increased uptake is caused by hypermetabolic thyrocytes. The reason why a metastatic breast cancer presented as a diffuse pattern remains a mystery. Since the patient had involvement of the pericardium and breast cancers metastasize to the pericardium by lymphatic route,<sup>[5]</sup> we hypothesized that the diffuse involvement of the thyroid gland could be the result of a lymphatic route of metastatization, in contrary to a more focal involvement which could relate more to the expected hematogenous route of metastatization. Thus, for thyroid lesions with diffuse FDG uptake, FNA biopsies need to be done to rule out metastatic disease, especially for patients with history of cancer.

## References

1. Lacka K, Breborowicz D, Uliasz A, Teresiak M. Thyroid metastases from a breast cancer diagnosed by fine-needle aspiration biopsy. Case report and overview of the literature. *Exp Oncol* 2012;34:129-33.
2. Leboeuf R, Bénard F, Langlois MF. Thyroid cancer presenting as a PET incidentaloma in a patient with concomitant breast cancer metastases to the thyroid. *Clin Nucl Med* 2006;31:382-5.
3. Egaña N, Socias C, Matteucci T, Bilbao I, Alvarez-Coca M. Thyroid metastasis of lobular breast carcinoma. *Endocrinol Nutr* 2012;59:219-20.
4. Papi G, Fadda G, Corsello SM, Corrado S, Rossi ED, Radighieri E, *et al.* Metastases to the thyroid gland: Prevalence, clinicopathological aspects and prognosis: A 10-year experience. *Clin Endocrinol (Oxf)* 2007;66:565-71.
5. Katalinic D, Stern-Padovan R, Ivanac I, Aleric I, Tentor D, Nikolac N, *et al.* Symptomatic cardiac metastases of breast cancer 27 years after mastectomy: A case report with literature review – Pathophysiology of molecular mechanisms and metastatic pathways, clinical aspects, diagnostic procedures and treatment modalities. *World J Surg Oncol* 2013;11:14.
6. Benson EC, Drosdowech DS. Metastatic breast carcinoma of the coracoid process: Two case reports. *J Orthop Surg Res* 2010;5:22.
7. Wadasadawala T, Gupta S, Bagul V, Patil N. Brain metastases from breast cancer: Management approach. *J Cancer Res Ther* 2007;3:157-65.

8. Nakhjavani MK, Gharib H, Goellner JR, van Heerden JA. Metastasis to the thyroid gland. A report of 43 cases. *Cancer* 1997;79:574-8.
9. Zhou XC, Hu KQ, Zhang XF, Ye YH, Jiang Y, Pan F, *et al.* Breast cancer metastatic to the bilateral thyroid: A case report. *Head Neck Oncol* 2012;4:51.
10. Kim SS, Kim IJ, Kim SJ, Lee JY, Bae YT, Jeon YK, *et al.* Incidental diffuse thyroid 18F-FDG uptake related to autoimmune thyroiditis may be a favorable prognostic factor in advanced breast cancer. *J Nucl Med* 2012;53:1855-62.
11. Kim SS, Kim SJ, Bae YT, Lee JY, Kim BH, Kim YK, *et al.* Factors associated with the development of new onset diffuse thyroid F18-fluorodeoxyglucose uptake after treatment of breast cancer in patients without a history of thyroid disease or thyroid dysfunction. *Thyroid* 2012;22:53-8.
12. Rothman IN, Middleton L, Stack BC Jr, Bartel T, Riggs AT, Bodenner DL. Incidence of diffuse FDG uptake in the thyroid of patients with hypothyroidism. *Eur Arch Otorhinolaryngol* 2011;268:1501-4.
13. Tateishi U, Gamez C, Dawood S, Yeung HW, Cristofanilli M, Inoue T, *et al.* Chronic thyroiditis in patients with advanced breast carcinoma: Metabolic and morphologic changes on PET-CT. *Eur J Nucl Med Mol Imaging* 2009;36:894-902.
14. Chen W, Parsons M, Torigian DA, Zhuang H, Alavi A. Evaluation of thyroid FDG uptake incidentally identified on FDG-PET/CT imaging. *Nucl Med Commun* 2009;30:240-4.
15. Hsu CH, Wu CH, Chu JS. Metastatic cancer in thyroid detected by FDG PET. *Clin Nucl Med* 2006;31:51-2.
16. Gianoukakis AG, Karam M, Cheema A, Cooper JA. Autonomous thyroid nodules visualized by positron emission tomography with 18F-fluorodeoxyglucose: A case report and review of the literature. *Thyroid* 2003;13:395-9.

**How to cite this article:** Win AZ, Aparici CM. Bilateral Diffuse Fluorodeoxyglucose Uptake in Thyroid Gland Diagnosed by Fluorodeoxyglucose-Positron Emission Tomography/Computed Tomography. *World J Nucl Med* 2014;13:138-41.

**Source of Support:** Nil, **Conflict of Interest:** None declared