Article published online: 2022-05-18

Case report

Evaluation and Identification of Lumbosacral Transitional Vertebra Causing Intractable Low Back Pain Utilizing Bone Single-Photon Emission Tomography with Computed Tomography

Khulood S. Al Riyami, Suliman M. Alahmed, Ziauddin Z. Saad, Jamshed Bomanji

Department of Nuclear Medicine, University College London Hospital, London, UK

Abstract

The cause of low back pain due to lumbosacral transitional vertebra (LSTV) still remains a debated topic. Functional imaging with bone scintigraphy has been a valuable adjunct in its assessment; however, in recent years, the additional utility of single-photon emission tomography with computed tomography (SPECT/CT) is evolving as the imaging modality of choice in identifying range of complex lower back pain sources, leading to the provision of suitable treatment options. We present a case demonstrating a variant type of LSTV as a source of pain localized and delineated on hybrid SPECT/CT imaging treated by minimally invasive microendoscopic resection of the pseudoarticulations.

Keywords: Low back pain, lumbosacral transitional vertebra, single-photon emission tomography with computed tomography

Introduction

This case report shows the added value of single-photon emission tomography with computed tomography (SPECT/CT) in pointing out the possible pain generator sites in patients with lumbosacral translation vertebra and low back pain. The presence of osteoblastic activity at the sites of pseudoarthrosis at the anomaly site supports the implication of Bertolotti syndrome in this group of patients.

Case Report

A 36-year-old female with a long history (>6 years) of lower back pain with intermittent symptoms in the right leg was referred to our department for bone scintigraphy coupled with SPECT/CT of lumbosacral spine to look for any pain generator. There was no significant medical or surgical history and detailed previous bone workup including conventional imaging could not identify the longstanding cause. In addition, she received series of therapeutic injections in lumbosacral region but was uneventful.

The planar bone scintigraphy images showed increased tracer (^{99m}Tc-methylene diphosphonate) uptake at the lumbosacral junction with slight prominence toward the right side. The SPECT/CT of the lumbosacral spine, however, demonstrated variant form of unilateral right-sided lumbosacral translational vertebra. A small well-corticated bone between the right upper sacrum and the right L5 vertebral transverse process with significantly increased osteoblastic activity at both bone-transverse process pseudoarticulation

Address for correspondence:
Dr. Khulood S. Al Riyami, Department of Nuclear Medicine, University College London Hospital, 235 Euston Road, London, UK.
E-mail: khuloodal.riyami@uclh.nhs.uk

Access this article online

Quick Response Code:

Website: www.wjnm.org

DOI: 10.4103/1450-1147.215495

How to cite this article: Al Riyami KS, Alahmed SM, Saad ZZ, Bomanji J. Evaluation and identification of lumbosacral transitional vertebra causing intractable low back pain utilizing bone single-photon emission tomography with computed tomography. World J Nucl Med 2017;16:328-30.

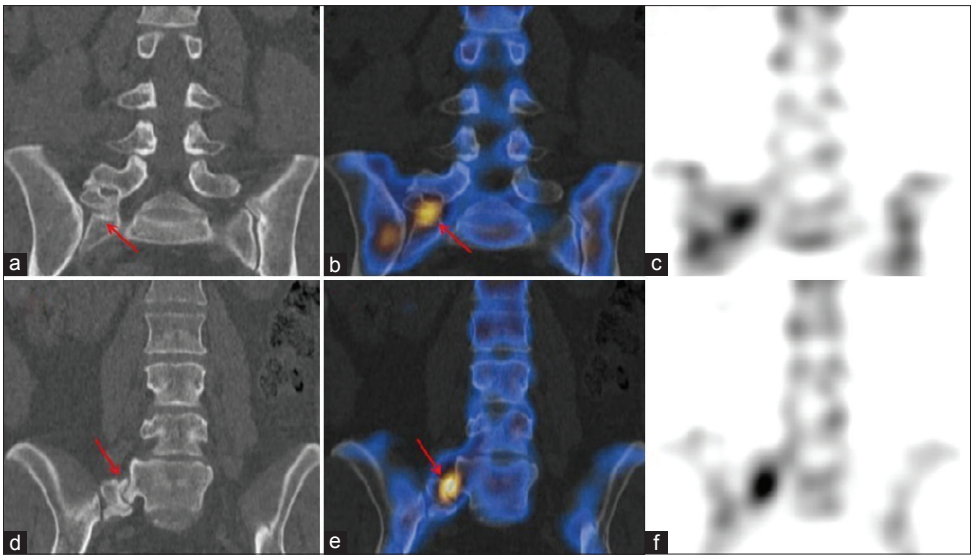

Figure 1: (a and d) coronal computed tomography; (b and e) fused single-photon emission tomography with computed tomography; (c and f) coronal single-photon emission tomography shows increased osteoblastic activity at both articulation sites (pseudoathrosis) of the well-corticated bone with L5 (d and e arrows) and sacral ala (a and b arrows)

sites [Figure 1]. Other than this, no facetal or sacroiliac joint arthropathy was observed. The patient was treated with surgical resection and now remains pain-free at 18-month follow-up.

Discussion

During the last 5–6 years, evaluation of back pain in particular lower back utilizing SPECT/CT modality to assess for pain generators has gained popularity and emerging as new subspecialist indication in nuclear medicine. The described changes in the biomechanics of weight-bearing across the lumbosacral junction lead to morphological alteration at vertebral joints[1] for which hybrid bone SPECT/CT has shown to be a valuable additional tool in assessment.[2]

The prevalence of lumbosacral transitional vertebrae (LSTV) is around 20.8%,[3] and unilateral sacralization is seen up to 7.4% of the population.[4] The implication of LSTV on the back has been a topic of debate since the term "Bertolotti Syndrome" was introduced in 1917, which described the relationship between low back pain and LSTV. Many papers have since supported this association.[5-8]

Radiographic classification of LSTV has been described by Castellvi *et al*. in 1984, in which four types are identified based on the morphological characteristics.[5]

The cause of low back pain secondary to this anomaly has been described to arise from different anatomic locations which include: (1) posterior element, spinal canal, and disc pathology from the level superior to the transition. (2) Spondylosis of the atypical articulation between the sacrum and LSTV. (3) Facet joint degeneration on the opposite side to the unilateral fused or articulating LSTV; and (4) extraforaminal compromise due to a widened transverse process.[5]

The management of low back pain secondary to LSTV varies according to the underlying cause and is divided into conservative treatment including local injection of anesthetic, corticosteroids, radiofrequency ablation, and surgery. There are broadly two surgical approaches for management of low back pain secondary to Bertolotti syndrome: Resection of the pseudoarticulation region and spinal arthrodesis.[6,9] Surgery is reserved for selected patients, ideally after a multidisciplinary team discussion, where LSTV is established as the true source of pain.

This case report highlights an atypical form of LSTV Type IIa as per Castellvi *et al*.'s description, in which there are two anomalous sites of pseudoarticulation formed between the accessory corticated bone and transverse process, in addition to the sacrum. We believe that lumbosacral SPECT/CT can play an improvised role in helping referrers and physicians in localizing the underlying cause of low back pain in LSTV earlier than other imaging modalities. Furthermore, SPECT/CT can help differentiate between a metabolically active and chronic burntout disease which may show features of degeneration, without any ongoing activity.[10]

Financial support and sponsorship
Nil.

Conflicts of interest
There are no conflicts of interest.

References

1. Mahato NK. Facet dimensions, orientation, and symmetry at L5-S1 junction in lumbosacral transitional states. Spine J 2011;36:E569-73.
2. Pekindil G, Sarikaya A, Pekindil Y, Gültekin A, Kokino S. Lumbosacral transitional vertebral articulation: Evaluation by planar and SPECT bone scintigraphy. Nucl Med Commun 2004;25:29-37.
3. Muir JM. Partial lumbosacral transitional vertebrae: 2 cases of unilateral sacralization. J Chiropr Med 2012;11:77-83.
4. Kamanli A, Genc H. Radiological abnormalities of the lumbosacral spine in young male individuals. J Back Musculoskelet Rehabil 2002;16:91-4.
5. Castellvi AE, Goldstein LA, Chan DP. Lumbosacral transitional vertebrae and their relationship with lumbar extradural defects. Spine (Phila Pa 1976) 1984;9:493-5.
6. Konin GP, Walz DM. Lumbosacral transitional vertebrae: Classification, imaging findings, and clinical relevance. AJNR Am J Neuroradiol 2010;31:1778-86.
7. Luoma K, Vehmas T, Raininko R, Luukkonen R, Riihimäki H. Lumbosacral transitional vertebra: Relation to disc degeneration and low back pain. Spine (Phila Pa 1976) 2004;29:200-5.
8. Taskaynatan MA, Izci Y, Ozgul A, Hazneci B, Dursun H, Kalyon TA. Clinical significance of congenital lumbosacral malformations in young male population with prolonged low back pain. Spine (Phila Pa 1976) 2005;30:E210-3.
9. Santavirta S, Tallroth K, Ylinen P, Suoranta H. Surgical treatment of Bertolotti's syndrome. Follow-up of 16 patients. Arch Orthop Trauma Surg 1993;112:82-7.
10. Fogelman I, Maisey MN, Clarke SE. An Atlas of Clinical Nuclear Medicine. London: Martin Dunitz; 1996. p. 77.