

## CASE ILLUSTRATION WITH REVIEW

# Post-craniotomy blindness in the supine position: Unlikely or ignored?

Payman Vahedi<sup>1,2</sup>, Ali Meshkini<sup>3</sup>, Zahra Mohajernezhadfar<sup>4</sup>, R. Shane Tubbs<sup>5</sup>

<sup>1</sup>Department of Neurosurgery, Eberhard Karls University Tübingen, Germany, <sup>2</sup>Nishabour Faculty of Medicine, Mashad University of Medical Sciences, Mashad, <sup>3</sup>Tabriz University of Medical Sciences, Tabriz, <sup>4</sup>Department of Ophthalmology, Eye Research Center, Farabi Eye Hospital, Tehran University of Medical Sciences, Tehran, Iran, <sup>5</sup>Department of Pediatric Neurosurgery, Children's Hospital, Birmingham, Alabama, USA

## ABSTRACT

Immediate visual loss following craniotomy in the supine position is a disastrous complication in neurosurgical patients. The incidence is unknown and little is known on the definite pathogenesis. Also, preventive or restorative interventions are unclear. We describe the rare case of post-craniotomy optic neuropathy and sudden visual loss after craniotomy in the supine position for an olfactory groove meningioma, discuss the possible pathophysiology and review the literature on the pathogenesis, risk factors, and outcome. Although rare, neurosurgeons, as well as neuroanesthesiologists should be aware of the possibility of this devastating complication in the high-risk group of patients.

**Key words:** Craniotomy, ischemic optic neuropathy, papilledema, pathophysiology, visual loss

## Introduction

Sudden blindness after craniotomy in the supine position has been rarely discussed in the literature. Although the potential for blindness in the prone position is well known following spinal surgery,<sup>[1,2]</sup> blindness after an uncomplicated craniotomy is unfamiliar to many neurosurgeons and many are unaware of its existence.

Despite initial description of the complication by some authors<sup>[3-6]</sup> in the 1970's with their experience after ventriculography or ventricular decompression procedures, its importance has been neglected in the literature thereafter. Different names, such as post-decompression optic neuropathy, orbital infarction syndrome and postoperative visual loss (PVL), have been used by some<sup>[7-10]</sup> to explain the possible contributing mechanisms leading to the blindness. Although this has shed some light on the issue, the nature of this complication still remains elusive.

A rare case of sudden blindness following an uneventful craniotomy in the supine position is presented and the possible etiologies and medico-legal issues are discussed.

## Case Report

### History

A 37-year-old female patient presented with a 5 months history of constant pulsatile frontal headache. The headaches were only somewhat responsive to paracetamol but she had to take narcotics to get to sleep. Recently, she had noticed that she was unable to distinguish smells while cooking and the food had a different taste for her.

### Physical examination

Neurological exam revealed anosmia and bilateral papilledema more severe on the left side. Visual acuity was 20/20 and 20/40 in the right and left eyes, respectively. The remainder of the physical exam and the laboratory tests were all within normal range.

### Imaging

Axial brain CT scan was performed and demonstrated an extra axial hyperdense interhemispheric space-occupying lesion within the anterior cranial fossa. Surrounding vasogenic edema was evident. Brain magnetic resonance imaging (MRI) with and without contrast revealed the mass that was isointense relative to the gray matter on T1 and T2-weighted images. The tumor showed a homogenous contrast uptake with gadolinium injection suggesting an olfactory meningioma [Figure 1].

Access this article online	
Quick Response Code:	Website: www.asianjns.org
	DOI: 10.4103/1793-5482.110278

### Address for correspondence:

Dr. Zahra Mohajernezhadfar, Department of Ophthalmology, Farabi Eye Hospital, Tehran University of Medical Sciences, Tehran, Iran.  
E-mail: zmfard@gmail.com

## Operation

The patient was operated in the supine position and the head was placed in the neutral position. A bifrontal craniotomy was performed over the superior sagittal sinus (SSS). The dura was opened in a linear fashion on both sides of SSS and it was ligated at its anterior third. Gross total resection of the firm tumor was made, the infiltrated dura was resected and the tumor's adhesions to the anterior skull base were coagulated (Simpson grade II).

## Post-operative course

The patient awoke with sudden bilateral blindness. Her vision was no light perception (NLP) in both eyes. Extraocular movement and IOP were normal. Fundoscopy revealed no apparent change. The anesthesiologist records documented no intra-operative hypotension. Early axial brain CT scan excluded the possibility of developing mass effect and 24 h brain MRI showed no residual tumor. One main concern was the possibility of inadvertent surgical trauma to the optic nerves or chiasm. Review of the operative video excluded this possibility, as well as any external pressure on the eyes during the surgery. Visual evoked potential (VEP) responses were completely abolished in both eyes.

## Follow-up

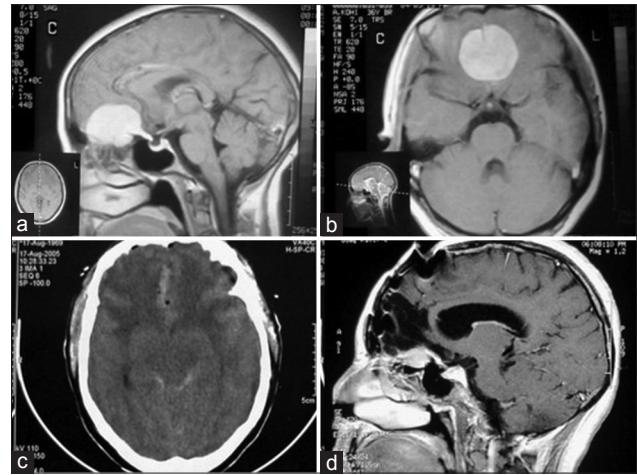
Serial therapeutic lumbar punctures (LP) were done and high dose methylprednisolone were given for three days with the hope to resolve possible optic nerve entrapment, which was unsuccessful. After six weeks post-procedure, she gained some light perception in her right eye. Follow-up fundoscopy revealed bilateral optic disc atrophy after two months. During 52 months follow up, her visual status showed no improvement. Fundoscopy revealed bilateral optic atrophy [Figure 2].

Informed consent was sought and granted from the patient's family to report this case.

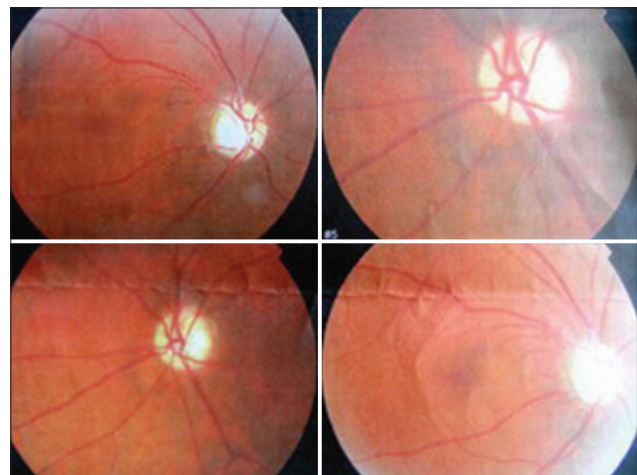
## Discussion

Sudden blindness following an uncomplicated craniotomy in the supine position is a rarely discussed entity in the literature. Although a few cases have been reported in the medical literature, the true incidence is not known. The reason might be the fact that most cases cannot find their way into the literature because of the vague pathophysiology of this complication. Hence, addressing this debatable complication not only helps to highlight the possible pathophysiology(ies), but also has medico-legal applications.

Holmes<sup>[11]</sup> was the first to describe the occurrence of visual loss after simple craniotomies. Although his two patients with preoperative increased ICP experienced blindness after decompressive craniotomies, it is possible that the mechanism of progressive blindness in his patients was different from the immediate post-operative blindness issued by the next authors, as well as in our case.



**Figure 1:** (a and b) Pre-operative sagittal and axial T1-weighted MRI with gadolinium contrast injection showing the homogenous enhancement by an olfactory groove meningioma. (c) Immediate post-operative brain CT shows tumor removal and vasogenic brain edema. (d) Post-operative sagittal T1-weighted MRI with gadolinium contrast reveals near total resection of the tumor



**Figure 2:** Post-operative fundus photography 4 months after surgery shows bilateral optic disc atrophy, which is more severe in the left eye

In 1949, Suchs<sup>[12]</sup> described the case of a 16-year-old girl with a cerebellar tumor and papilledema who became blind one day after tumor removal. The cause of the blindness in this patient was also likely different from patients awakening from anesthesia with blindness.

The issue was further discussed by Rinaldi, *et al.*,<sup>[6]</sup> in 1962, who witnessed blindness following decompressive surgery for increased ICP in five patients. Although they hypothesized occipital infarction as the possible mechanism, only one patient proved to have true occipital infarction at autopsy. It is possible that some of these patients might have had optic neuropathy. These may be the first descriptions of sudden visual loss after craniotomy in the supine position in the literature.

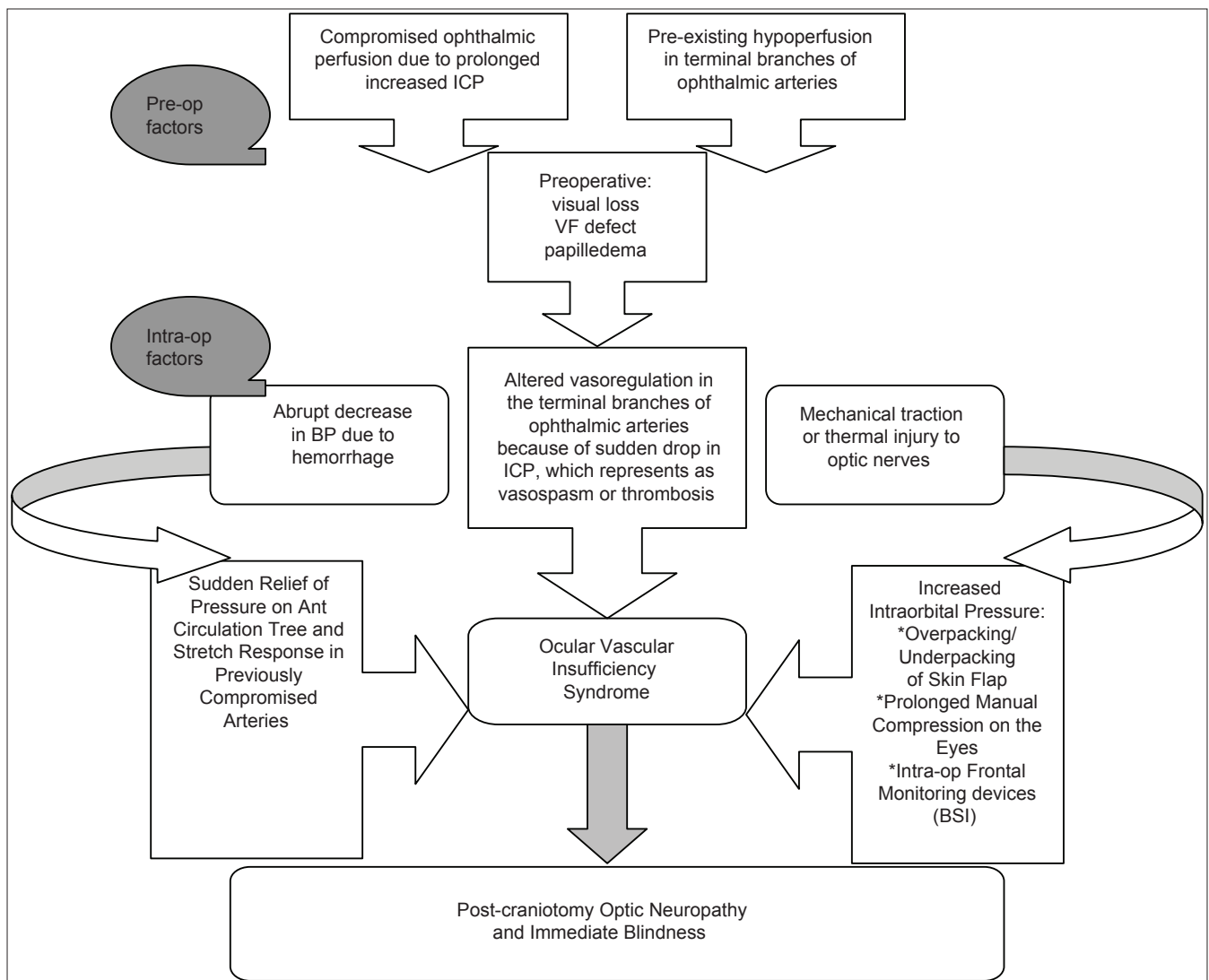
Later, in 1970, Obenchain *et al.*<sup>[5]</sup> reported blindness after decompressive surgery in three patients with cerebellar

astrocytoma, frontal lobe astrocytoma, and hydrocephalus due to aqueductal obstruction. Some years later, the role of ventriculography in sudden blindness was further discussed by Keane,<sup>[4]</sup> who demonstrated bilateral retinal vascular occlusion after ventriculography in a patient with papilledema. Keane's case is the only case with a fair outcome in the literature. The patient's visual acuity improved to 20/40 in both eyes two years later.

Early reports on the occurrence of post-craniotomy visual loss proposed sudden relief of increased intracranial pressure and vascular occlusion as possible factors exacerbating vision due to preoperative papilledema.

Beck and Greenberg<sup>[7]</sup> coined the term post-decompressive optic neuropathy in 1985. In their series of five patients, bilateral papilledema was present before surgery in all cases and four had pre-operative decreased visual acuity. All patients

awoke with visual loss following craniotomies and the pattern of visual field loss was in a nerve fiber bundle distribution, which was typical for optic disc damage. They concluded that papilledema is a prerequisite for the development of such a complication and hypothesized hypoperfusion to the prelaminar portion of the optic nerves as the most likely pathogenesis. Hypoperfusion might occur due to a release of vasoregulatory factors after lowering ICP and the resultant decreased perfusion to the optic nerves. To back up their theory, Beck and Greenberg<sup>[7]</sup> referred to the study of Hayreh and Edwards,<sup>[3]</sup> which had previously demonstrated a sudden drop in ophthalmic artery pressure after sudden lowering of intracranial pressure. Although Beck and Greenberg related their finding to the possible intra-operative optic disc damage, the certainty of this relation remains questionable as visual fields were examined preoperatively in only one of their patients.



**Figure 3:** Possible pre-operative (pre-op) and intra-operative (intra-op) factors contributing in the pathophysiology of post-craniotomy optic neuropathy in the supine position

Bostrom *et al.*<sup>[8]</sup> also proposed the same mechanism for the unexpected blindness following their removal of an intraventricular tumor in a case of juvenile xanthogranuloma (JXG).

Several other authors have reported sudden monocular visual loss due to the external pressure on the eyes in the supine position.<sup>[9,10,13]</sup> Choudhari *et al.*,<sup>[13]</sup> reported a patient who

awoke blind following a 3-hour long pterional craniotomy for an AcomA aneurysm. The authors proposed the ongoing external pressure on the ipsilateral eye as the main mechanism for post-operative sudden visual loss. Maier *et al.*<sup>[9]</sup> also emphasized on the role of intra-operative external pressure on the eyes and believed high intraorbital pressure, low arterial blood pressure, and shallow orbits were the three main risk factors for this disastrous complication. In this three reports,

**Table 1: Possible pre-operative and intra-operative factors contributing in the pathophysiology of post-craniotomy optic neuropathy in the supine position**

Year	Sex	Age	Lesion	Craniotomy/surgery	Pre-op visual status	Post-op visual status	Course	Intervention	Follow-up (months)	Associated conditions
1985 <sup>[7]</sup>	M	20	Astrocytoma	Lt Frontal/ Biopsy	Bilateral papilledema blurred vision	ODs: Pale RE: 20/800 LE: 20/400 VF: Marked Loss	Sudden	No	6 m	Intra-op hypotension
	M	15	Meningioma	Rt Fronto-Parietal	Bilateral papilledema RE: 20/60 LE: N/A	ODs: Pale RE: 20/200 LE: 2m FC VF: Marked Loss	Sudden	No	5 m	
	M	22	Astrocytoma	Rt Frontal/ Subtotal Resection	Bilateral papilledema	ODs: Pale RE: 20/20 LE: 20/25 VF: Bilateral Loss	Sudden	No	6 m	
	M	9	Astrocytoma	VP Shunt	Bilateral papilledema and OD Atrophy RE: 20/50 LE: 20/100	ODs: Pale RE: 20/400 LE: 20/800 VF: Bilateral Loss	Sudden	No	12 m	Hydro-cephalus
	F	38	Astrocytoma	Rt Fronto-temporal/ subtotal resection	Bilateral papilledema blurred vision for distance	ODs: Pale RE: 20/25 LE: 20/40 VF: Bilateral Loss	Sudden	No	5 m	
2000 <sup>[8]</sup>	M	4	JXG	?	ODs: Bilateral Atrophy ↓VA/↓VF	Light perception	Sudden	No	?	Rapid drop in ICP
2009 <sup>[10]</sup>	F	38	?	?	?	Immediate: NI appearing Disc and Retina ODs: Atrophy in 2 months VA: HM	Sudden (LE)	Dexamethasone (IV)	2 m	BIS over forehead >8 h
2007 <sup>[13]</sup>	M	47	AcomA Aneurysm	Rt Pterional	NI	Immediate: NI Appearing Disc and Retina ODs: Atrophy in 8w VA: FC	Sudden (RE)			Prolonged external pressure on Rt eye >3 h
2007 <sup>[9]</sup>	M	24	Post Traumatic Rinorrhea	Frontal Basal Skull Approach	NI	Immediate: VA: HM in both eyes Fundoscopy: CRAO ODs: Atrophy in 4 m	Sudden	Diamox Heparin	4 m	Brief intra-op asystole due to ↑ICP direct pressure on eyes >5 h
This case	F	36	Olfactory Groove Meningioma	Bifrontal craniotomy	Bilateral papilledema mild optic atrophy	Immediate: VA: NLP in Both Eyes ODs: Atrophy 2 m)	Sudden	Serial LP	52 m	

BIS – Bispectral index; CRAO – Central retinal artery occlusion; FC – Finger count; HM – Hand motion; ICP – Intracranial pressure; Intra-op – Intra-operative; IV – Intravenous; JXG – Juvenile xanthogranuloma; LE – Left eye; LP – Lumbar puncture; Lt – Left; NI – Normal; NLP – No light perception; OD – Optic disc; Pre-op – Pre-operative; Post-op – Post-operative; RE – Right eye; Rt – Right; VA – Visual acuity; VF – Visual field; VP – Ventriculoperitoneal



as well as Keane's,<sup>[4]</sup> orbital infarction syndrome has been considered as the cause of sudden blindness. Due to the collaterals between the ophthalmic and external carotid artery, the site of arterial occlusion should be the terminal branches of the ophthalmic artery, primarily the central retinal artery, and short posterior ciliary arteries.

Although several theories have been emerged from these few reports on the possible pathophysiology of post-craniotomy sudden blindness in the supine position, we believe a multifactorial pathophysiology should be involved [Figure 3]. Almost all cases suffered from pre-operative decline in the visual status or pailledema. Increased ICP due to a brain tumor, previous severe head injury or an aneurysm rupture, etc., decreases perfusion to the terminal branches of the ophthalmic artery. The previously hypoperfused optic disc might become ischemic after the abrupt decline in blood pressure due to excessive bleeding from the tumor or induced intra-operative hypotension. This might cause a further decrease in retinal perfusion and lead to the development of an ischemic optic neuropathy (ION). Moreover, sudden decreased ICP may altar vasoregulation in the ophthalmic arteries, as well as other cerebral arteries and cause vasospasm. Prolonged induced vasospasm probably becomes irreversible in previously compromised terminal branches of the ophthalmic arteries, however, autoregulation compensates for vasospasm in other regions of the cerebral vasculature. Additionally, increased intra-orbital pressure due to an external pressure, which has been discussed by some authors, might decrease orbital venous drainage and worsens the hypoperfusion status. Therefore, a combination of vascular compromise, altered vasoregulation and increased intraorbital pressure might contribute to the development of post-craniotomy optic neuropathy. This should be a posterior ischemic optic neuropathy (PION) because in most cases, optic discs have been normal despite sudden visual loss and optic disc atrophy has developed over weeks or months. Figure 3 summarizes the possible pathophysiology.

All the therapeutic methods have failed to improve the patients' visual outcome [Table 1]. For our patient, a combination therapy including high dose acetazolamide (to improve flow to the optic nerve head and retina by lowering ICP) and methylprednisolone (controversial) and serial LP (to decrease possible optic nerve entrapment) were all unsuccessful. Therefore, we suggest preventive methods to be applied to high-risk craniotomies. These may include gradual lowering of ICP (e.g., piecemeal resection of large tumors when possible), careful monitoring of BP and VEP during surgery, maintaining blood pressure at normotensive status (not the preferred hypotensive status) and frequent eye checks to avoid external pressure on the eyes. We suggest using protective eye shields in all frontal craniotomies. Simple eye patches should be avoided. These may prevent excessive pressure on

the eyes by the surgeon's hand, myocutaneous flap, or even monitoring devices.

Considering the age of the patients (range: 4-47 y/o), we do not think atherosclerosis was a risk factor. Likewise, because all patients awoke with blindness, the role of exacerbated postoperative vasogenic edema and compressive optic neuropathy should be insignificant.

From a medico-legal standpoint, we believe the case of post-craniotomy optic neuropathy in the supine position deserves a dual awareness by both the neurosurgical community and the patients. First, we should bear in mind the possibility of such a disappointing complication for all high-risk patients operated on a seemingly uncomplicated session. Second, high-risk patients and their families need to be warned of its possibility along with other complications.

## Conclusion

Post-craniotomy sudden visual loss is a shocking complication to any neurosurgeon. Most neurosurgeons are unaware of its existence and it is probably underestimated in the literature. The prognosis is dismal and it is mostly due to the prolonged intra-operative vascular insufficiency of the ophthalmic arteries.

Possible risk factors are pre-operative decreased VA or VF, pailledema or optic atrophy. A thorough ophthalmological exam and consultation is advised for these patients.

Lack of controlled studies and animal models, ambiguous pathophysiology and risk factors limit a definite conclusion. Further studies should be directed at comparing high and low risk patients in case control studies regarding the development of post-craniotomy optic neuropathy. Autopsy findings might also contribute to the understanding of the pathophysiology.

Finally, this complication should be discussed with high-risk patients and their families preoperatively.

## References

- Alexandrakis G, Lam BL. Bilateral posterior ischemic optic neuropathy after spine surgery. *Am J Ophthalmol* 1999;127:354-5.
- Myers MA, Hamilton SR, Bogosian AJ, Smith CH, Wagner TA. Visual loss as a complication of spine surgery. A review of 37 cases. *Spine (Phila Pa 1976)* 1997;22:1325-9.
- Hayreh SS, Edwards J. Ophthalmic arterial and venous pressures. Effects of acute intracranial hypertension. *Br J Ophthalmol* 1971;55:649-63.
- Keane JR. Sudden blindness after ventriculography. Bilateral retinal vascular occlusion superimposed on papilledema. *Am J Ophthalmol* 1974;78:275-8.
- Obenchain T, Crandall PH, Hepler RS. Blindness following relief of increased intracranial pressure. A sequel to severe papilledema. *Bull Los Angeles Neurol Soc* 1970;35:147-52.
- Rinaldi I, Botton JE, Troland CE. Cortical visual disturbances following ventriculography and/or ventricular decompression. *J Neurosurg* 1962;19:568-76.

7. Beck RW, Greenberg S. Post-decompression optic neuropathy. *J Neurosurg* 1985;63:196-9.
8. Boström J, Janssen G, Messing-Jünger M, Felsberg JU, Neuen-Jacob E, Engelbrecht V, *et al.* Multiple intracranial juvenile xanthogranuloma. *J Neurosurg* 2000;93:335-41.
9. Maier P, Feltgen N, Lagreze WA. Bilateral orbital infarction syndrome after bifrontal craniotomy. *Arch Ophthalmol* 2007;125:422-3.
10. Yamashita S, Takahashi H, Tanaka M. Bispectral index sensor as a possible cause of postoperative visual loss after frontal craniotomy. *Br J Anaesth* 2009;103:134.
11. Holmes G. The prognosis in papilloedema. *Br J Ophthalmol* 1973;21:337-42.
12. Sachs E. Diagnosis and treatment of brain tumors and care of the neurosurgical patient, 2<sup>nd</sup> ed. St Louis: CV Mosby; 1949.
13. Choudhari KA, Pherwani AA. Sudden visual loss due to posterior ischemic optic neuropathy following craniotomy for a ruptured intracranial aneurysm. *Neurol India* 2007;55:163-5.

**How to cite this article:** Vahedi P, Meshkini A, Mohajernezhadfar Z, Tubbs RS. Post-craniotomy blindness in the supine position: Unlikely or ignored?. *Asian J Neurosurg* 2013;8:36-41.

**Source of Support:** Nil, **Conflict of Interest:** None declared.