

CASE REPORT

Neglected primary Ewing's sarcoma of ethmoid presenting as surgical emergency

Dinesh Shukla, Vinjamuri Srinivas Rao, Alugolu Rajesh, Aniruddh Kumar Purohit

Department of Neurosurgery, Nizam's Institute of Medical Sciences, Punjagutta, Hyderabad, India

ABSTRACT

We present a male child with primary Ewing's sarcoma arising from ethmoid sinuses with intradural and extracranial extension (bilateral nasal cavities, orbits, and maxillary sinuses). This is a rare condition. He presented with recurrent episodes of epistaxis for 2 years, sudden onset rapidly progressive bilateral proptosis, with painful restriction of extraocular movements, and decreased visual acuity for 4 days. Sudden complete loss of vision following admission demanded emergency tumor decompression.

Key words: Anterior cranial fossa, ethmoid sinus, Ewing's sarcoma, tumor

Introduction

Ewing's sarcoma is an uncommon primary malignant bone tumor usually involving long bones in children and young adults. It represents only 2% of all neoplasms below the age of 15 year.^[1] Primary Ewing's sarcoma arising from in head and neck region is rare, representing 1-4% of all cases.^[2] We herein report a rare case of primary Ewing's sarcoma originating from ethmoid sinus extending into anterior cranial fossa, bilateral nasal cavities, orbits, and maxillary sinuses.

Case Report

A 10-year-old male child was brought by his parents with history of recurrent epistaxis for 2 years for which endoscopic biopsy was performed elsewhere. The biopsy was inconclusive. His epistaxis subsided but parents noted gradual widening of nasal bridge, proptosis, and decrease in the vision in both eyes. A week prior to admission he had another bout of epistaxis.

Examination revealed bilateral severe proptosis with conjunctival chemosis and complete ophthalmoplegia in

left and partial in right eye [Figure 1]. His visual acuity was counting fingers at a distance of 2 metres in right eye and 1 metre in the left eye. Nasal bridge was widened with pinkish tumor visible through the anterior nares. Rest of examination was unremarkable.

CT scan revealed a well-defined hyperdense lesion $8.2 \times 8.6 \times 9.2 \text{ cm}^3$ in basifrontal region extending through the ethmoid sinuses into bilateral nasal cavities, orbits, and maxillary sinuses and eroding the bone. It was enhancing homogeneously on contrast [Figure 2].

Patient had sudden onset, complete visual loss shortly after admission and hence was taken up for emergency surgical decompression. He was operated by transcranial-transnasal approach and greyish white, moderately vascular predominantly extradural tumor was noted in basifrontal region which was encroaching into bilateral ethmoid sinuses, nasal cavities, orbits, maxillary sinuses up to nasopharynx, and extending posteriorly up to lesser wing of sphenoid with erosion of adjacent bone. Dura was involved by the tumor and only a small part of tumor was extending intradurally. Bilateral external carotid control was taken in the neck. A near total excision was achieved followed by repair of anterior cranial fossa floor in three layers using fascia lata, split calvarial bone flap, and pericranium. Postoperatively, proptosis decreased dramatically [Figure 3] and visual acuity improved to finger counting at 4 metres in right eye with perception of light in left eye.

Microscopic examination revealed the tissue composed of cellular lesion; cells are round to polygonal with scant to moderate amount of cytoplasm and very frequent mitosis with small foci of necrosis. IHC with LCA, Tdt, CK was negative and CD99 positive in tumor cells suggestive of Ewing's sarcoma.

Access this article online	
Quick Response Code:	Website: www.asianjns.org
	DOI: 10.4103/1793-5482.110281

Address for correspondence:

Dr. Alugolu Rajesh, Department of Neurosurgery, Nizam's Institute of Medical Sciences, Punjagutta, Hyderabad - 500 082, India.
E-mail: drarajesh1306@gmail.com

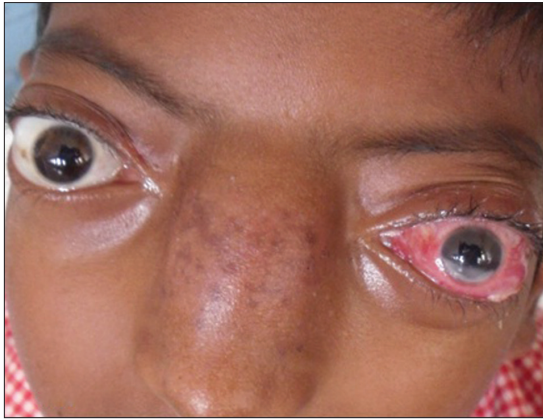

Figure 1: Preop status showing bilateral proptosis (left > right) with widened nasal bridge. Extensive conjunctival chemosis on the left side with exposure keratitis



Figure 3: Postop status with resolved proptosis and mild decrease in the width of nasal bridge

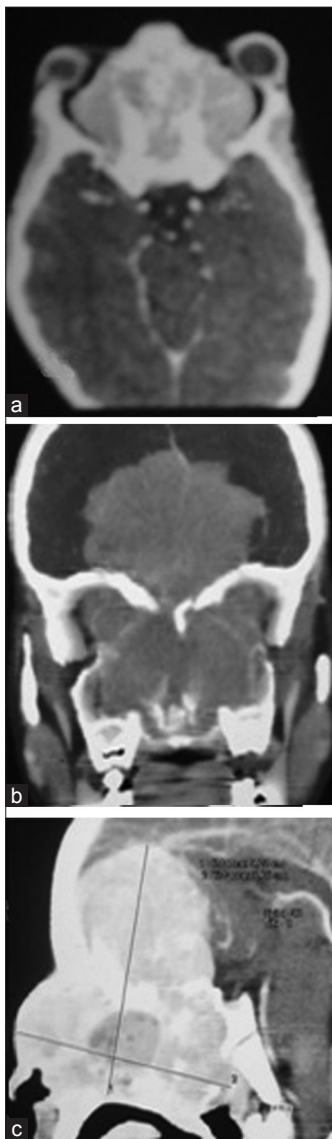

Figure 2: (a) Axial, (b) sagittal and (c) coronal sections of CT brain contrast study showing well enhancing lesion in basifrontal region extending through the ethmoid sinuses into bilateral nasal cavities, orbits, and maxillary sinuses

He was subjected to chemo-radiotherapy subsequently. Following four cycles of chemotherapy with vincristine (1 mg), doxorubicin (70 mg), cyclophosphamide (1100 mg) intervened with ifosfomide (D1-D4, 1.7 g), and etoposide (D1-D4, 90 mg). After four cycles of chemotherapy, intensity modulated radiotherapy on linear accelerator (Clinac-iX-3665), 1.8 Greys per fraction, 31 fractions (total dose- 55.8 Greys) was given. He was continued on chemotherapy (described above) for 10 cycles. He is planned to get chemotherapy for two more cycles. Patient was doing well at follow up of 11 months and there was no apparent clinical or radiological [Figure 4] evidence of local recurrence or systemic metastasis (No hot spot on bone scan).

Discussion

Ewing's sarcoma was first described in 1921 by James Ewing.^[3] It is a malignant bone tumor in children peaking around 15 years of age and usually involving long bones (47%) followed by pelvis (29%) and ribs (16%).^[4] Involvement of skull is noted in less than 4% of cases.^[2,5] The commonest site of primary cranial Ewing's sarcoma is temporal bone^[6,7] followed by frontal, parietal and occipital bones. Sphenoid^[8,9] and ethmoid bones are involved less commonly. Primary cranial Ewing's sarcoma is usually extra dural, but dural invasion has also been documented.^[10]

Pain, swelling, and compromised function of the affected part is the most common presenting feature of peripherally located Ewings tumor^[11] whereas headache is the most common symptom and papilledema is the most common sign in patients with cranial involvement.^[1] Duration of symptoms before presentation ranges from 2 weeks to 2 years.^[12] In present case, as the lesion was arising from ethmoid bone and involving mainly the anterior skull base with extension into adjacent regions, the chief presenting complaint was due to mass effect over surrounding structures in the form of proptosis, painful ophthalmoplegia, decreased visual acuity

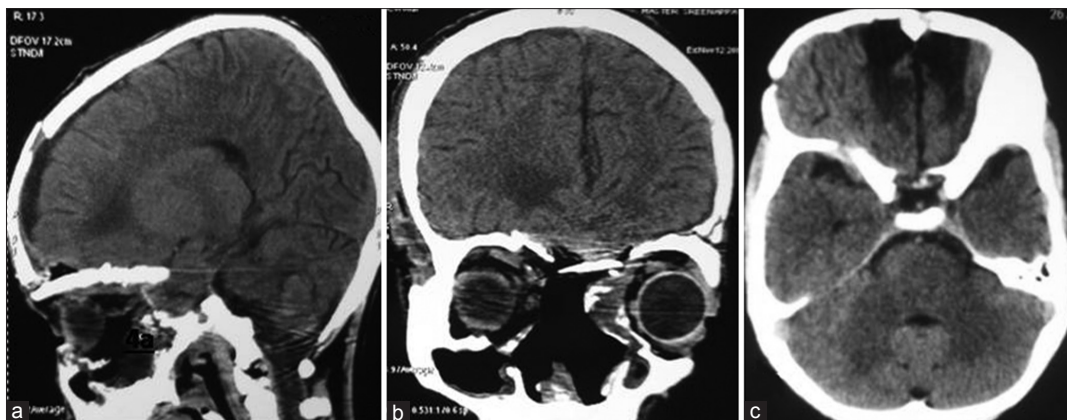


Figure 4: Postop CT scan (a) sagittal and (b) coronal sections showing no significant residual tumor. (c) Axial sections at the level of greater wing of sphenoid showing minimal edema of the bilateral basifrontal regions

along with broadening of the nasal bridge, and epistaxis. Sudden complete loss of vision prompted emergency surgical decompression of the lesion as has also been documented in literature.^[13]

In the skull, these tumors are present as permeative, destructive lesions associated with soft tissue components, and no calcification, reflecting the aggressive nature of the tumor. The classic radiologic features of Ewing's sarcoma such as "Moth-eaten" permeative bony destruction, rarefaction, and cortical erosion may be present but typical onion peel appearance may not be seen in cranial tumors.^[14] In our case, CT scan showed a large extra axial mass arising from and destroying the ethmoids and anterior cranial base with extension into orbits (b/l), nasal cavity upto the palate and bilateral maxillary sinuses.

The differential diagnosis of lesions in the above mentioned area include esthesioneuroblastoma, sinonasal malignancies, neuroendocrine carcinoma, chondrosarcoma, other sinonasal malignancies or inflammatory conditions such as infected granuloma.

Ewing's sarcoma is a radiosensitive tumor. Multimodality therapy consisting of an initial biopsy, aggressive combination of surgery, chemotherapy and localized radiotherapy is the treatment of choice and may result in long-term survival.^[2] The prognosis of Ewing's sarcoma of the skull is relatively good as compared to primary bony site in long bones and pelvis as there is little tendency for metastasis.^[6,15]

The case is reported because of the rarity of Ewing's sarcoma to arise from ethmoid sinus and presenting as surgical emergency along with important role that multimodality treatment in the form of aggressive surgical excision followed by chemoradiotherapy plays in achieving a fairly good outcome.

References

1. Mehta Y, Hendrickson FR. CNS involvement in Ewing's sarcoma. *Cancer* 1974;33:859-62.
2. Allam A, El-Husseiny G, Khafaga Y, Kandil A, Gray A, Ezzat A, *et al.* Ewing's Sarcoma of the Head and Neck: A Retrospective Analysis of 24 Cases. *Sarcoma* 1999;3:11-5.
3. Ewing J. Diffuse endothelioma of bone. *Proc N Y Pathol Soc* 1921;21:17-24.
4. Falk S, Alpert M. The clinical and roentgen aspects of Ewing's sarcoma. *Am J Med Sci* 1965;250:492-508.
5. Bhansali SK, Desai PB. Ewing's sarcoma: Observation on 107 cases. *J Bone Joint Surg Am* 1963;45:541-53.
6. Desai KI, Nadkarni TD, Goel A, Muzumdar DP, Naresh KN, Nair CN. Primary Ewing's sarcoma of the cranium. *Neurosurgery* 2000;46:62-8.
7. Boumdin H, el Quessar A, Chakir N, el Hassani MR, Jiddane M. Primary Ewing's sarcoma of the cranial vault. Report of 2 cases. *J Neuroradiol* 2001;28:200-4.
8. Singh P, Jain M, Singh DP, Kalra N, Khandelwal N, Suri S. MR findings of primary Ewing's sarcoma of greater wing of sphenoid. *Australas Radiol* 2002;46:409-11.
9. Sharma RR, Netalkar A, Lad SD. Primary Ewing's sarcoma of the greater wing of the sphenoid bone. *Br J Neurosurg* 2000;14:53-6.
10. Li WY, Brock P, Saunders DE. Imaging characteristics of primary cranial Ewing's sarcoma. *Pediatr Radiol* 2005;35:612-8.
11. Johnson R, Humphreys SR. Past failures and future possibilities in Ewing's sarcoma. *Experimental and preliminary clinical results.* *Cancer* 1969;23:161-6.
12. Mishra HB, Haran RP, Joseph T, Chandi SM. Primary Ewing's sarcoma of the skull. A report of two cases. *Br J Neurosurg* 1993;7:683-6.
13. Tourmut P, Turjman F, Laharotte JC, Froment JC, Gharbi S, Duquesnel J. Primary Ewing's sarcoma of the skull presenting as an acute surgical emergency. *Childs Nerv Syst* 1994;10:193-4.
14. Salunke PS, Gupta K, Malik V, Kumar N, Henke LE, Cai C, *et al.* Primary Ewing's sarcoma of cranial bones: Analysis of ten patients. *Acta Neurochir (Wien)* 2011;153:1477-85.
15. Hadfield MG, Luo VY, Williams RL, Ward JD, Russo CP. Ewing's sarcoma of the skull in an infant. A case report and review. *Pediatr Neurosurg* 1996;25:100-4.

How to cite this article: Shukla D, Rao VS, Rajesh A, Purohit AK. Neglected primary Ewing's sarcoma of ethmoid presenting as surgical emergency. *Asian J Neurosurg* 2013;8:51-3.

Source of Support: Nil, **Conflict of Interest:** None declared.