

Chooramani technique: A novel method of omental transposition in traumatic spinal cord injury

Gopal S. Chooramani, Girish Kumar Singh¹, Rajeshwar Nath Srivastava¹, Pramod Kumar Jaiswal¹, Chhitij Srivastava²

Departments of Nuclear Magnetic Resonance Imaging, SGPGI, ¹Orthopedics, ²Neurosurgery, CSM Medical University, Lucknow, India

ABSTRACT

Background: Spinal cord injury often results in significant catastrophic disability. Placement of the intact omentum upon a recently traumatized spinal cord was found to be effective. It represents a very suitable organ for revascularization of the ischemic nervous tissue, due to its abundance in blood and lymph vessels and its capability to adhere to the surface of the lesion, with capillary overgrowing in 4-6 h. The traditional method of omentum transposition is a hectic and time-consuming two-stage procedure in which position is changed twice. The major disadvantage of this two-staged procedure is that it takes longer operative time, and there is high risk of infection due to change of position with an open wound. So there is a need for modifications so that the procedure can be made easier and complications can be avoided.

Objective: To avoid the complications and to make the procedure easier, a single-staged procedure called 'chooramani technique' for omental transposition in spinal cord injury is proposed.

Materials and Methods: The study was conducted on 16 patients of post-traumatic thoraco-lumbar spinal cord injury with paraplegia.

Results: Complications like wound infection, incisional hernia, and CSF leak were avoided. Operative time reduced to approximately half.

Conclusion: This modification of technique is relatively easy and can be adopted for patients undergoing omental transposition for spinal cord injury.

Key words: Omental transposition, spinal cord injury, paraplegia

Introduction

Spinal cord injury often results in significant catastrophic disability. Research in the field of recovery and regeneration of spinal cord has given a ray of hope to both doctors and patients that all spinal cord injuries will eventually be repairable.

After the primary spinal cord injury there is complex secondary injury cascade that leads to death of potentially viable axons.

The key principles in spinal cord repair is to protect surviving nerve cells from further damage, replacing damaged nerve cells, stimulating the re-growth of axons and targeting their connections appropriately, and retraining the neural circuits to restore body functions.

The omentum is a highly vascular, fatty tissue. Although the omentum has been viewed as an inert tissue without any significant biological function, scientists are now discovering that it is a physiologically dynamic tissue.

The placement of the intact omentum upon a recently traumatized spinal cord was found to be effective. It represents a very suitable organ for revascularization of the ischemic nervous tissue, due to its abundance in blood and lymph vessels and its capability to adhere to the surface of the lesion, with capillary overgrowing in 4-6 h.^[1]

Materials and Methods

The study was conducted on the patients of thoraco-lumbar spine injuries with complete paraplegia admitted to our institution. Ethical clearance was taken from the institutional

Access this article online	
Quick Response Code:	Website: www.asianjns.org
	DOI: 10.4103/1793-5482.125661

Address for correspondence:

Dr. Chhitij Srivastava, Department of Neurosurgery, CSM Medical University (formerly KGMU), Lucknow, Uttar Pradesh, India.
E-mail: drchhitij@yahoo.co.in

ethical committee. Informed consent was taken from the patient and their attendants.

Apart from routine investigations for fitness for surgery and anesthesia, investigations like X-rays in AP and Lat views and MRI with screening of full spine was done as a preoperative protocol.

All the patients were subjected to surgery in the form of decompression, posterior instrumentation (titanium pedicle screw and rod devices) along with omentum transposition.

Sitting allowed with braces from the next day of surgery or when pain of surgery and effect of anesthesia permits patient to get up from bed.

Patients were subjected to active assisted/gentle passive physiotherapy. Patients' attendants were trained about the rehabilitation protocol.

Surgical technique

The traditional method of omentum transposition is a hectic and time-consuming two-stage procedure in which position is changed twice. In the first stage, the patient is placed in a supine position and underwent a laprotomy procedure for omental harvesting and lengthening. In the second stage, a subcutaneous tunnel is made and patient has to be rolled in the prone position for the fixation of spine, laminectomy, and suturing the omentum to dural edges.

The major disadvantage of this two-staged procedure is that it takes longer operative time, and there is high risk of infection due to change of position with open wound and more chances of incisional hernia.

To avoid these complications and to make the procedure easier, we propose a single-staged procedure called 'chooramani technique' for omental transposition in spinal cord injury. Before performing the procedure on live subjects, it was first tried on cadavers in a dissection hall. The patient is placed in a prone position. Painting and draping is started from mid-thoracic spine (site of injury) extending to the left lateral abdominal area, reaching up to the umbilicus.

In prone position the area of spinal cord damage (thoracic or thoraco lumbar) is decompressed and fixed by laminectomy and pedicle screw fixation. Spinal wound is covered by wet cottonoid. For harvesting, the omentum operating table is slightly tilted towards the right and the left lateral abdominal wall is retracted by the assistant standing on the right-hand side of the patient. A transverse incision is given starting from the tip of the twelfth rib to the lateral rectus sheath [Figure 1]. Oblique and transversus muscles are cut in single layer and the peritoneum is opened by small 5 cm incision [Figure 2]. Dry packing gauze is inserted into the peritoneal opening and while retrieving it omentum comes out through the opening

along with the gauze piece. Omentum is gently pulled till its attachment to the transverse colon is visualized. After inspecting the vascular arcade of the omentum, it is freed from its attachment of the transverse colon. A long vascular pedicle is created in this way [Figure 3]. A tunnel is made beneath the abdominal muscles between the spinal and abdominal wound and omentum is taken out through the spinal wound. To facilitate the passage of omental pedicle, one- or two-surface cut on the way may be needed.

The dura is opened and arachnoid is dissected to inspect the spinal cord [Figure 4]. Pedicled omentum is kept over the pia of the damaged spinal cord and omentum stitched to dural margins with interrupted sutures.

Result and Discussion

Pathophysiology of spinal cord injury

The initial trauma includes both traction, which pulls nerve cells apart, and compression, which damages nerves and blood vessels. This physical trauma sets off a cascade of biochemical and cellular events that kill neurons, strips axons of their myelin insulation and triggers an inflammatory immune system response.

Immediately after the trauma, the blood – brain barrier is broken leading to leaking of oedematous fluid into spinal cord tissue. As the oedema accumulates in the spinal cord, it swells up. There is further loss of blood supply when the pressure in the spinal canal rises. Because of differences in tissue composition, the impact is greater on the interior grey matter of the spinal cord than on the outlying white matter. The combination of leaking, swelling, and sluggish blood flow prevents the normal delivery of oxygen and nutrients to neurons causing many of them to die.

After the injury, an excessive release of neurotransmitters can cause additional damage by overexciting nerve cells. Glutamate, an excitatory neurotransmitter, is commonly used by nerve cells in the spinal cord to stimulate activity in neurons. When spinal cells are injured, neurons flood the area with glutamate which triggers a destructive process called excitotoxicity.

Immune cells, which normally circulate in the blood vessels, leak and invade the surrounding tissue to trigger an inflammatory response. This inflammation is characterized by fluid accumulation and the influx of immune cells and release of cytokines which exert an inhibitory influence on the activities of nerve cells.

All of these mechanisms of secondary damage - restricted blood flow, excitotoxicity, and inflammation - increase the area of damage in the injured spinal cord.

Once the secondary wave of damage ends, the spinal cord is

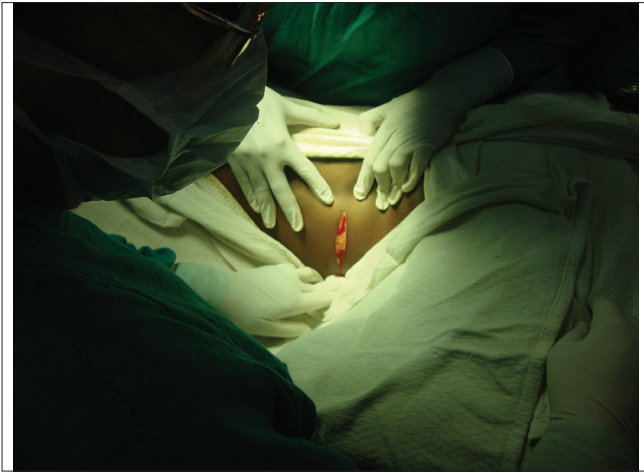

Figure 1: Incision starting at the tip of the 12th rib in the lateral abdominal wall

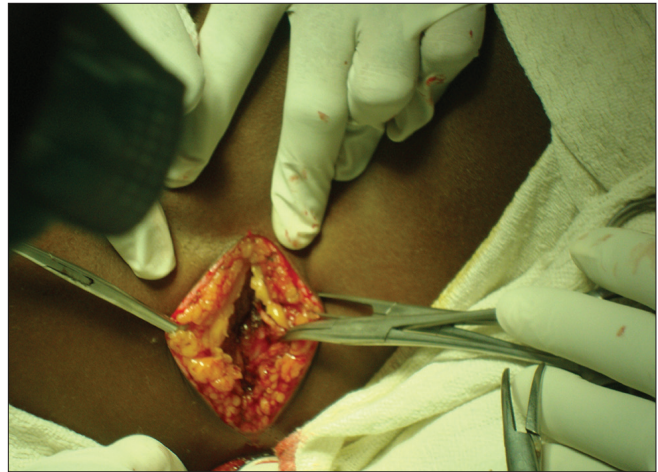


Figure 2: Opening the peritoneum

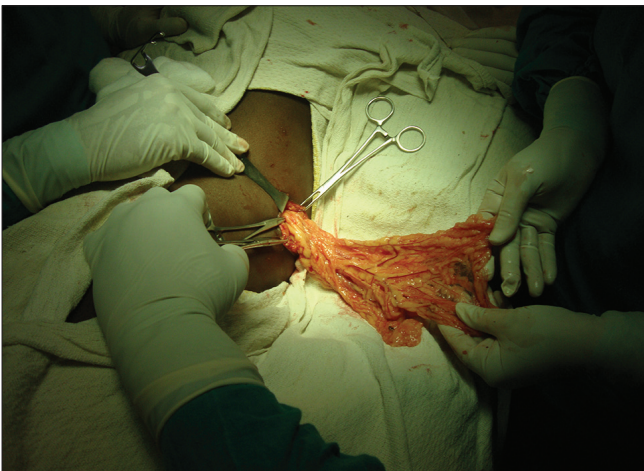

Figure 3: Omentum taken out through the wound

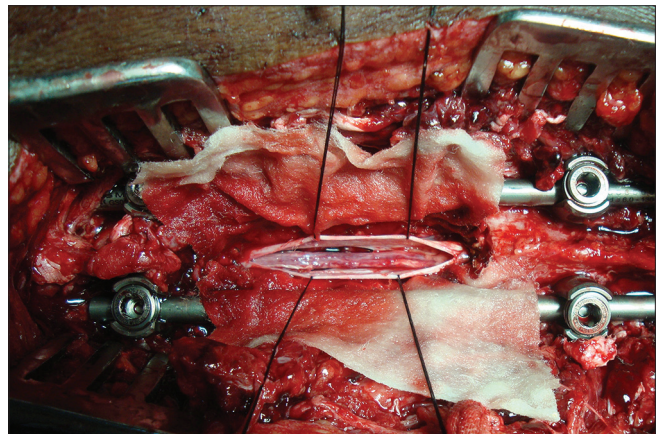


Figure 4: Dura opened exposing the traumatized spinal cord

left with areas of scar tissue and fluid-filled gaps, or cysts that axons cannot penetrate or bridge.

Omentomyelopexy

Omentum is a highly vascular organ with a rich source of angiogenic factors which promote the growth of blood vessels on organs over which it is placed. The lymphatic system of omentum helps in absorbing oedema fluids. Recent studies have proved that omentum also contain omnipotent stem cells that can differentiate in various cells types.

A transplanted greater omentum has been used in many disorders such as in lymphedema, management of chronic wound, myocardial infarction, stroke, and so on.

The use of omentum for spinal cord vascularization was first done in 1975 in a dog model.^[2] After killing the animal, extensive anastomosis was found between the blood vessels of omentum and dog.

Research in cats has also shown that the omentum can help

repair a damaged spinal cord. It was theorized that the beneficial effect of omental transposition was due to the establishment of a dynamic equilibrium between production of vasogenic oedema from the injured cord and its absorption through omental pathways. Removing vasogenic oedema at the omental/spinal cord interface is hypothesized to stabilize a rising tissue pressure within the cord during the acute phase of injury and at a later date to decrease scar formation at the injury site.^[3]

The omentum has the ability to produce blood vessels that make vascular connections to the pia mater of the normal spinal cord within 72 h of omental transposition.^[4]

It is also observed that vascularization occurs at an even faster rate when the omentum is applied to a traumatized spinal cord.^[3]

Division of the right or left gastroepiploic artery and the vasa recta along the greater curvature of the stomach with mobilization of the omentum from the transverse colon allows the development of a vascularized omental pedicle flap.

Anatomically its attachment and vascular arcade are in such a way that it can be lengthened and exteriorized to any long size for various extra abdominal procedures.^[5] Some surgeons use a substitute procedure, in which a free, unattached piece of omental tissue is surgically placed over the injured cord and connected to a surrounding vascular source (e.g., to the carotid artery and jugular vein). Dr Hernando Rafael in Mexico has mostly used this modified procedure to treat over 250 people with spinal cord injury. Although blood circulation is maintained, because the graft is separated from the omentum's lymphatic system, the tissue's ability to absorb fluid is eliminated.

Goldsmith pioneered this procedure for various central nervous system disorders. In 1984, he carried out the first surgery in a person with spinal cord injury. The procedure's acceptance has grown greatly in other parts of the world, such as in China where more than 3000 people with spinal cord injury have had omental surgery. Goldsmith and Rafael estimate that about 40 percent of their patients have regained some function, and Chinese surgeons have reported an even greater improvement rate.

We have operated 16 cases with our technique. Nine patients belongs to the age group 16-30 years, four patients were in the age group 31-45 years while three patients were in the age group 46-60 years. The reason for the maximum number of patients in the 16-30 year age group is due to the fact that this age group is more prone to trauma as it is more involved in outdoor activities. Males due to the same reason are more involved (male:female, 7:1). The most common mode of injury was the fall from height (9/16) as majority of

patients were from rural area. The total duration of procedure from skin incision to wound closure is 4 h. It includes spinal instrumentation and omental transposition. The post-period was uneventful in all the patients. There is not a single case of post-operative CSF leak or intestinal obstruction. One patient improved from ASIA A to D in 3-month follow-up while two patients improve to ASIA B.

Hence, it can be concluded that this single-stage procedure for omental transposition is technically feasible, relatively easy, and associated with minimal morbidity as compared to the two-staged procedure.

References

1. Ignjatovic M, Pervulov S, Cuk V, Kostic Z, Minic L. Early angiogenic capabilities of the transposed omental flap after omentomyeloplasty. *Acta Chir Jugosl* 2001;48:41-3.
2. Goldsmith HS, Duckett S, Chen WF. Spinal cord vascularisation by intact omentum. *Am J Surg* 1975;129:262-5.
3. Goldsmith HS, Steward E, Duckett S. Early application of pedicled omentum to the acutely traumatised spinal cord. *Paraplegia* 1985;23:100-12.
4. Levader B, Zwetnow NN. Bulk flow of C.S.F. through a lumbo-omental pedicle graft in the dog. *Acta Neurochirurgica* 1978;41:147-55.
5. Alagumuthu M, Das BB, Pattanayak SP, Rasananda M. The omentum: A unique organ of exceptional versatility. *Indian J Surg*. 2006;68:136-41.

How to cite this article: Chooramani GS, Singh GK, Srivastava RN, Jaiswal PK, Srivastava C. Chooramani technique: A novel method of omental transposition in traumatic spinal cord injury. *Asian J Neurosurg* 2013;8:179-82.

Source of Support: Nil, **Conflict of Interest:** None declared.