

CASE REPORT

Multiple intracranial abscesses: Heralding asymptomatic venous ASD

Praveen K. Gupta, Rehab Al Marzook¹, Leena Sulaibeekh²

Departments of Clinical Neurosciences, ¹Pediatrics, Salmania Medical Complex, ²Cardiology, MKCC, BDF Hospital, Manama, Kingdom of Bahrain

ABSTRACT

A case of multiple intracranial abscesses in an immune-competent young girl is reported. She had chicken pox. Two weeks later, she presented with multiple intracranial abscesses. No significant cardiac abnormality was detected on transthoracic echocardiogram (TTE). The condition was treated medically. However, one of the abscesses adjacent to the CSF pathways enlarged on treatment and caused obstructive hydrocephalus that required stereotactic aspiration. Gram stain showed gram positive cocci in chain. Pus was sterile on culture. She was treated with broad spectrum IV antibiotics based on Gram staining report for 6 weeks followed by another 8 weeks of oral antibiotics. She made good recovery and had been leading a normal life. The abscess capsules took 30 months to resolve completely on MRI. A repeat TTE done in the follow up showed enlarged right heart chambers with a suggestion of a venous ASD. A trans-esophageal echocardiogram (TEE) confirmed the presence of sinus venous ASD from the SVC side with mainly left to right shunt. There was also partial anomalous drainage of the pulmonary veins. The patient underwent correction of the defect and has been doing well.

Key words: Abscesses, asymptomatic, intracranial, multiple, venous atrial septal defect

Introduction

Intracranial abscess is an uncommon and potentially life threatening condition. Almost 30% are multiple. Exceptionally as many as 40 abscesses have been described in a case study.^[1] These are usually metastatic (Cyanotic heart diseases or pulmonary AVM) and less commonly due to contiguity (paranasal sinusitis or otitis media). They usually occur in immune-compromised patients and rarely in immune competent states. A case of multiple intracranial abscesses in an immune-competent young patient is reported. No cause was detected. The management required judicious surgical intervention of the abscess. In the follow-up, the patient was repeatedly investigated to detect the underlying cause which ultimately led to the detection of asymptomatic venous ASD. Unrelenting efforts are required to identify the underlying cause.

Case Report

A 13-year-old Saudi girl presented with 1 week history of headache, vomiting, and fever. She was treated by oral antibiotics with no relief. Two days prior to admission, she started talking incomprehensively, developed photophobia, and ataxia. Patient had chicken pox 4-weeks prior to admission that lasted 2 weeks. She also complained of chronic recurrent headache and fainting attacks with some abnormal movements, 4-5 times in the last 5 years. Each attack lasted a few minutes. She had exertional chest pain, dyspnoea, and palpitation on walking short distance. No treatment was sought for these conditions. There was no history of cyanotic or rheumatic heart disease or chronic infection. She had no exposure to chronic contagious diseases or animals.

On admission, HR was 105/min. Temperature and BP were normal and RR 32/min. No cyanosis, clubbing or lymphadenopathy. Paranasal sinuses were normal. No cardiac murmur. Other systemic examinations were normal. Neurologically, she was fully conscious and oriented with gross ataxia. Fundus showed early papilloedema. Muscle tone and power were normal in all the four limbs. There was no nystagmus or tremor. She could not walk without support.

Hematological tests revealed normal hemoglobin and polymorphonuclear pleocytosis with 80% neutrophils. RBC count was normal. ESR was 62 mm 1st h and CRP 27 mg/L.

Access this article online	
Quick Response Code:	Website: www.asianjns.org
	DOI: 10.4103/1793-5482.125677

Address for correspondence:

Dr. Praveen K. Gupta, Department of Clinical Neurosciences, 12, Bldg 695, Salmania Tower B, Road 1123, Block 311, Salmania, Manama, Kingdom of Bahrain. E-mail: pkguptaram@hotmail.com

Serum biochemistry showed raised GGT with reversed albumin globulin ratio. Blood culture was sterile. Tests for other infective and parasitic conditions were normal. Stool did not show any ova or cyst. PPD and HIV, both were negative. X-ray chest, ECG, and transthoracic echocardiogram (TTE) were normal. Transesophageal echocardiography (TEE) was refused by the patient. CT scan of the brain revealed almost 12 identical contrast enhancing ring lesions on both sides of the brain with uniform wall thickness and perilesional edema suggestive of multiple intracranial abscesses [Figure 1]. All the lesions were almost of same size indicating same age. Abdominal and pelvic ultrasounds were normal.

She was treated with Ceftriaxone, Vancomycin, Metronidazole, Mannitol, Dexamethasone, and Diphenyl hydantoin. She made significant improvement. Dexamethasone and Mannitol were withdrawn gradually once condition got stabilized. Two weeks after admission, the patient suddenly deteriorated, became bradycardic, lethargic, and had screaming attacks with labile mood and visual hallucinations. No cranial nerve or motor deficits were present. Mannitol and Dexamethasone were restarted. EEG showed abnormal slow waves with underlying multifocal epileptic discharges predominantly on right temporo-occipital region. Repeat CT scan of brain showed increase in the size of right thalamic lesion compressing the posterior III ventricle/aqueduct with obstructive triventricular dilatation and periventricular lucency. There were no changes in other lesions. She underwent stereotactic aspiration of the right thalamic lesion and 5 cc of brownish pus was aspirated. Gram stain

showed gram positive cocci in chains. However, the culture was sterile. Repeatedly, blood cultures and TTE were normal. Empirically, Gentamycin was added to the treatment regimen and the patient gradually started improving. Repeat CT scan of brain showed gradual reduction in the size of abscesses. She was given IV antibiotics for 6 weeks and another 8 weeks of oral antibiotics.

Resolution of lesions was very gradual and total clearance of all the lesion took 30 months on MRI. Antiepileptic drugs were continued. Repeat TTE, 36 months later showed enlarged right heart chambers with a suggestion of venous atrial septal defect (ASD) [Figure 2]. Pulmonary artery pressure (PAP) was 25-30 mmHg. TEE confirmed 1.8 cms sinus venous ASD from the SVC side [Figure 3] with anomalous drainage of right upper pulmonary vein. Right heart chambers were dilated. The shunt was left to right. She underwent correction of the defect and did well.

Discussion

Intracranial abscesses are uncommon and constitute 4% of all intracranial space occupying lesions in children.^[3] Multiple intracranial abscesses are seen in 10-36% of all intracranial abscesses.^[4,5] Sixty percent are seen in the first two decades of life^[6] and usually affect immune-compromised individuals. However, she was immune-competent when presented but that was preceded by Chicken pox, a well known immune-compromising state. They are usually embolic in nature and associated with cyanotic congenital heart disease (cCHD), constituting almost 30-50% of all

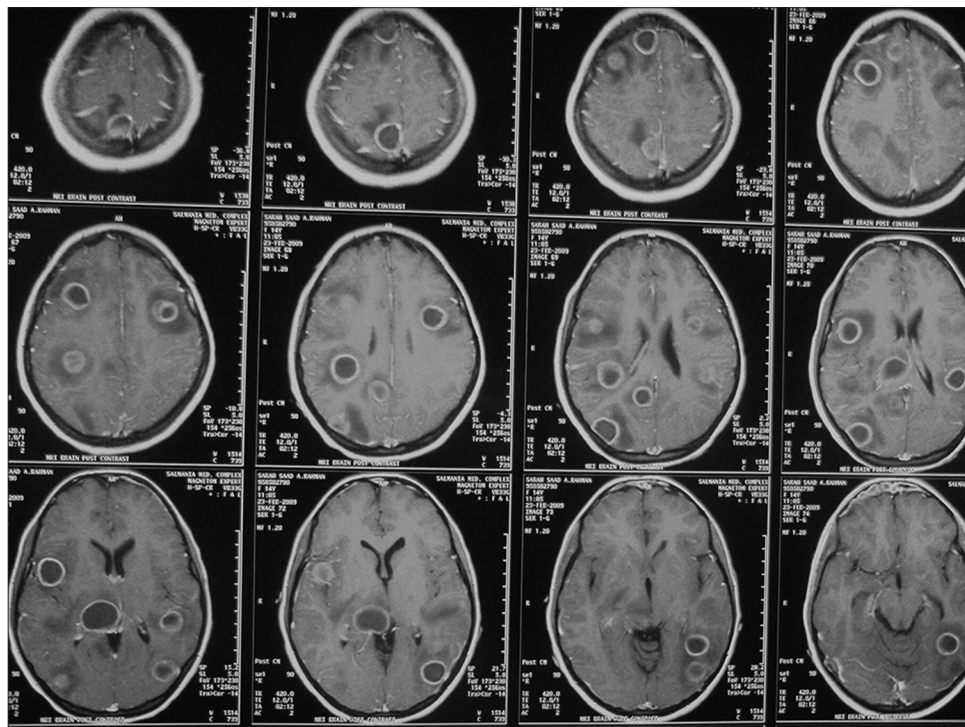


Figure 1: Multiple intracerebral abscesses

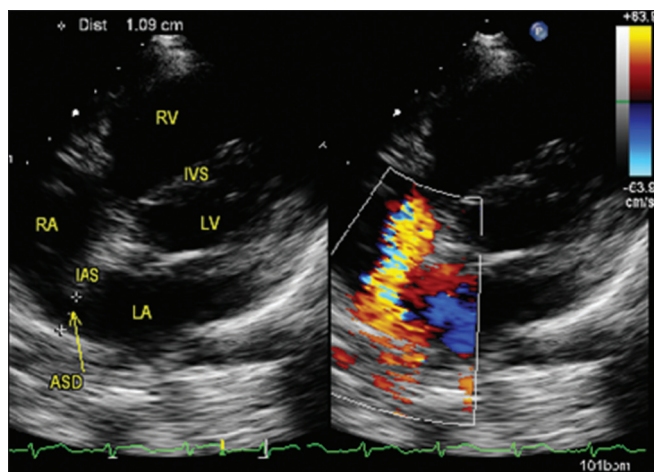


Figure 2: TTE showing the defect in the upper part of the septum

possible etiological factors.^[2,3,5] In contrast, only 5-18.7% of patients with CHD develop intracranial abscesses.^[7] This is due to right to left flow shunt in the heart, by-passing the pulmonary filter. Commonly, it involves right parietal lobe due to direct and maximal blood flow but any area may be affected. When abscesses are multiple, all the areas in the supratentorial compartment may get involved but posterior fossa still escapes as was noted in our case because the blood flow to the vertebral arteries has to wind round many curves and angulations. The abscesses are usually deep seated and thin walled, as was seen in the present case. Same size of the lesions indicated approximately same age and was possibly due to multiple emboli showering into the brain during immune-deficiency window. High index of suspicion is needed to diagnose them early and imaging of choice is CECT or MRI.

Microbiology usually reflects underlying risk factors. Gram positive cocci in chain – *streptococcus milleri*, *streptococcus viridans*, *microaerophilic staphylococcus aureus*, and *anaerobic streptococcus* are usually seen in cCHD.^[4,8,9] Pus does not grow any bacteria in almost 30%.^[6] This lead from the microbiology can be utilized to focus on investigations to identify the source of infection. In the present case, cardia was evaluated by TTE twice while under active treatment and both the time, the study did not show any abnormality. TEE was refused by the patient. Usually it takes 2 weeks for an intracranial abscess to mature but in immune-compromised state they mature slowly.^[6] No underlying disease or source of infection was identified and this may be so in almost 20% of intracranial abscesses.^[5] One of the causes of cerebral abscess in such unrecognized cases, labeled as cryptogenic brain abscesses is a missed or silent ASD.

A triad of cyanosis, polycythemia, and clubbing was first described by Reading to heighten clinical suspicion of brain abscess of embolic origin.^[10] However, in the present case no significant cCHD or any features of the clinical triad were

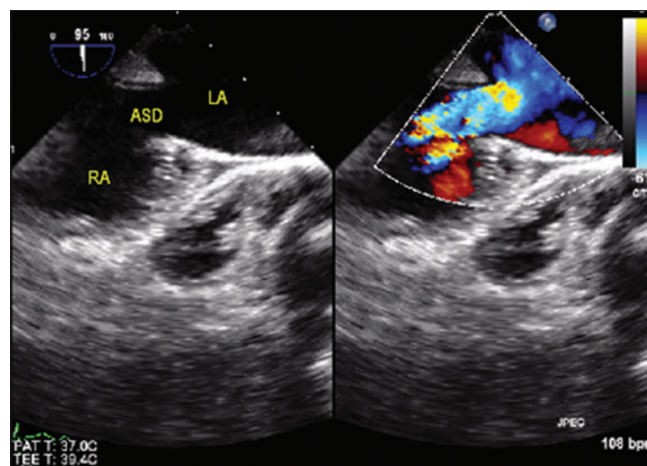


Figure 3: TEE bicaval view showing the sinus venosus ASD at SVC side

noted. The shunt was mainly left to right. However, the defect in the superior part of the atrial septum with the absence of the ridge of the right upper pulmonary vein might have resulted in the admixture of venous blood from superior vena cava with the left atrial blood. This admixture of blood can lead to the paradoxical embolus and intracerebral abscesses as was also reported by Abdulla R *et al.*^[11] The process was without any anatomical or physiological changes, i.e., right heart dilatation or rise in PAP at that stage. With progression of the condition, increasing blood volume was shunted into the right heart causing it to dilate without any rise in PAP. The shunt continued left to right and patient remaining acyanotic. At this stage, 3 years after her admission, the condition was identified by TTE and confirmed by TEE. Sinus venosus ASD, a rare form of congenital heart disease can be missed on TTE performed routinely in the evaluation of brain abscess. It is prudent to assume that the cause of cerebral abscess in cryptogenic brain abscesses is a missed or silent ASD unless proved otherwise. TEE is the most sensitive test to diagnose sinus venosus ASD^[12,13] and should be carried out in situations where no plausible pathology is identified.

Treatment of such an abscess requires meticulous and judicious approach.^[14] The largest lesion is tapped, abscess decompressed and pus sampled. The abscess adjacent to right thalamus in the present case enlarged and caused obstructive hydrocephalus. The abscess was decompressed and the obstruction released. The patient then made good recovery with antibiotics. Hyperbaric oxygen is another treatment modality that is proven effective and help recover faster.^[15,16] Pus did not grow any bacteria. Only Gram stain showed gram positive cocci in chains and based on this information, she was treated with broad spectrum antibiotics for almost 3 months and got cured. However, abscess wall took a long time to get resolved, almost 30 months on MRI. Such a combined approach results in high cure rate, higher than 90%.^[2] However, in spite of all advances, the morbidity and mortality remain high, 32% in one study due to failure to control intracranial and systemic

infection^[6] and is dependent on neurological status on initial presentation and socio-economic status of the patient.

Conclusion

Present study highlights the management complexity associated with multiple intracranial abscesses. In the absence of any definite etiology, a metastatic abscess should be considered due to a silent sinus venous ASD and anomalous pulmonary drainage. The patient was treated on empirical basis and made a good recovery.

References

- Ghafoor T, Amin MU. Multiple brain abscesses in a child with congenital cyanotic heart disease. *J Pak Med Assoc* 2006;56:603-5.
- Han S, Lim DJ, Chung YG, Cho TH, Lim SJ, Kim WJ, *et al.* The multiple brain abscesses associated with congenital pulmonary arteriovenous malformations: A case report. *J Korean Med Sci* 2002;17:407-11.
- Ciurea AV, Stoica F, Vasilescu G, Nuteanu L. Neurosurgical management of brain abscesses in children. *Childs Nerv Syst* 1999;15:309-17.
- Prusty GK. Brain abscesses in cyanotic heart disease. *Indian J Pediatr* 1993;60:43-51.
- Shahzad K, Hamid MH, Khan MA, Malik N, Maqbool S. Brain abscess in children. *J Coll Physicians Surg Pak* 2005;15:609-11.
- Sharma BS, Gupta SK, Khosla VK. Current concepts in the management of pyogenic brain abscess. *Neurol India* 2000;48:105-11.
- Pandian JD, Moosa NV, Cherian PJ, Radhakrishnan K. Brainstem abscess complicating tetralogy of Fallot successfully treated with antibiotics alone. *Neurol India* 2000;48:272-5.
- Rajnik M, Ottolini MG. Serious infections of the central nervous system: Encephalitis, meningitis, and brain abscess. *Adolesc Med* 2000;11:401-25.
- Seneviratne Rde S, Navasivayam P, Perera S, Wickremasinghe RS. Microbiology of cerebral abscess at the neurosurgical unit of the National Hospital of Sri Lanka. *Ceylon Med J* 2003;48:14-6.
- Reading B. Case of congenital telangiectasia of the lung, complicated by brain abscess. *Tex State J Med* 1932;28:462.
- Abdullah R, Baldauf M, Azam S, Hassanein M, Dhuper S. Multiple brain abscesses: An initial presentation in a child with an undiagnosed sinus venosus atrial septal defect. *Clin Neurol Neurosurg* 2007;109:620-3.
- Mehta RH, Helmcke F, Nanda NC, Pinheiro L, Samdarshi TE, Shah VK. Uses and limitations of transthoracic echocardiography in the assessment of atrial septal defect in the adult. *Am J Cardiol* 1991;67:288-94.
- Teo KS, Disney PJ, Dundon BK, Worthley MI, Brown MA, Sanders P, *et al.* Assessment of atrial septal defects in adults comparing cardiovascular magnetic resonance with transoesophageal echocardiography. *J Cardiovasc Magn Reson* 2010;12:44.
- Mamelak AN, Rosenblum ML, Obana WG, Mampalam TJ. Improved management of multiple brain abscess: A combined surgical and medical approach. *Neurosurgery* 1995;36:76-85.
- Kurschel S, Mohia A, Weigl V, Eder HG. Hyperbaric oxygen therapy for the treatment of brain abscess in children. *Childs Nerv Syst* 2006;22:38-42.
- Kutlay M, Colak A, Yildiz S, Demircan N, Akin ON. Stereotactic aspiration and antibiotic treatment combined with hyperbaric oxygen therapy in the management of bacterial brain abscesses. *Neurosurgery* 2008;62(Suppl 2):540-6.

How to cite this article: Gupta PK, Marzook RA, Sulaibeekh L. Multiple intracranial abscesses: Heralding asymptomatic venous ASD. *Asian J Neurosurg* 2013;8:202-5.
Source of Support: Nil, **Conflict of Interest:** None declared.