

Keyhole concept in cerebral aneurysm clipping and tumor removal by the supraciliary lateral supraorbital approach

Kentaro Mori

Department of Neurosurgery, National Defense Medical College, Saitama, Japan

ABSTRACT

The keyhole concept in neurosurgery is designed to minimize the craniotomy needed for the access route to deep intracranial pathologies. Such keyhole surgeries cause less trauma and can be less invasive than conventional surgical techniques. Among the various types of keyhole mini-craniotomy, supraorbital or lateral supraorbital mini-craniotomy is the standard and basic keyhole approaches. The lateral supraorbital keyhole provides adequate working space in the suprasellar to parasellar areas and planum sphenoidale area including the anterior communicating artery complex. Despite the development of neuro-endoscopic techniques and intra-operative assistant methods, the limited working angle to manipulate and observe deeply situated pathologies is a major disadvantage of the keyhole approaches. Neurosurgeons should understand that keyhole mini-craniotomy surgeries aim at “minimally invasive neurosurgery” but still carry the risks of malpractice unless we understand the advantages and disadvantages of these keyhole concepts and strategies.

Key words: Lateral supraorbital keyhole, neurosurgery, pterional keyhole, supraorbital keyhole

Introduction

The standard pterional approach was first established by Yaşargil, and various variations and skull base approaches have since been developed to treat various pathologies with safe neurosurgical procedures. The keyhole concept in neurosurgery was first advocated by Perneczky in Germany. The concept of keyhole neurosurgery is not to reduce the craniotomy size to as small as a “keyhole,” rather to make the “minimum craniotomy” required to access deep intracranial pathologies at the end of the route.^[1,2] Standard craniotomy forms a “funnel-shaped surgical corridor” to reach intracranial pathologies [Figure 1a]. In contrast, keyhole mini-craniotomy forms a “reverse funnel-shaped surgical corridor” that provides adequate working space through a small bone window but limits the working angle [Figure 1b]. The limited working angle hinders the observation and manipulation

of the targets from various directions. Therefore, to overcome such problems with keyhole neurosurgery, Perneczky introduced the endoscopy technique to observe and manipulate deeply situated lesions via mini-craniotomy.^[3]

The Perneczky method consists of an eyebrow (“supraciliary”) skin incision and supraorbital keyhole mini-craniotomy [Figure 2a].^[1,4,5] Although the supraorbital keyhole approach is the representative keyhole approach to treat various intracranial pathologies in the supra- and parasellar regions, other types of keyhole approaches can be used, such as the subtemporal, interhemispheric, and retromastoid keyhole approaches, to treat cerebral aneurysms according to location.^[6] Several other variations on the supraorbital keyhole approach via eyebrow incision have been described in more recent years.^[7-9] We have also advocated the lateral supraorbital keyhole approach [Figure 2b]^[9] to treat particular pathologies such as anterior communicating artery (A-com A) aneurysm from the more lateral direction than the Perneczky method, and the pterional keyhole approach^[8] to treat middle cerebral artery aneurysm located in the lateral sylvian fissure. Among these various cranial keyhole approaches, the Perneczky method and its variant lateral supraorbital keyhole approach are the basic keyhole strategies. This review describes and discusses the surgical nuances of these two approaches.

Access this article online	
Quick Response Code:	Website: www.asianjns.org
	DOI: 10.4103/1793-5482.131059

Address for correspondence:

Prof. Kentaro Mori, Department of Neurosurgery, National Defense Medical College, 3-2 Namiki, Tokorozawa, Saitama 359-8513, Japan.
E-mail: kmori@ndmc.ac.jp

Pre-operative computer-assisted simulation for tailor-made keyhole surgery

The keyhole surgery approach forms the minimum skull window to access deeply situated pathologies in the cranium,

so accurate pre-operative information is essential about the exact location and size of the mini-craniotomy to determine the precise trajectory. Pre-operative planning for keyhole surgery is mainly based on three-dimensional computed tomography angiography (3D-CTA). The author has developed a tailor-made method based on surgical simulation using 3D imaging of individual patients to allow safe performance of aneurysm clipping or tumor removal via computer simulation of the keyhole mini-craniotomy.^[10] Briefly, after intra-venous injection of 50 mL iodinated contrast medium, the imaging data obtained using multi-detector row computer tomography

are transferred to the workstation (Mimics, version 13.1, Materialise) to generate the 3D-CTA images. The 3D images reconstruct the skin, skull, cerebral arteries and veins, and the aneurysm or tumor. Various shapes and sizes of virtual mini-craniotomy are generated by computer graphics to optimize the visualization of the target through this “keyhole” [Figure 3a and b]. The size, shape, and location of the planned keyhole, and the head position can be accurately determined by this virtual osteotomy technique [Figure 3c and d].^[10] However, repair of the opened frontal sinus with pericranial flap is not possible after keyhole mini-craniotomy, so the planned site of the keyhole craniotomy should not overlap the frontal sinus.

Surgical procedures and nuances of the Perneczky method (supraorbital keyhole approach) and lateral supraorbital keyhole approach

The patient is positioned in the supine position. The degree of head rotation should be determined by the pre-operative 3D simulation as described above [Figure 4a]. Generally, a slightly chin-up position is preferable because of the gravity-related self-retraction of the frontal lobe. The head is fixed

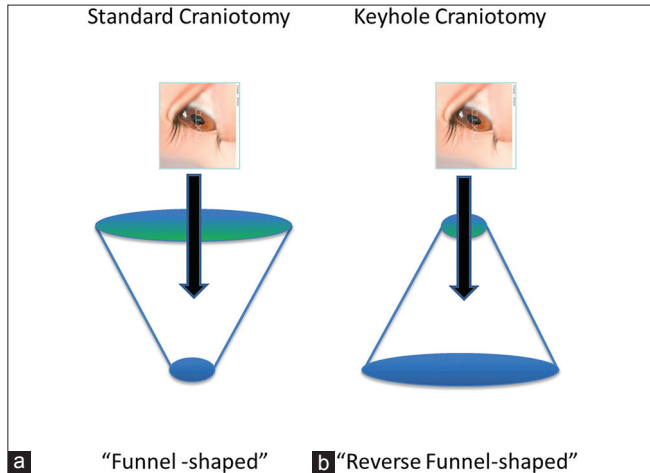


Figure 1: Comparison of the surgical corridors of standard craniotomy and keyhole craniotomy. Standard craniotomy provides a “funnel-shaped surgical corridor” (a), whereas keyhole mini-craniotomy provides a “reverse funnel-shaped surgical corridor” (b)

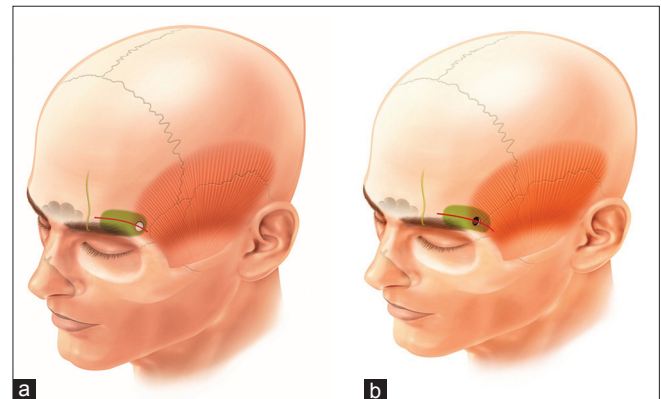


Figure 2: Schematic illustrations of the supraorbital keyhole (a) and lateral supraorbital keyhole (b) approaches. The red lines indicate the supraclavicular incision and the green shading shows the keyhole mini-craniotomy. Note the skin incision and the keyhole of the lateral supraorbital keyhole approach are located more laterally than those of the supraorbital keyhole approach

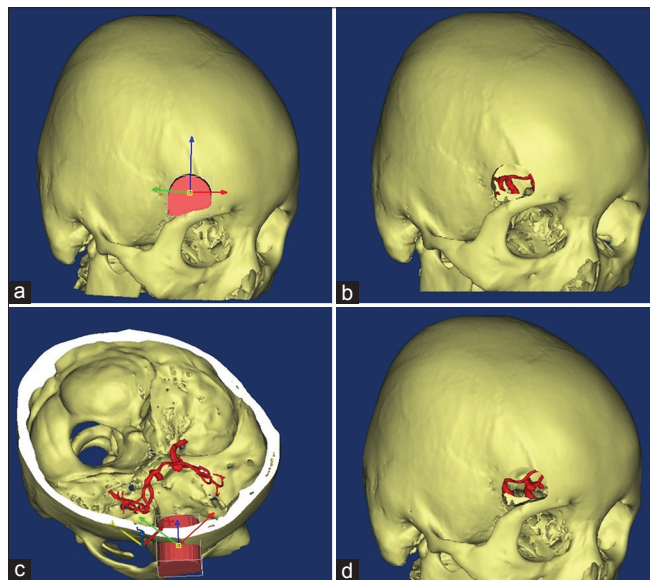


Figure 3: Virtual osteotomy technique to determine the location of the scheduled keyhole and head positioning. The “keyhole” generated by the computer graphics is applied to the 3D skull to determine the location of the scheduled lateral supraorbital keyhole from the relationship to the aneurysm (a and b); the skull with the target A-com A aneurysm complex is rotated at various angles to optimize the visualization (c and d)

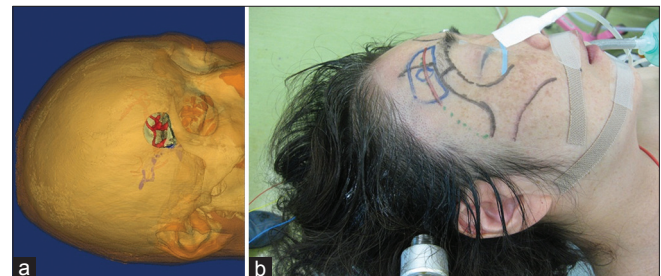


Figure 4: Pre-operatively determined lateral supraorbital keyhole and head position (a) and photograph during surgery; (b) the landmark structures such as the orbit, orbito-zygomatic suture, and zygoma are marked on the face with black lines. The scheduled keyhole is marked with a blue line and the eyebrow skin incision with a red line

with a Mayfield tri-pin holder. The landmark structures such as the orbit, supraorbital notch, superior temporal tine, orbito-zygomatic suture, and frontal sinus are marked on the face [Figure 4b]. The planned supraorbital mini-craniotomy is also marked on the face. Opening of the frontal sinus and supraorbital notch should be avoided. As mentioned above, cases with huge frontal sinus are contraindicated for the supraorbital keyhole approach because sinus repair with the pericranial patch is not possible. Generally, the eyebrow skin incision starts from the supra-orbital notch and extends to 5 mm lateral to the end of the scheduled mini-craniotomy (length is about 4.5 cm). The skin incision should be made along the relaxed skin tension line for the best cosmetic result. If the wrinkle over the eyebrow is deep, this fold can be used as the skin incision. The skin incision is extended more laterally for the lateral supraorbital keyhole. After the skin incision, the frontalis muscle is divided. The skin is retracted using fish hooks with rubber bands. The temporal fascia is incised for about 15 mm along the superior temporal line to the orbito-zygomatic process, and the temporal muscle is subperiosteally dissected around the McCarty point [Figure 5a]. The temporal muscle is retracted posteriorly using fish hooks [Figure 5b]. Supraorbital keyhole surgery requires skin and muscle retraction toward the postero-inferior direction. Therefore, the wrap should be tightly hooked to the metal bar around the head. After the frontal bone over the orbital rim and McCarty point is exposed, a burr hole is made at the McCarty point and the supraorbital mini-craniotomy (about 25 × 20 mm) is made using a surgical saw. The mini-craniotomy for the lateral supraorbital keyhole is extended laterally up to the sphenoid ridge using a high-speed drill (about 30 × 20 mm) [Figure 5c]. The frontal base dura mater is dissected up to the level of the planum sphenoidale, and the bony ridge over the orbit (Juga) is drilled away using a high-speed drill to flatten the frontal base. This maneuver improves the operative view through the subfrontal approach and does not require additional orbital rim removal. The dura mater is incised in a curvilinear fashion and reflected toward the orbital side [Figure 5d]. Under the operating microscope, the arachnoid membrane over the frontal base near the sylvian fissure is incised using a micro-blade and the cerebrospinal fluid (CSF) is aspirated. Once the brain becomes slack, a tapered spatula is advanced 5-10 mm toward the chiasmatic cistern. Then the arachnoid membrane ahead of the spatula tip is again incised and CSF is carefully aspirated, and the spatula is further advanced little by little (creeping technique). Brain retraction by the spatula is limited to within 10 mm over the frontal base. These procedures are repeated until the chiasmatic area is developed, so this technique can avoid brain contusion. The chiasmatic cistern is opened, and massive CSF is aspirated until the brain becomes slack enough. The medial sylvian fissure is opened in an antegrade fashion. The internal carotid artery (ICA), A1 the A1 portion of the anterior cerebral artery, and proximal M1 are exposed. These keyhole approaches are basically the subfrontal route, and opening of the medial sylvian

fissure provides the relatively wide operative view around the prechiasmatic area to the parasellar region. After aneurysm clipping or tumor removal, arachnoid plasty is performed using fibrin-glue soaked Surgicel sheet to seal the opened arachnoid membrane as far as possible to reduce post-operative subdural fluid collection. The dura mater is closed in watertight fashion. In our institution, the bony defect is sealed with a single pterion titanium plate. The frontalis muscle is closed using 4-0 vicryl suture, the subcutaneous tissue is closed using 5-0 polydioxanone absorbable suture (PDS[®], Ethicon, Inc.), and the skin is closed with either 6-0 nylon suture or derma-bond. No drain is placed. The operating microscope and the endoscope are generally used for observation of the target pathologies and confirmation of complete clipping. Trans-cranial muscle evoked potential (MEP) monitoring is used for monitoring the safety of aneurysm clipping procedures.

Representative cases

Case 1: A-com A aneurysm

A 51-year-old woman had suffered from mild headache. Magnetic resonance (MR) angiography revealed a small anterior communication artery aneurysm. The patient was referred to our institution. Pre-operative planning simulation with 3D-CTA determined the size and location of the optimum lateral supraorbital keyhole and head positioning. Based on this decision, the head was fixed with a Mayfield tri-pin holder [Figure 4]. The landmark structures and the scheduled keyhole were marked on the face [Figure 4]. The eyebrow skin incision was made and the temporal fascia was detached along the superior temporal line to the orbito-zygomatic process, and then the temporal muscle was dissected and retracted posteriorly [Figure 5a and b]. The supraorbital keyhole was made and extended to the lateral sphenoid ridge [Figure 5c]. The frontal base was flattened epidurally using a high-speed drill. The dura was opened in a curvilinear fashion [Figure 5d]. The subfrontal route was chosen using the creeping technique. CSF was aspirated after opening the carotid cistern, the medial sylvian fissure was opened, and the ICA, M1, and A1 were exposed. The rectal gyrus was subpially aspirated and the A-com A aneurysm complex was exposed [Figure 6a]. After a temporary clip was placed on the ipsilateral A1, neck clipping was performed [Figure 6b]. After dural closure, the bony defect was sealed with a pterion plate and the wound was closed as described above. The patient was discharged on the third post-operative day without any neurological deficits.

Case 2: Planum sphenoidale meningioma

A 78-year-old woman suffered from dizziness. MR imaging showed a small planum sphenoidale meningioma. MR imaging demonstrated the planum sphenoidale meningioma before and after surgery as shown in Figure 7. The size and optimum location of the scheduled keyhole were determined using 3D-CTA simulation [Figure 8]. The eyebrow skin incision and lateral supraorbital keyhole were made [Figure 9a and b]. The

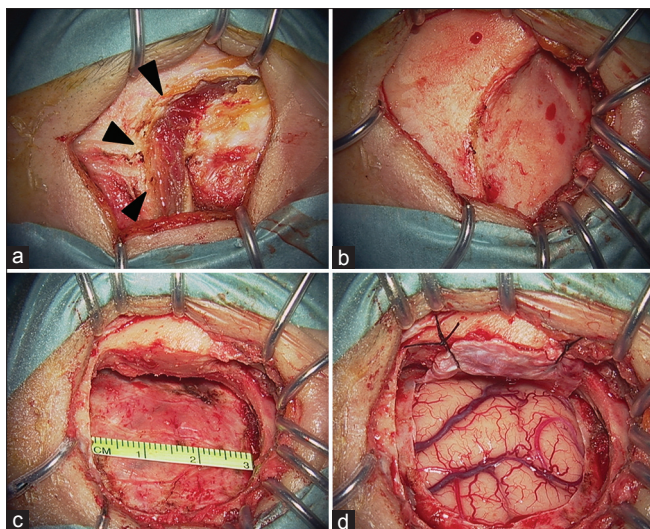


Figure 5: Intraoperative photographs during lateral supraorbital keyhole surgery for A-com A aneurysm. (a) Temporal fascia is incised along the superior temporal line to the orbito-zygomatic process; (b) temporal muscle is retracted posteriorly using hooks; (c) lateral keyhole mini-craniotomy is extended to the sphenoid ridge (arrowheads); (d) after dural opening

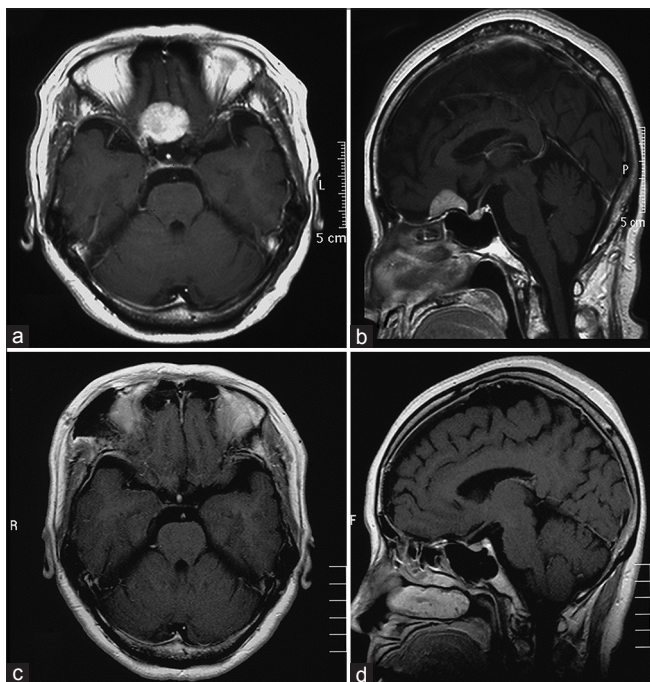


Figure 7: Magnetic resonance images of the planum sphenoidale meningioma before (a and b) and after (c and d) tumor removal via the lateral supraorbital keyhole mini-craniotomy

subfrontal approach was performed and the carotid cistern was opened. Massive CSF was aspirated and the brain became slack. The medial sylvian fissure was opened and the frontal lobe was gently elevated. The tumor was exposed [Figure 9c]. The tumor attachment on the planum sphenoidale was coagulated and detached. The tumor was debulked and detached from the surrounding brain structures in an epi-arachnoid fashion. The tumor was completely resected [Figure 9d]. After dural

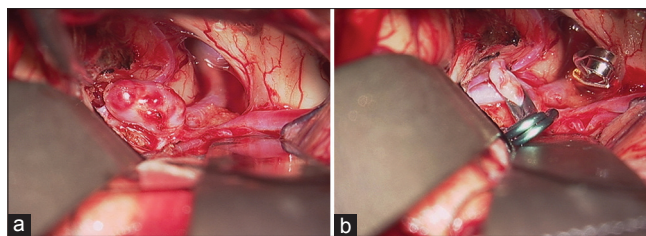


Figure 6: Photographs obtained during the lateral supraorbital keyhole approach for A-com A aneurysm. (a) A-com A aneurysm is exposed after resection of the rectal gyrus; (b) after neck clipping

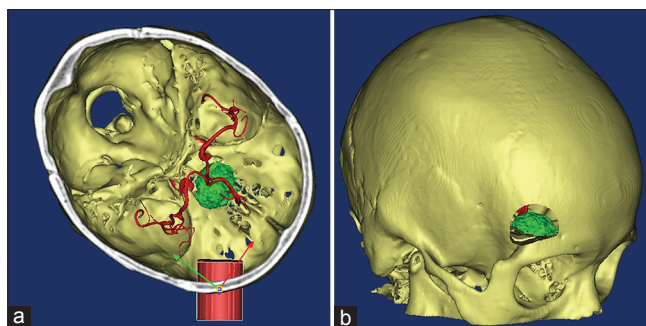


Figure 8: Pre-operative surgical planning using 3D images of the skull, cerebral arteries, and the planum sphenoidale meningioma (green). (a) The “keyhole” generated by the computer graphics is applied to the 3D skull to determine the location of the scheduled lateral supraorbital keyhole from the relationship to the tumor; (b) the skull with the target tumor is rotated at various angles to optimize the visualization

closure, the bony defect was fixed with a single pterion titanium plate [Figure 10a]. The wound was closed as described above [Figure 10b]. The patient was discharged on the fifth post-operative day without any sequelae.

Surgical results of keyhole clipping surgery

A total of 220 consecutive keyhole clipping surgeries for 230 unruptured cerebral aneurysms were performed in 210 patients, 143 women and 67 men aged from 34 years to 79 years (mean \pm standard deviation: 62.3 ± 8.9 years), in the Juntendo University Shizuoka Hospital from June 2007 to December 2011. All operations were performed by the author (K.M.) The 128 cases of middle cerebral artery aneurysm were clipped via pterional keyhole surgery, the 53 cases of the A-com A aneurysm were clipped via lateral supraorbital keyhole surgery, and the 39 cases of the ICA aneurysm were clipped via supraorbital keyhole surgery. The size of the aneurysm, size of the keyhole, operation time, and post-operative hospitalization days are shown in Table 1. The surgical results are described in Table 2. Neck remnant persisted in 3 cases, and one case was clipped through the standard pterional approach later. None of the cases required change to the standard craniotomy during the scheduled keyhole surgeries. The mortality was 0% and the morbidity was 0.9%. Post-operative CT/MR imaging showed six cases of lacunar infarction (2.7%), but neither brain contusion nor hemorrhagic complication occurred. Most of the patients (91%) were discharged within 3 days after the surgery.

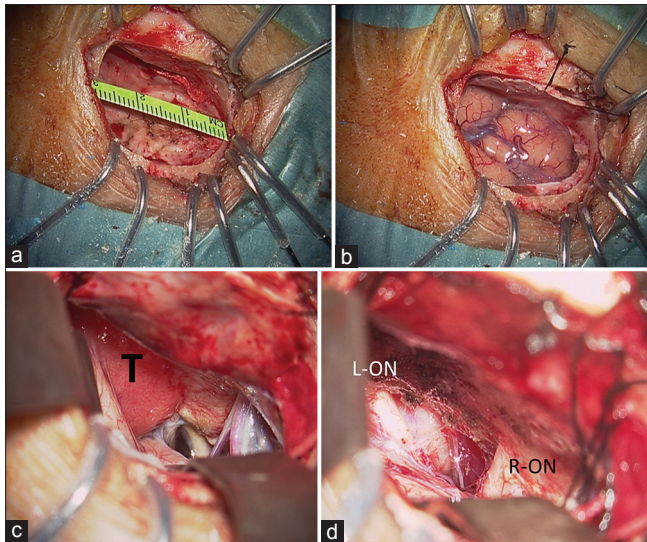


Figure 9: Photographs obtained during the lateral supraorbital keyhole approach to planum sphenoidale meningioma. (a) Lateral supraorbital keyhole mini-craniotomy; (b) after dural opening; (c) planum sphenoidale meningioma (t) and the right internal carotid artery are exposed; (d) after tumor removal. The left (L-ON) and right (R-ON) optic nerves are exposed

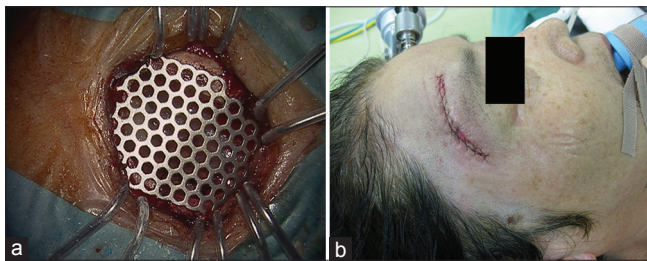


Figure 10: Photographs obtained during the lateral supraorbital keyhole approach to planum sphenoidale meningioma. (a) Titanium mini-plate seals the bony defect; (b) After the operation

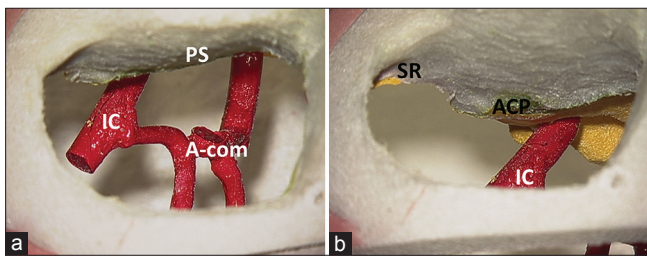


Figure 11: Operative views via the lateral supraorbital keyhole mini-craniotomy in the artificial skull model with artificial anterior communicating artery (A-com A) complex. (a) The lateral supraorbital keyhole approach provides good operative views from the planum sphenoidale to the A-com A complex; and (b) the parasellar region. ICA – Internal carotid artery, PS – Planum sphenoidale, SR – Sphenoid ridge, ACP – Anterior clinoid process

Discussion

Comparison with pterional approach and indications for the lateral supraorbital keyhole approach

The standard pterional approach via fronto-temporal

Table 1: Summary of 220 keyhole clipping surgeries

Type of keyhole	Pterional	Lateral supraorbital	Supraorbital
Number of cases	128	53	39
Target aneurysm	MCA	A-com A	ICA
Size of aneurysm (mm)	6.5±1.8	6.4±1.8	5.8±1.5
Size of keyhole			
Maximal diameter (mm)	25±2	30±3	29±2
Minimal diameter (mm)	23±2	24±3	22±2
Operation time (min)	163±31	193±36	163±26
Hospitalization (day)	2.3±3.5	2.4±2.3	3.7±7.8

MCA – Middle cerebral artery; A-com A – Anterior communicating artery; ICA – Internal carotid artery; The values are means±standard deviation

Table 2: Surgical results of 220 keyhole clipping surgeries (230 unruptured aneurysms)

Neck clipping	225	(%)	
Neck remnant	3 (1 re-op)		
Wrapping	2		
mRS			
Grade 0	218	(99.1)	
Grade 1	1	(0.45)	Mild dementia
Grade 2	0	(0)	
Grade 3	1	(0.45)	Hemiparesis
Grade 4	0	(0)	
Grade 5	0	(0)	
Grade 6	0	(0)	

mRS – Modified rankin scale

craniotomy has been a major technique in the treatment of intracranial pathologies, but the introduction of modern neuroimaging technologies, endoscopic assistance, surgical techniques, and other developments have encouraged the adoption of less invasive techniques including the keyhole approaches for a subset of patients. The intracranial keyhole approaches are innovative techniques to minimize approach-related injuries in the skull and soft tissues including the temporal muscle. The concept of keyhole neurosurgery is to access deep intracranial lesions through the minimum craniotomy. The spatial relationship between the small cranial window and the relatively wide operative field provides a reverse funnel-shaped surgical corridor [Figure 1]. This special corridor provides a wide operative field but limits the working angle.^[11] This limited working angle is generally the one of the major disadvantages of keyhole strategies and limits the directions for observation and manipulation of the target pathologies. Compared with the pterional approach, the lateral supraorbital approach offers equivalent access to the A-com A complex and sellar to parasellar regions, but less access to the retrosellar area.^[11] The lateral supraorbital keyhole approach provides a more median trajectory than the pterional approach with a lateral trajectory.^[12] 3D skull modeling with artificial cerebral arteries can show the operative view from the lateral supraorbital keyhole [Figure 11]. The lateral supraorbital

keyhole approach provides a good operative view from the planum sphenoidale to the A-com A complex [Figure 11a] and the parasellar region [Figure 11b]. However, the middle fossa under the sphenoid ridge and the anterior part of the frontal fossa (olfactory groove area) are obscured from the operative view. Therefore, it is reasonable to avoid tumor removal in these locations unless using “pull-surgery.” Understanding the limitations of the operative field and the reduced working angle in keyhole surgeries including the lateral supraorbital approach is extremely important to determine the appropriate surgical indications for safe procedures. In our institution, we limit use of the lateral supraorbital keyhole approach to relatively small and anteriorly projecting unruptured A-com A aneurysm, laterally projecting ICA aneurysm, and small parasellar to presellar tumors. Although the lateral supraorbital keyhole approach has been recommended to remove olfactory groove meningioma by experts with this approach,^[13] we would rather select the classical approaches to treat tumors in the midline of the anterior part of the frontal fossa. Middle cerebral artery aneurysm should be treated by pterional or sphenoid ridge keyhole approaches because of the location in the lateral sylvian fissure.^[8,14]

Use of the endoscope

Keyhole surgery requires neuro-endoscopic assistance for safe procedures.^[3,6,15] However, the endoscopic view is two-dimensional and the author uses the operating microscope as the main tool to manipulate the pathologies and the endoscope is used only for observation. In our institution, we have also introduced trans-cranial MEP monitoring and indocyanine green video-angiography during surgery to avoid surgical complications in addition to the pre-operative simulation using 3D-CTA.

Cosmetic issues

Most keyhole approaches can avoid scalp hair shaving but the skin incision on the face is the major disadvantage of this procedure. However, meticulous and multiple layered wound closure of the eyebrow skin incision promises satisfactory cosmetic results by a few months after the operation as long as the wound is made along the relaxed skin tension line or wrinkle. The supraorbital keyhole approach requires only partial dissection of the temporal muscle but may still cause the formation of dimpling behind the superior temporal line (anterior temporal hollow) due to local temporal muscle atrophy. Such post-operative temporal halo formation can be avoided using a convex-shaped titanium pterion plate that compensates for any temporal muscle atrophy.^[9]

Comparison with other variants of supraorbital keyhole approaches

Other variants of the lateral supraorbital keyhole are the orbitofrontozygomatic or transorbital keyhole approaches that include removal of the orbital bar with the anterior part of the orbital roof.^[16-19] These approaches combine supraorbital

minicraniotomy with removal of the frontal orbital bar with orbital roof to facilitate better access to intradural lesions. We do not remove either the orbital bar or orbital roof, instead we completely drill away any bony prominences on the orbital roof to flatten the surgical corridor in the base of the anterior cranial fossa.^[9,20] The author does not recommend removal of orbital bony structures. Complicated pathologies that require the orbital or zygomatic bone removal should not be indicated for the keyhole approaches.

Conclusions

The disadvantage of the keyhole approach is the limited working angle that hinders the observation and manipulation of the targets from various directions. The use of appropriate keyhole mini-craniotomy combined with careful pre-operative planning to select the surgical trajectory, intraoperative endoscopic assistance, and monitoring systems can avoid the disadvantages associated with standard craniotomy.^[21,22] However, we should remember that although keyhole mini-craniotomy surgery is intended to achieve “minimally invasive neurosurgery,” these procedures carry the risks of malpractice if the neurosurgeon does not understand the advantages and disadvantages of these keyhole concepts and strategies.

References

1. Perneckzy A, Muller-Forell W, Lindert E, Fries G. Current strategies in keyhole and endoscope-assisted microneurosurgery. In: Perneckzy A, editor. *Keyhole Concept in Neurosurgery*. Stuttgart: Thieme Medical Publishers; 1999. p. 37-51.
2. Fukushima T. The key of keyhole microsurgery brain protective operation. In: Fukushima T, Sameshima R, editors. *Manual of Skull Base Dissection*. 2nd ed. Raleigh: AF-Neuro Video, Inc.; 2004.
3. Fischer G, Oertel J, Perneckzy A. Endoscopy in aneurysm surgery. *Neurosurgery* 2012;70:184-90.
4. Reisch R, Perneckzy A, Filippi R. Surgical technique of the supraorbital key-hole craniotomy. *Surg Neurol* 2003;59:223-7.
5. Reisch R, Perneckzy A. Ten-year experience with the supraorbital subfrontal approach through an eyebrow skin incision. *Neurosurgery* 2005;57:242-55.
6. Fischer G, Stadie A, Reisch R, Hopf NJ, Fries G, Böcher-Schwarz H, *et al*. The keyhole concept in aneurysm surgery: Results of the past 20 years. *Neurosurgery* 2011;68:45-51.
7. Hernesniemi J, Ishii K, Niemelä M, Smrcka M, Kivipelto L, Fujiki M, *et al*. Lateral supraorbital approach as an alternative to the classical pterional approach. *Acta Neurochir Suppl* 2005;94:17-21.
8. Mori K, Osada H, Yamamoto T, Nakao Y, Maeda M. Pterional keyhole approach to middle cerebral artery aneurysms through an outer canthal skin incision. *Minim Invasive Neurosurg* 2007;50:195-201.
9. Mori K, Yamamoto T, Nakao Y, Oyama K, Esaki T, Watanabe M, *et al*. Lateral supraorbital keyhole approach to clip unruptured anterior communicating artery aneurysms. *Minim Invasive Neurosurg* 2008;51:292-7.
10. Mori K, Yamamoto T, Nakao Y, Esaki T. Tailor-made keyhole clipping for safe treatment of unruptured cerebral aneurysm [In Japanese]. *Surgery for Cerebral Stroke* 2011;39:89-95.
11. Figueiredo EG, Deshmukh V, Nakaji P, Deshmukh P, Crusius MU, Crawford N, *et al*. An anatomical evaluation of the mini-supraorbital approach and comparison with standard craniotomies. *Neurosurgery* 2006;59:ONS212-20.
12. Salma A, Alkandari A, Sammet S, Ammirati M. Lateral supraorbital

- approach vs pterional approach: An anatomic qualitative and quantitative evaluation. *Neurosurgery* 2011;68:364-72.
13. Romani R, Lehecka M, Gaal E, Toninelli S, Celik O, Niemelä M, *et al.* Lateral supraorbital approach applied to olfactory groove meningiomas: Experience with 66 consecutive patients. *Neurosurgery* 2009;65:39-53.
 14. Nathal E, Gomez-Amador JL. Anatomic and surgical basis of the sphenoid ridge keyhole approach for cerebral aneurysms. *Neurosurgery* 2005;56:178-85.
 15. Berhouma M, Jacquesson T, Jouanneau E. The fully endoscopic supraorbital trans-eyebrow keyhole approach to the anterior and middle skull base. *Acta Neurochir (Wien)* 2011;153:1949-54.
 16. Dare AO, Landi MK, Lopes DK, Grand W. Eyebrow incision for combined orbital osteotomy and supraorbital minicraniotomy: Application to aneurysms of the anterior circulation. Technical note. *J Neurosurg* 2001;95:714-8.
 17. Steiger HJ, Schmid-Elsaesser R, Stummer W, Uhl E. Transorbital keyhole approach to anterior communicating artery aneurysms. *Neurosurgery* 2001;48:347-52.
 18. Warren WL, Grant GA. Transciliary orbitofrontozygomatic approach to lesions of the anterior cranial fossa. *Neurosurgery* 2009;64:324-30.
 19. El Shafei HI. Anterolateral mini fronto-orbito-zygomatic craniotomy via an eyebrow incision in pediatrics: Technical notes and evaluation. *Pediatr Neurosurg* 2011;47:248-53.
 20. Jallo GI, Bognár L. Eyebrow surgery: The supraciliary craniotomy: Technical note. *Neurosurgery* 2006;59:ONSE157-8.
 21. Garrett M, Consiglieri G, Nakaji P. Transcranial minimally invasive neurosurgery for tumors. *Neurosurg Clin N Am* 2010;21:595-605.
 22. Mori K, Esaki T, Yamamoto T, Nakao Y. Individualized pterional keyhole clipping surgery based on a preoperative three-dimensional virtual osteotomy technique for unruptured middle cerebral artery aneurysm. *Minim Invasive Neurosurg* 2011;54:207-13.

How to cite this article: Mori K. Keyhole concept in cerebral aneurysm clipping and tumor removal by the supraciliary lateral supraorbital approach. *Asian J Neurosurg* 2014;9:14-20.

Source of Support: Nil, **Conflict of Interest:** None declared.