

CASE REPORT

Atypical medulloblastoma: A case series

Ali Meshkini, Amir Vahedi¹, Mohammad Meshkini², Hossein Alikhah³,
 Mohammad Naghavi-Behzad^{2,3}

Neuroscience Research Center, ¹Department of Pathology, ²Students' Research Committee, ³Medical Philosophy and History Research Center, Tabriz University of Medical Sciences, Tabriz, Iran

ABSTRACT

Medulloblastoma is common in children as a tumor of midline posterior fossa, which arises from vermis and appears as a homogeneously enhancing hyperdense mass on computed tomography scan and is associated with the clinical picture of posterior fossa syndrome. This unique clinic-radiological pattern in considered "typical" medulloblastoma, but medulloblastomas does not follow the typical clinic-radiological pattern in a significant number of children and adult cases. We review here the previous reports of atypical or uncommon features of medulloblastoma and add our very rare atypical cases of medulloblastomas to this list. Medulloblastoma should be considered in all midline posterior fossa tumors, hemisphere and cerebellopontine angle despite having clinical and radiological features suggestive of other tumors. Definitive diagnosis requires histologic confirmation in all cases.

Key words: Adult, atypical, children, computed tomography, magnetic resonance imaging, medulloblastoma

Introduction

Medulloblastoma is the most common malignant tumor of the brain in the pediatric population. It is a solid, homogeneously enhancing, midline tumor of the posterior fossa.^[1] As a primitive neuroectodermal tumor (PNET), it predominantly affects the cerebellum and IV ventricle.^[2] Its unique clinico-radiological pattern is referred as "typical" medulloblastoma. However, such typical subset of the disease is not common in clinical practice.^[3] Cyst formation, irregular enhancement, extension through the fourth ventricle foramina, manifestation as a neoplasm of the cerebellopontine angle and calcification are some of the atypical features.^[1,4,5]

Kumar *et al.* described uncommon presentations of medulloblastoma in 19 out of 42 patients, with cystic changes in 13, hypodense non-enhancing mass in 5, calcifications in 6

and tumors in very unusual location (i.e. the cerebellopontine angle cistern) in 3 patients.^[3] Furtado *et al.* reported on adult medulloblastoma with the dural tail sign, mimicking posterior petrous meningioma.^[6] A few studies have described uncommon features of medulloblastoma in children.^[7] The main diagnostic challenge here is that clinical presentation, imaging findings and prognosis in both children and adults substantially differ.^[8] In our study, we present our own series of atypical features of medulloblastoma.

Case Reports

Case 1

A 19-year-old girl patient presented with the complaints of headache and vomiting and mild truncal ataxia. On neurological examination, her Glasgow Coma Scale (GCS) was 15. Brain magnetic resonance imaging (MRI) was suggestive of an extra axial on the left side of the tentorium, with extension to both sides. Two necrotic areas were visible in the infra- and supratentorial components of the mass. Severe vasogenic edema was noticed at the cerebellum, with a mass effect and a resultant tonsillar herniation [Figure 1a and b]. Histopathologic examination showed highly cellular neoplasm composed of cells with medium sized and hyperchromatic nuclei, little cytoplasm and moderate nuclear pleomorphism as well as foci of necrosis, which is indicative of classic medulloblastoma [Figure 1c].

Case 2

A 16-year-old girl with a history of headache and vertigo was admitted to hospital emergently because of lethargy. She was ataxic, with abnormal cerebellar function tests. Brain MRI

Access this article online	
Quick Response Code:	Website: www.asianjns.org
	DOI: 10.4103/1793-5482.131077

Address for correspondence:

Dr. Mohammad Naghavi-Behzad, Medical Philosophy and History Research Center, Tabriz University of Medical Science, Daneshgah Street, Tabriz, Eastern Azerbaijan, Iran.
 E-mail: Dr.Naghavii@gmail.com

revealed an extra axial mass in the left cerebellar hemisphere with dural enhancement. Though MRI-based initial diagnosis was meningioma [Figure 2a], Histopathologic examination showed highly cellular neoplasm composed of large cells with hyperchromatic nuclei, scant cytoplasm, nuclear molding and moderate pleomorphism, consistent with undifferentiated medulloblastoma [Figure 2b].

Case 3

A 27-year-old woman presented with a history of vertigo, malaise and frequent vomiting. On neurological examination, cerebellar function tests were abnormal. MRI investigations picked a solid mass in the posterior fossa and the left hemispheric lesion and mild hydrocephalus [Figure 3a and b]. Histopathologic examination showed proliferation of large cells

with hyperchromatic nuclei and scant cytoplasm, as well as nodular foci of tumor in less cellular areas, which is indicative of desmoplastic nodular medulloblastoma [Figure 3c].

Case 4

A 7-year-old girl presented with a history of headache and vomiting for 2 months and purulent sputum discharge for several months. Her GCS was 15 and had mildly abnormal cerebellar function tests, such as nystagmus and ataxia. Brain MRI detected a huge cerebellar hemispheric mass with cystic and solid components and extension to the brain stem and cerebellopontine angle [Figure 4a]. Histopathologic examination showed proliferation of large neoplastic cells with hyperchromatic nuclei and scant cytoplasm, moderate mitosis, extensive areas of necrosis and nodular arrangement,

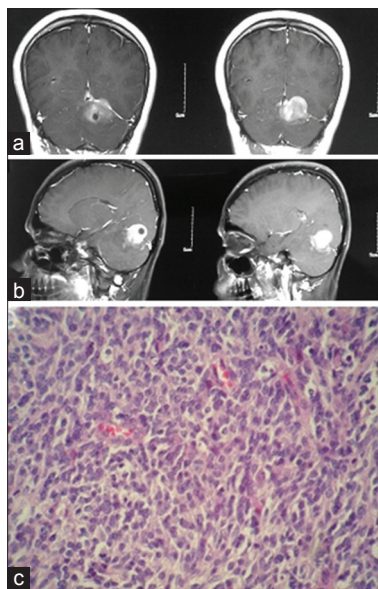


Figure 1: (a) Magnetic resonance imaging (MRI) Coronal view with contrast; (b) MRI Sagittal view; (c) histopathology showed proliferation of cells with hyperchromatic nuclei and scant cytoplasm

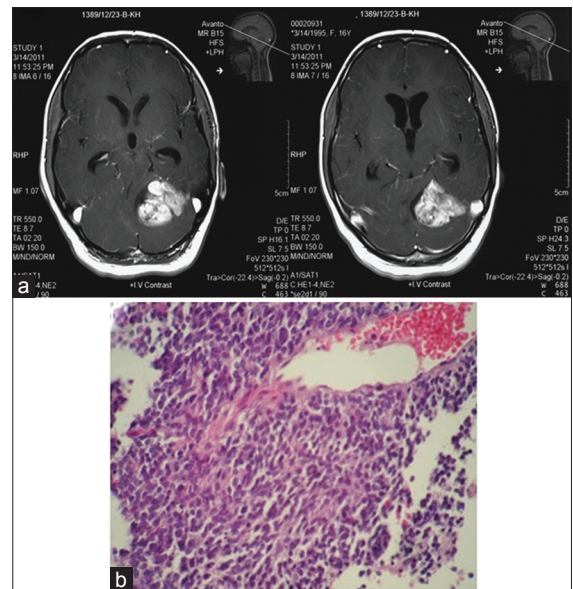


Figure 2: (a) Axial magnetic resonance imaging with contrast; (b) histopathology showed proliferation of undifferentiated cells with nuclear molding, surrounding vessel

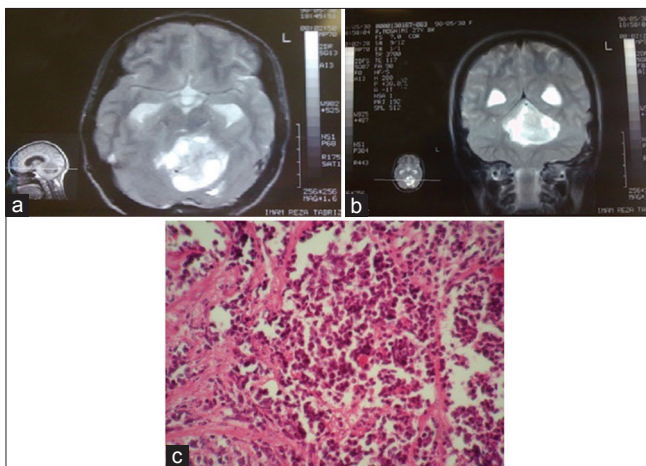


Figure 3: (a) Magnetic resonance imaging axial view T2; (b) coronal view T2; (c) histopathology showed hypocellular areas with nodular fashion (Pale islands)

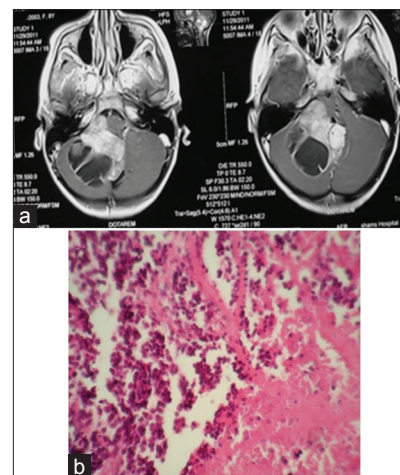


Figure 4: (a) Axial magnetic resonance imaging with contrast; (b) histopathology showed proliferation of hyperchromatic cells with areas of necrosis

which is indicative of desmoplastic nodular medulloblastoma [Figure 4b].

Discussion

Posterior fossa PNETs, or medulloblastomas, are the most common malignant, solid tumors of the brain in children. This disease is diagnosed in about 20% of cases of pediatric brain tumors and in one-third of all cases of posterior fossa tumors.^[9] For a comparison, medulloblastomas account for just 1% of adult brain tumors.

Computed tomography (CT) scan or MRI are the main diagnostic options for pediatric medulloblastomas. On CT scanning, medulloblastomas are typically characterized as hyperdense neoplasms with homogenous contrast enhancement. They may be partially cystic as well.

Usually, these tumors have small calcified and cystic formations. Extensive calcifications are rarely visualized by MRI as iso- or hypointense structures on T1-weighted scans, hyperintense - on T2-weighted scans and intensively enhanced - after gadolinium injection. Nearly, 10-15% of medulloblastomas are not enhanced on contrast MRI scans, which makes it difficult to rule out residual disease post-operatively.^[9]

The above presented cases of supra- and infratentorial components of medulloblastoma and extra-axial mass in the left cerebellar hemisphere with dural enhancement add valuable diagnostic information to the published literature on uncommon and atypical forms and loci of medulloblastoma. We may assume that atypical characteristics of the tumor are not so uncommon in children and young adults. Medulloblastomas should be included in the list for differential diagnosis of any

posterior fossa mass. Besides, medulloblastoma should be ruled out in a patient with posterior fossa mass, clinically and radiologically interpreted as a low-grade tumor or meningioma.

Unfortunately, precise radiologic features distinguishing medulloblastomas from other posterior fossa tumors are not yet described and pathomorphology of the excised tumors is the only valid option to rule in or out medulloblastomas.^[9]

References

1. Mueller DP, Moore SA, Sato Y, Yuh WT. MRI spectrum of medulloblastoma. *Clin Imaging* 1992;16:250-5.
2. Yazigi-Rivard L, Masserot C, Lachenaud J, Diebold-Pressac I, Aprahamian A, Avran D, *et al.* Childhood medulloblastoma. *Arch Pediatr* 2008;15:1794-804.
3. Kumar R, Achari G, Banerjee D, Chhabra DK. Uncommon presentation of medulloblastoma. *Childs Nerv Syst* 2001;17:538-42.
4. Prasad VS, Reddy DR, Sundaram C. Calcified medulloblastoma in a child. *Clin Imaging* 1994;18:275-6.
5. Meshkini A, Shahzadi S, Alikhah H, Naghavi-Behzad M. Role of stereotactic biopsy in histological diagnosis of multiple brain lesions. *Asian J Neurosurg* 2013;8:69-73.
6. Furtado SV, Venkatesh PK, Dadlani R, Reddy K, Hegde AS. Adult medulloblastoma and the “dural-tail” sign: Rare mimic of a posterior petrous meningioma. *Clin Neurol Neurosurg* 2009;111:540-3.
7. Eran A, Ozturk A, Aygun N, Izbudak I. Medulloblastoma: Atypical CT and MRI findings in children. *Pediatr Radiol* 2010;40:1254-62.
8. Behbahani M, St George EJ, Dunn LT, Hadley DM, Stewart W. Atypical adult medulloblastoma. *Acta Neurochir (Wien)* 2011;153:1511-7.
9. Winn HR, Berger MS, Dacey RG Jr, editors. *Youmans Neurological Surgery*. 6th ed. Philadelphia, PA: Elsevier; 2011.

How to cite this article: Meshkini A, Vahedi A, Meshkini M, Alikhah H, Naghavi-Behzad M. Atypical medulloblastoma: A case series. *Asian J Neurosurg* 2014;9:45-7.

Source of Support: The work is original and the sole supporter of this work was Tabriz University of Medical Sciences, **Conflict of Interest:** None declared.

New features on the journal's website

Optimized content for mobile and hand-held devices

HTML pages have been optimized of mobile and other hand-held devices (such as iPad, Kindle, iPod) for faster browsing speed.

Click on [**Mobile Full text**] from Table of Contents page.

This is simple HTML version for faster download on mobiles (if viewed on desktop, it will be automatically redirected to full HTML version)

E-Pub for hand-held devices

EPUB is an open e-book standard recommended by The International Digital Publishing Forum which is designed for reflowable content i.e. the text display can be optimized for a particular display device.

Click on [**EPub**] from Table of Contents page.

There are various e-Pub readers such as for Windows: Digital Editions, OS X: Calibre/Bookworm, iPhone/iPod Touch/iPad: Stanza, and Linux: Calibre/Bookworm.

E-Book for desktop

One can also see the entire issue as printed here in a 'flip book' version on desktops.

Links are available from Current Issue as well as Archives pages.

Click on  View as eBook