

## CASE REPORT

# Challenges in a case of ophthalmic artery aneurysm associated with abnormal internal carotid arteries

Eduard B. Dinca<sup>1,2</sup>, Felix Brehar<sup>2</sup>, Andrei Giovani<sup>2</sup>, Alexandru V. Ciurea<sup>2</sup>

<sup>1</sup>Department of Neurosurgery, The National Centre for Stereotactic Radiosurgery, Royal Hallamshire Hospital, Sheffield, United Kingdom, <sup>2</sup>“Bagdasar-Arseni” Institute for Excellence in Neurosurgery, Bucharest, Romania

## ABSTRACT

Ophthalmic artery aneurysms account for 5% of all cerebral aneurysms and are an important cause of morbidity and mortality related to subarachnoid hemorrhage. The diagnosis is often made only when the aneurysm is large enough to become symptomatic. They remain technically challenging for both neurosurgeon and interventional radiologist. We present the case of a 62-year-old woman admitted for transient loss of consciousness, followed by generalized tonic-clonic seizures. Computed tomography (CT) showed a subarachnoid hemorrhage (SAH), clinically graded as Hunt and Hess III. Magnetic resonance imaging (angioMR) and the four-vessel digital subtraction angiography (DSA) identified a ruptured, 8 mm left ophthalmic artery aneurysm. Embolization was the first therapeutic choice. Nevertheless, the attempt had to be aborted due to a combination of a hypoplastic right internal carotid artery (ICA) and an irregular atheromatous plaque on the left ICA, rendering the procedure unduly hazardous. Therefore, microsurgical clipping of the aneurysm became the procedure of choice. Postoperatively, the patient was in good condition, with no visual and neurological deficits. At 6 months follow up, she was assigned maximum scores of 5 and 8 on the Glasgow Outcome Scale (GOS) and Extended GOS (GOS-E), respectively. Aneurysm rupture represents a neurosurgical emergency and an early intervention (less than 48 h) is recommended to maximize the chances of deficit-free survival. The peculiarities of this case consisted in the combination between the size and the location of the aneurysm, abrupt presentation, and the impossibility of embolization due to bilateral ICA abnormalities, congenital (hypoplastic right ICA) and acquired (extensively atherosclerotic left ICA).

**Key words:** Digital subtraction angiography, embolization, microsurgery, ophthalmic artery aneurysms

## Introduction

Aneurysms account for 0.2-7.9% of all cerebrovascular lesions, with 5% of them being ophthalmic artery aneurysms.<sup>[1]</sup> These are usually discovered when they are large enough to become symptomatic, with diplopia and headache.

Most surgical interventions occur as emergencies, addressing delicate situations when life is at risk. Any kind of vascular surgery has a great hemorrhagic, and subsequently, ischemic risk. Even in best hands, the techniques of clipping or vessel anastomosis continue to have a high morbidity

and mortality risk.<sup>[2,3]</sup> Ophthalmic artery aneurysms pose particular challenges to both neurosurgeon and interventional radiologist. Modern embolization techniques proved safe and effective, raising the survival and the quality of life for ophthalmic artery aneurysms patients; thus, it has become the standard of care.<sup>[2]</sup> Nevertheless, there are cases where embolization is impossible to perform or is fraught with unacceptable danger (giant lesions, ICA abnormalities), and a swift microsurgical solution is needed.

## Case Report

We present the case of a 62-year-old woman, admitted to a local hospital following a short episode of loss of consciousness related to physical effort, with subsequent generalized

Access this article online	
<b>Quick Response Code:</b> 	<b>Website:</b> <a href="http://www.asianjns.org">www.asianjns.org</a>
	<b>DOI:</b> 10.4103/1793-5482.144160

### Address for correspondence:

Dr. Eduard B. Dinca, The National Centre for Stereotactic Radiosurgery, Royal Hallamshire Hospital, Glossop Rd, Sheffield S10 2JF, United Kingdom. E-mail: Eduard.Dinca@gmail.com

This is an open access article distributed under the terms of the Creative Commons Attribution-NonCommercial-ShareAlike 3.0 License, which allows others to remix, tweak, and build upon the work non-commercially, as long as the author is credited and the new creations are licensed under the identical terms.

**For reprints contact:** [reprints@medknow.com](mailto:reprints@medknow.com)

**How to cite this article:** Dinca EB, Brehar F, Giovani A, Ciurea AV. Challenges in a case of ophthalmic artery aneurysm associated with abnormal internal carotid arteries. *Asian J Neurosurg* 2017;12:106-8.

tonic-clonic seizures. The patient had features of Hunt and Hess Grade III SAH which was confirmed by CT scan and was referred to the Bagdasar Arseni Emergency Hospital for further management. An angio-CT scan [Figure 1] and a four-vessel DSA [Figure 2] were performed, which showed a ruptured ophthalmic artery aneurysm.

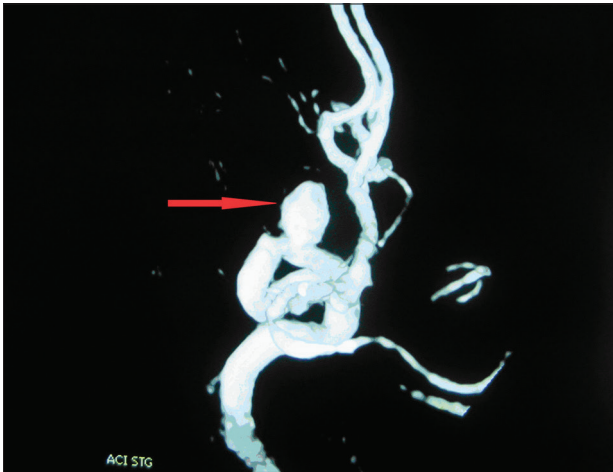
During the diagnostic angiography, the interventional radiologist also attempted endovascular treatment, but embolization had to be aborted due to the anatomic particularities of the case. In addition to the multilobulated aspect of the left ophthalmic artery aneurysm, the left ICA was intensely atheromatous, and the right ICA was hypoplastic. These findings related a high thrombo-embolic risk and rendered the endovascular treatment impossible.

Given this particular anatomical setting, we decided to perform an early surgical intervention, hoping to offer the patient the best chance of avoiding subsequent vasospasm. The intervention proved challenging, as the aneurysm size and

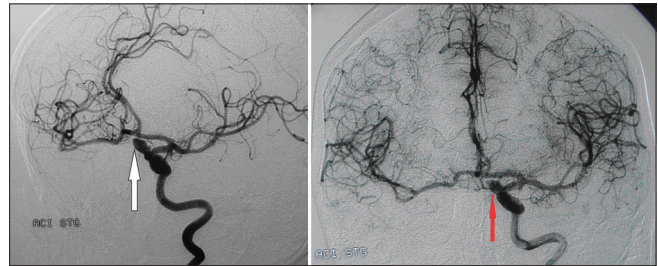
location provided a very narrow working space. The surgical procedure was performed in a classic fashion, beginning with a left pterional flap. The proximal sylvian fissure was dissected after brain relaxation was obtained by having inserted an external ventricular drain into the frontal horn of the lateral ventricle. The ICA was then followed from the bifurcation to the emergence from the cavernous sinus, and additional CSF leakage provided further brain relaxation. We did not need to use a temporal clip, as the proximal ICA was adequately exposed. The base of the left anterior clinoid process was subsequently drilled and the aneurysm was dissected from its adherences. A 10 mm Yasargil titanium clip was applied on the neck of the aneurysm, parallel to the ophthalmic artery. Previously, the artery had been carefully dissected from its adherences to the neck of the aneurysm, to make sure it remained under the clip. The clip positioning was inspected to make sure the aneurysm was well clipped and there was no kinking.

An angio-CT performed on the first postoperative day proved the integrity of the circle of Willis and the integrity of the flux in the left ophthalmic artery. The aneurysm has been excluded from circulation [Figure 3].

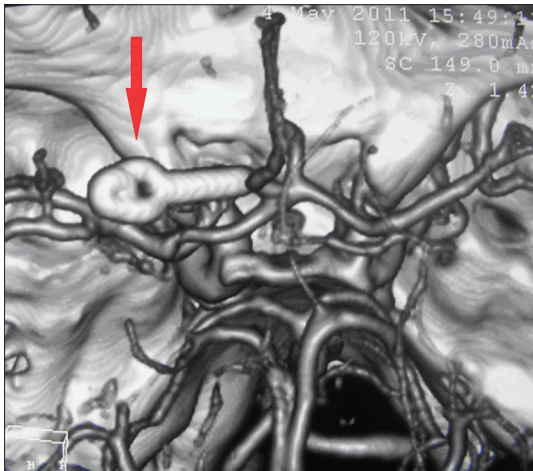
Postoperatively, the patient was in good condition with a GCS of 15 and no neurological deficits. During the postoperative course, a calcium channel blocker (nimodipine) was administered. Her vision was completely preserved. At 6 months follow up, she was assigned maximum scores of 5 and 8 on the GOS and Extended GOS (GOS-E), respectively.



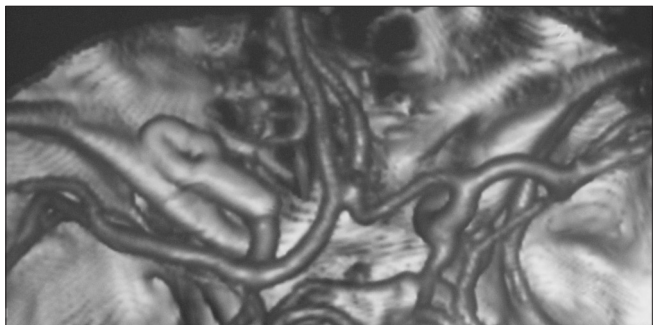
**Figure 1:** Angio-CT with 3D reconstruction showing the left ophthalmic artery aneurysm



**Figure 2:** Left ophthalmic artery aneurysm, superiorly and medially oriented. Four-vessel DSA



**Figure 3:** Postoperative angio-CT with 3D reconstruction, showing the clip in place and the integrity of vessels in the circle of Willis



**Figure 4:** Angio-CT with 3D reconstruction focusing on the anterior circulation. The state of the carotid arteries rendered angiographic access for coiling difficult

## Discussion

Ophthalmic artery aneurysms are a serious challenge, for both neurosurgeon - given their location and relation with the anterior clinoid, the fragile nature of the aneurysm and the usually broad-based neck - and interventional radiologist, given the small caliber of the vessel and the potential risk of visual disturbances.<sup>[4]</sup> Given the earlier results of surgery were quite poor, with a reported mortality up to 25%, embolization gained legitimate grounds as a safer and technically simpler technique than microsurgery. Embolization was first performed using balloons, with a mortality of up to 9%; later, the coiling technique was developed, with significantly better results.<sup>[4,6]</sup> Yet there are special conditions that make embolization impossible, like giant ophthalmic artery aneurysms, atherosclerotic, or hypoplastic ICA. In these circumstances, vascular neurosurgery interventions should be reserved for experienced neurosurgeons, especially when complications such as aneurysmal rupture appear. Special care should be exerted when employing the vascular clips, as their application should be such as it excludes only the lesion from flow, leaving the patent vessel intact. After applying a clip the surgeon should always check its positioning by simple inspection or even by opening the aneurysm. The operating microscope is an indispensable tool for these types of interventions.

The patient in this case did not present with visual disturbances because the fundus of the aneurysm was projecting superiorly and anteriorly over the clinoid process, and there was no optic nerve or chiasm compression. It was, therefore, very difficult to approach the neck of the aneurysm with the view obstructed by the fundus. The ophthalmic artery comes in close relationship with the optic nerve and in order for the nerve to be displaced medially, one should first incise the optic sheath. In order to apply the clip, we identified the ophthalmic artery posteriorly and inferiorly displaced by the neck of the aneurysm. The dissection was difficult because the segment of ICA between the emergence from the cavernous sinus and the emergence of the ophthalmic artery was very narrow. After the clinoid was drilled, this proximal portion of the ophthalmic artery, displaced by the neck of the aneurysm, became more evident. Nevertheless, the clinoid should not be extensively drilled, due to the risk of potentially severe pneumocephalus after opening some ethmoidal cells, which may require reintervention.<sup>[7,8]</sup> It is very important to have a good mobilization of the ICA by incising both the internal and the external dural rings, allowing a good visualization of the neck, otherwise when applying the clip we risk narrowing the parent vessel.<sup>[3,7]</sup>

Given the difficulties in approaching this type of aneurysms, the first treatment option is endovascular occlusion of

the aneurysm. Most cases come to the attention of the neurosurgeon following SAH, although some are big enough to compress adjacent structures, in which case the endovascular treatment must leave room for a more radical option where the dome of the aneurysm is coagulated after clipping, in order to address them both as vascular and as mass effect lesions. Our aneurysm, although large, did not cause neurological deficits so it was not opened after the clipping.

The particularities in this case - where the dimensions of the aneurysm made it an ideal candidate for embolization - were revealed precisely when this treatment was attempted. The contralateral, right ICA was hypoplastic, so one could not rely on anastomosis with the contralateral circulation, and the intensely atheromatous ipsilateral ICA prevented the radiologist to proceed with the embolization [Figure 4]. To the best of our knowledge, this is an exquisitely rare case in the literature, where a ruptured ophthalmic artery aneurysm was associated with congenital and acquired lesions on both ICAs that prevented embolization, thus making surgical clipping the only available treatment.

## Conclusion

To offer the patient the best chance for a cure, the surgical intervention for a ruptured aneurysm should be done as soon as possible, preferably in less than 48 hours from rupture. This case reports the rare occurrence of a ruptured left ophthalmic artery aneurysm, with surgically uneasy orientation, associated with a hypoplastic right ICA and an atheromatous left ICA that made embolization impossible.

## Financial support and sponsorship

Nil.

## Conflicts of interest

There are no conflicts of interest.

## References

1. Guidetti B, La Torre E. Management of carotid-ophthalmic aneurysms. *J Neurosurg* 1975;42:438-42.
2. Figueireido EG, Tavares WM, Rhoton AL, De Oliveira E. Surgical nuances of giant paraclinoid aneurysms. *Neurosurg Rev* 2010;33:27-36.
3. Giannotta SL. Ophthalmic Segment Aneurysm Surgery. *Neurosurgery* 2002;50:558-62.
4. Lefkowitz M, Giannotta SL, Hieshima G, Higashida R, Dowd C, Teitelbaum GP. Embolization of neurosurgical lesions involving the ophthalmic artery. *Neurosurgery* 1998;43:1298-303.
5. Heran NS, Song JK, Kupersmith MJ, Niimi Y, Namba K, Langer DJ, *et al.* Large ophthalmic segment aneurysms with anterior optic pathway compression: Assessment of anatomical and visual outcomes after endovascular coil therapy. *Neurosurgery* 2007;106:968-75.
6. Murayama Y, Nien YL, Duckwiler G, Gobin P, Jahan R, Frazee J, *et al.* Guglielmi detachable coil embolization of cerebral aneurysms: 11 years experience. *J Neurosurg* 2003;98:959-66.
7. Dolenc V. A combined epi- and subdural direct approach to carotid-ophthalmic artery aneurysms. *J Neurosurg* 1985;62:667-72.
8. Kinouchi H, Mizoi K, Nagamine Y, Yanagida N, Mikawa S, Suzuki A, *et al.* Anterior paraclinoid aneurysms. *J Neurosurg* 2002;96:1000-5.