

CASE REPORT

Delayed supratentorial intracerebral hemorrhage following posterior fossa surgery

Pravin Salunke, Vinod Malik, Priyamvada Kovai, Ashish Aggarwal, Niranjana K. Khandelwal¹

Departments of Neurosurgery, ¹Radiodiagnosis, PGIMER, Chandigarh, India

ABSTRACT

Delayed supratentorial intracerebral hematoma after posterior fossa surgery is uncommon. Only few cases have been reported in the past. The cause has been attributed to sitting position leading to changes in intracranial arterial and venous pressures. We report two cases of delayed intracerebral hematoma following posterior fossa surgery, none of which were operated in sitting position. MR venogram done in one patient showed venous sinus thrombosis. Intracerebral hematoma following infratentorial surgery is uncommon and is possibly due to venous sinus thrombosis leading to venous hypertension. Control of bleeding from venous sinuses due to avulsion of emissary veins during craniotomy/craniectomy possibly induces sinus thrombosis that may propagate antegrade or retrograde, leading to venous hypertension and parenchymal bleed.

Key words: Posterior fossa surgery, supratentorial intracerebral bleed, venous sinus thrombosis

Introduction

Intracerebral hemorrhage remote from operative site is fortunately a rare complication, but is associated with significant morbidity and mortality.^[1] A few cases have been reported in the past; however, the exact cause could not be located.^[1-3] Besides, only a few had delayed deterioration. We came across two cases with delayed intracerebral hematoma following posterior fossa surgery, none of which were operated in sitting position unlike the previously reported cases. We have made an attempt to find out the cause and the possible ways to prevent these complications.

Case Reports

Case 1

A 7-year-old male patient presented with progressive headache and gait ataxia for 2 months. The gag reflex was weak bilaterally though the child had no difficulty in swallowing. MRI revealed a midline posterior fossa mass, occupying the fourth ventricle, iso to hypointense on T1 and hyperintense

on T2, with marginal enhancement on contrast. This mass was causing hydrocephalus and the child underwent ventriculoperitoneal shunt followed by definitive surgery a week later. There was bleeding from the torcula which was controlled with gelfoam. The intraoperative period was otherwise uneventful. The scan done on the first postoperative day showed gross total excision and the supratentorial region showed bilateral occipital lobe oedema suggestive of venous oedema. [Figure 1a]. The child threw seizures on the 2nd postoperative day and developed right hemiparesis. Noncontrast CT of the head revealed left parietal hematoma with minimal mass effect [Figure 1b]. The shunt tube was on the right side ruling out a shunt related complication. The child responded to conservative management. Magnetic resonance venogram (MRV) was not done in this case because of technical reasons. However, he developed recurrent chest infections secondary to lower cranial nerve involvement. The child finally succumbed to chest infection 2 months later.

Case 2

Thirty-five-year-old lady presented with progressive left-sided hearing loss of 2-year duration, imbalance while walking and headache for 5 months. Physical examination showed bilateral papilledema, hypalgesia and hypesthesia in the distribution of left trigeminal nerve, reduced hearing in the left ear and an ataxic gait. Radiology revealed a left sided acoustic neurinoma, measuring 4 by 4 cm. Her past medical history was insignificant. She underwent a left retromastoid suboccipital craniectomy in supine position with head turned towards the right side. Intraoperatively, there was bleeding from the sigmoid sinus that was controlled with gelfoam and oxidized cellulose. The cerebellum was full despite opening the cisterna magna and decreasing the rotation of head did

Access this article online

Quick Response Code:



Website:

www.asianjns.org

DOI:

10.4103/1793-5482.144166

Address for correspondence:

Dr. Ashish Aggarwal, Neurosurgery, PGIMER, Chandigarh - 160 012, India. E-mail: aaggarwal_7@yahoo.com

not help. Hence, the lateral third of the cerebellum had to be resected. Near total excision of the tumor was achieved. Postoperatively the patient was extubated and she had normal sensorium. Immediate postoperative scan showed minimal blood along the falx and small specks of blood at the operative site [Figure 2]. Twelve hours later she threw a seizure following which she had decorticate posturing. Repeat CT scan showed a frontal ICH with subdural hematoma with midline shift [Figure 3]. Decompressive hemicraniotomy along with evacuation of hematoma was done. The MRI showed thrombosis of the sigmoid sinus. MRV done at this point of time

revealed transverse and sigmoid sinus thrombosis [Figure 3]. In postoperative period patient was electively ventilated. There was only a marginal improvement in her status.

Discussion

Delayed supratentorial intracerebral hemorrhage occurring after posterior fossa surgery is a rare neurosurgical complication that is often associated with significant morbidity and mortality.^[1,2] The cause of this particular complication is not clear in majority of cases.^[1] In neurosurgery, hemorrhagic abnormalities and postoperative hematomas are well-

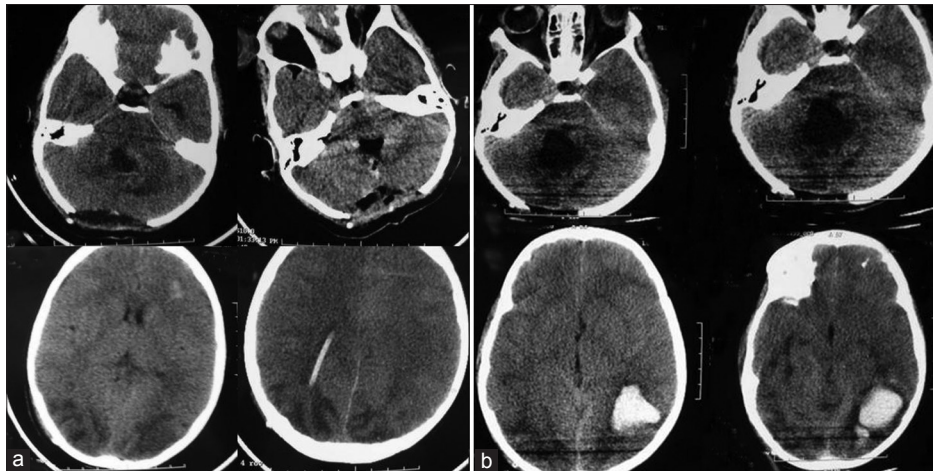


Figure 1: (a) Plain CT scan on postoperative day 1 showing total excision of tumor with no evidence of tumor bed hematoma. Bilateral occipital hypodensities are visualized suggestive of venous edema; (b) Plain CT scan on postoperative day 3 showing a left parietal hematoma

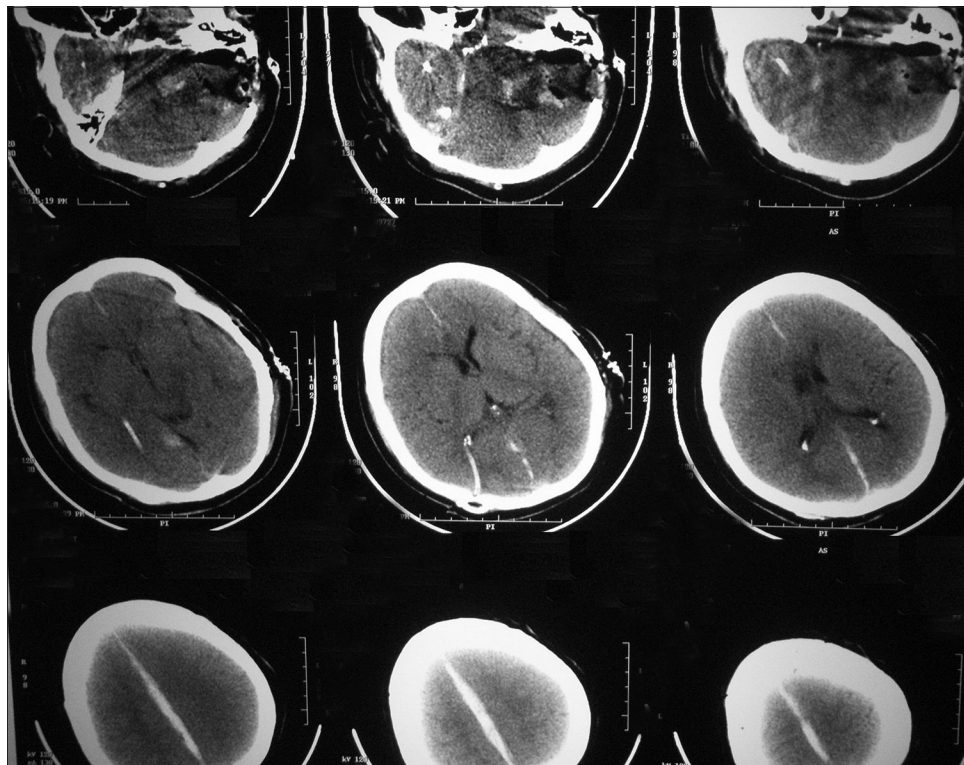


Figure 2: Immediate postoperative CT scan showing small blood specks in the tumor bed and small amount of interhemispheric fissure bleed

recognized entities with uniformly poor outcome. Operative site hematomas are common and are usually secondary to inadequate hemostasis.^[3] Supratentorial epidural and subdural hematomas following infratentorial surgery is known.^[2] However, the literature available on intracerebral hematomas following the posterior fossa surgery is sparse. We were able to locate few other reports.^[1,3-5] Table 1 summarizes these cases along with ours. Many of these patients were operated in the sitting position. The following reasons have been proposed. According to Seiler *et al.*, changes in intracranial dynamics in sitting position may cause tearing of subcortical veins leading to intracerebral bleeding. The hemorrhage may be mild to severe depending on the pressure gradient between cerebral veins and the heart; this is influenced by the position and positive end expiratory pressure used by anesthesiologists.

When the patient is repositioned after surgery, the pressure gradient is diminished or even reversed by coughing or vomiting, causing rerupture of the torn vein. As a consequence, the bleeding may occur in two stages, explaining the late deterioration in some.^[4] On the other hand, Harder and others have suggested that sitting position may reduce arterial blood flow leading to cerebral ischemia. Following surgery, when the patient is turned to normal position a hyperperfusion state may lead to hemorrhage in a relatively ischemic brain.^[2] The other two possible causes suggested by them were hypertension or disturbances in venous drainage.^[2]

Our two cases were not operated in sitting position. One was operated in supine with head turned to opposite side and the other in prone position. So the causes cited above do

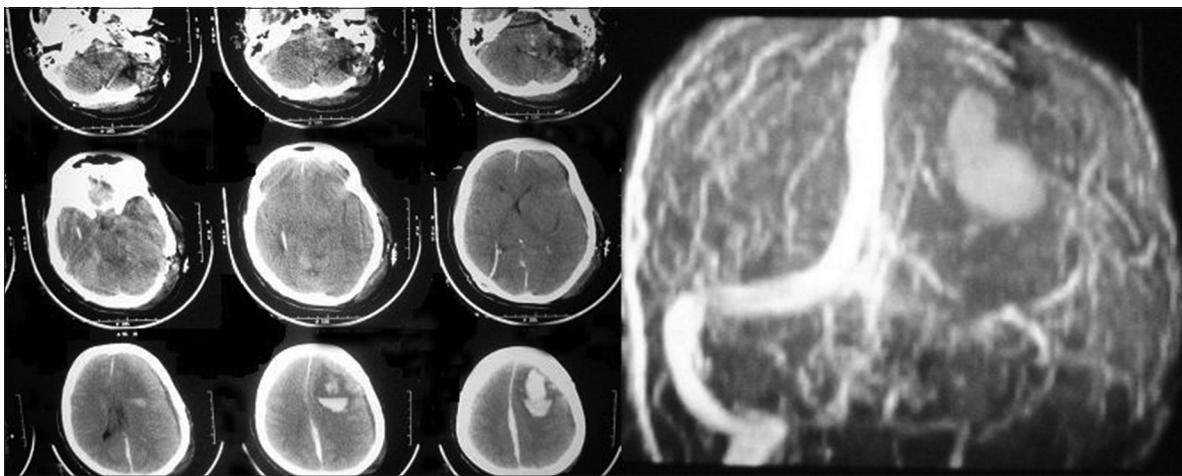


Figure 3: CT scan 12 hours postsurgery showing large left frontal hematoma. Tumor bed shows no changes as compared to immediate postoperative CT scan. Adjacent image is of MRV showing thrombosis of the transverse and sigmoid sinus

Table 1: Review of cases with intracerebral bleed following posterior fossa surgery

| Authors | Age/sex | Operative position | Location of hemorrhage | Time of presentation after surgery | Plausible cause of hemorrhage |
|---------------|---------|---------------------------------------|-------------------------|------------------------------------|---|
| Standerfer | - | Sitting | Basal ganglia | 7 days | Extracranial venous thrombosis |
| Haines | 65/F | Sitting | Right occipital | 4 hours | Could not be determined |
| Haines | 55/F | Sitting | Right basal ganglia | 45 minutes | Immediate postoperative HTN |
| Haines | 41/F | Sitting | Right fronto-parietal | Immediate | Could not be determined |
| Haines | 64/F | Sitting | Right frontal | 18 hours | Could not be determined |
| Haines | 62/F | Left Lateral | Intraventricular | Immediate | Immediate postoperative HTN |
| Harder | 44/F | Sitting head tilted | Left fronto-parietal | Not mentioned | Arterial ischemia |
| Harder | 51/F | Sitting head tilted | Bilateral frontal | Not mentioned | Arterial ischemia |
| Harder | 58/M | Sitting head tilted | Left parietal | Not mentioned | Arterial ischemia |
| Seiler | 66/F | lateral | Right parietal | immediate | Hypertension |
| Seiler | 64/F | sitting | Left parietal | 3 hours | Changes in intracerebral venous dynamics due to positioning |
| Seiler | 59/F | sitting | Right occipital | 24 hours | Changes in intracerebral venous dynamics due to positioning |
| Mahapatra | 34/F | sitting | Right parieto occipital | 24 hours | Coagulopathy |
| Mahapatra | 50/F | sitting | Left basal ganglia | Immediate | Coagulopathy |
| Present study | 40/F | Supine with head turned to right side | Left frontal hematoma | 12 hours | Venous sinus thrombosis |
| Present study | 7/M | Prone position | Left parietal hematoma | 48 hours | ?? Venous sinus thrombosis |

not explain the bleed in our patients. We got an MRV in the patient who was operated in supine position with head turned toward the opposite side after the decompressive craniectomy. It revealed sigmoid and transverse venous sinus thrombosis on the side of surgery. The thrombus was visualized in the postoperative MRI images ruling out congenital aplasia. The sinus was seen patent in the preoperative images. The sinus thrombosis itself or the propagation of the thrombus would have led to venous hypertension in the draining areas giving rise to delayed bleed. Besides left transverse sinus being dominant, its blockage increases the pressure in sagittal sinus leading bleed in its draining territory.

There is a possibility of avulsion of emissary veins from the sinuses while performing a craniectomy. The use of gelfoam or oxidized cellulose to block these holes in the sinuses might induce thrombosis that can propagate further in a retrograde or ante grade fashion. So these emissary veins have to be carefully separated from the bone, coagulated and cut well away from the sinus in order to prevent there avulsion from the venous sinuses. Inadvertent injury to venous sinus or its major tributary can have catastrophic effects. If the particular sinus is a dominant one, it calls for a thorough repair of sinus and not the patchwork. If the defect is small, oxidized cellulose is sufficient. For larger defects an attempt should be made

to repair the sinus using dural graft. This can be achieved by temporarily controlling bleed by cottonoid, drilling the surrounding bone to define the sinus rent fully and then repairing by an autologous dural patch. Regarding use of heparin, we have not used it till date but as per the comments of reviewers, it can be tried. For lesions that require exposure close to sinuses (transverse/sigmoid) the dominance of sinus should be known preoperatively by MRV.

References

1. Haines JH, Maroon JC, Jannetta PJ. Supratentorial intracerebral hemorrhage following posterior fossa surgery. *J Neurosurg* 1978;49:881-6.
2. Harders A, Gilsbach J, Weigel K. Supratentorial space occupying lesions following infratentorial surgery: Early diagnosis and treatment. *Acta Neurochir (Wien)* 1985;74:57-60.
3. Tondon A, Mahapatra AK. Supratentorial intracerebral hemorrhage following infratentorial surgery. *J Clin Neurosci* 2004;11:762-5.
4. Seiler RW, Zurbrugg HR. Supratentorial intracerebral hemorrhage after posterior fossa operation. *Neurosurgery* 1986;18:472-3.
5. Standefer M, Bay JW, Trusso R. The sitting position in neurosurgery: A retrospective analysis of 488 cases. *Neurosurgery* 1984;14:649-58.

How to cite this article: Salunke P, Malik V, Kovai P, Aggarwal A, Khandelwal NK. Delayed supratentorial intracerebral hemorrhage following posterior fossa surgery. *Asian J Neurosurg* 2016;11:315.

Source of Support: Nil, **Conflict of Interest:** None declared.