

## CASE REPORT

# Medullomyoblastoma: A rare case in an unusual location in an atypical age group

Sumit Bansal, Sachin A. Borkar, Ashish Suri, Mehar C. Sharma<sup>1</sup>, Ashok K. MahapatraDepartments of Neurosurgery and <sup>1</sup>Neuropathology, All India Institute of Medical Sciences, New Delhi, India

## ABSTRACT

Medullomyoblastoma is a variant of medulloblastoma with an aggressive course. It is typically seen in children less than 10 years of age and usually arises from the cerebellar vermis. Authors report an unusual case of medullomyoblastoma arising from the right middle cerebellar peduncle in an adult patient and pertinent literature is reviewed regarding this uncommon entity.

**Key words:** cerebellar peduncle, medulloblastoma, medullomyoblastoma, posterior fossa tumors

## Introduction

Medullomyoblastoma (MMB) was first described by Marinesco and Goldstein in 1933,<sup>[1]</sup> is a unique variant of medulloblastoma with more aggressive nature.<sup>[2]</sup> Typical affected age group is less than 10 years of age with occasional case reports in adults. Majority of patients present with symptoms of increased intracranial pressure.<sup>[2]</sup> Tumor is classified as WHO grade IV and is defined histopathologically as a combination of primitive neuroectodermal and myoblastic elements.<sup>[3]</sup> Authors report a rare case of medullomyoblastoma arising from the middle cerebellar peduncle in an adult patient.

## Case Report

### Clinical history

A 32-years-old male presented with two months history of gait ataxia. On examination right hemiparesis (4/5, MRC grading), left VII nerve paresis (H and B grade III) and right cerebellar signs were present. Rest of the neurological examination was normal.

### Imaging

Head CT revealed a heterogeneous solid cystic mass arising from the brainstem and extending to right cerebello-pontine angle

[Figure 1a]. MRI revealed a right middle cerebellar peduncle lesion (33 × 30 × 28 mm) extending to right cerebello-pontine angle with necrotic and hemorrhagic areas. The lesion was isointense on T1W, hyper intense on T2W with inhomogeneous postcontrast enhancement [Figures 1b-d]. There was mild mass effect over fourth ventricle, but no upstream hydrocephalus.

### Operative procedure

Right retro-sigmoid suboccipital craniotomy and near total excision of tumor was done. Intraoperatively, tumor was soft, greyish, highly vascular arising from the right middle cerebellar peduncle, infiltrating surrounding neurovascular structures, without any plane of cleavage.

### Postoperative course

Patient was electively ventilated for 48 hours. Postoperative course was uneventful except for mild impairment of gag reflex, for which nasogastric feeding was started. Patient was discharged on 7<sup>th</sup> postoperative day.

### Histopathological examination

The tumor tissue was fixed in neutral-buffered formalin and was routinely processed and paraffin embedded. Five-micrometer sections were cut for routine Hematoxylin and eosin staining and for immunohistochemistry.

Microscopic examination showed a malignant tumor arranged in sheets comprising of round to oval to spindle cells with scant amount of cytoplasm and vesicular nuclei with prominent nucleoli. Mitoses were frequent [Figure 2a]. Some of the cells had more eosinophilic cytoplasm. The tumor cells showed diffuse immunopositivity for synaptophysin, chromogranin and focal immunopositivity for desmin and myogenin [Figures 2b-d]. MIB-1 labeling index was 6%. The tumor cells were immunonegative for p53, GFAP, epithelial membrane antigen (EMA), pancytokeratin (CK) and TTF-1.

### Access this article online

#### Quick Response Code:



#### Website:

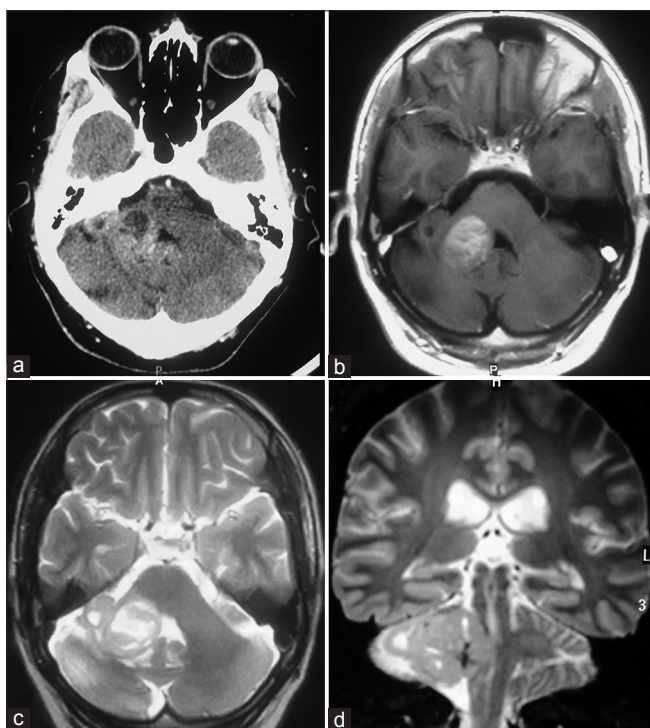
www.asianjns.org

#### DOI:

10.4103/1793-5482.144167

### Address for correspondence:

Dr. Ashish Suri, Additional Professor, Room No. 712, Department of Neurosurgery, Neurosciences Center, All India Institute of Medical Sciences, New Delhi - 110 029, India. E-mail: surineuro@gmail.com



**Figure 1:** Head CT scan showing hyperdense lesion in right cerebello-pontine angle (a); T1-W axial postcontrast MRI (b); T2-W axial MRI (c) and T2-W coronal MRI (d) Images showing contrast enhancing mass in right middle cerebellar peduncle with cerebello pontine angle extension

Based on above morphological and immunohistochemical features the possibility of medulloblastoma was considered.

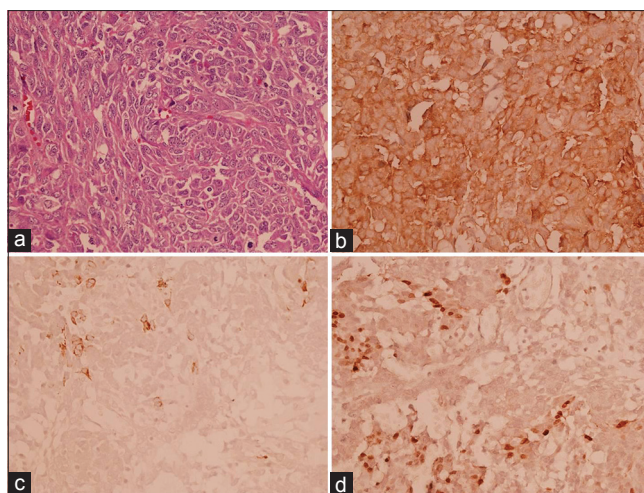
### Follow-up

At last follow-up, his lower cranial nerve function had improved and he was able to take food orally. MRI done 6 weeks after surgery showed no evidence of residual/recurrent tumor [Figure 3]. Patient is now undergoing radiotherapy.

### Discussion

Medulloblastoma is a unique variant of medulloblastoma with more aggressive nature.<sup>[1,2]</sup> As per the authors' literature review, of the patients previously described in the literature, approximately 90% were less than 10 years of age. To the best of authors' knowledge, only five cases of adult medulloblastoma have been described in literature till date<sup>[2,4-7]</sup> [Table 1]. Usual location is in the vermis and less often in the cerebellar hemispheres.<sup>[8]</sup>

MMB is considered to be a variant of medulloblastoma; however, the cell of origin of the myogenic component is controversial.<sup>[8]</sup> Ingraham and Bailey<sup>[9]</sup> and Misugi *et al.*<sup>[10]</sup> postulated it to be a variant of malignant teratoma consisting of a neuroectodermal and mesenchymal rhabdomyosarcomatous component. Banerjee and Kak<sup>[11]</sup> favored this hypothesis as they observed an epithelial component resembling medulloepithelioma in MMB. Chowdhary *et al.*<sup>[12]</sup> reported three cases of MMB with distinct



**Figure 2:** Photomicrographs showing sheets of oval to spindle-shaped cells with scant to moderate amount of cytoplasm, vesicular nuclei with prominent nucleoli and frequent mitoses (a, H and E, x400). Tumor cells are diffusely immunopositive for synaptophysin; (b) and focally for desmin and myogenin (c and d, x400 each)

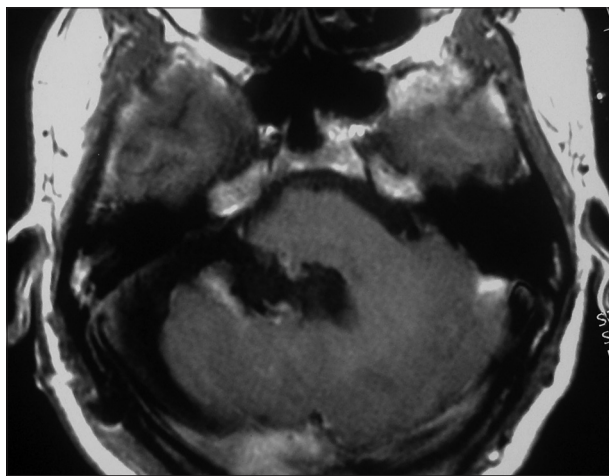
teratomatous areas supporting the theory of a teratomatous origin. Russell and Rubinstein<sup>[13]</sup> suggested that MMB is derived from the primitive germinal cells located in the midline of the posterior lip of the fourth ventricle in early fetal life and hence these tumors are preferentially located in the midline. Mahapatra *et al.*<sup>[5]</sup> demonstrated the presence of derivatives of all the three germ layers in MMB supporting the possibility of a teratomatous origin. Lewis *et al.*<sup>[14]</sup> and Willis<sup>[15]</sup> suggested that the myoblastic component of MMB originates from the highly plastic embryonic pluripotent mesenchymal cells derived from the neural crest surrounding the blood vessels in the brain and meninges. This was supported by Kartha *et al.*<sup>[16]</sup> who reported occasional striated muscle in the leptomeninges of the ventral pons in stillborn preterm babies. Marinesco and Goldstein<sup>[1]</sup> suggested that the striated muscles in MMB are derived from metaplastic vascular smooth muscle cells. Walter *et al.*<sup>[17]</sup> postulated that the myoblast originates from neoplastic transformation of the endothelial lining of the capillaries, which are mesodermal in origin. This is supported by the finding that muscle fibres in MMB are preferentially situated around the blood vessels. Furthermore, mitotic figures are seen in these endothelial cells. Lennon *et al.*<sup>[18]</sup> postulated that primitive neuroepithelial cells can differentiate into rhabdomyoblastic or melanocytic lines. Lantos *et al.*<sup>[8]</sup> reported a hamartomatous component in MMB, consistent with the theory that MMB may derive from dysplastic elements of the adjacent cerebellum.

Medulloblastoma is a rare cerebellar tumor<sup>[11,12,19,20]</sup> with histological characteristics of medulloblastoma within which smooth and striated muscle fibers are found. The muscle elements usually present a malignant appearance.

Overall, medulloblastoma is rapidly progressive, seen in young children with clinical symptoms ranging from a few

**Table 1: Summary of reported cases of adult medulloblastoma in literature**

Author	Age(years)/sex	Duration of symptoms	Clinical features	CT findings	Surgery	Adjuncts	Outcome
Helton <i>et al.</i> <sup>[2]</sup>	7.3 years at diagnosis, male (follow-up to age of 25 years is available)	2 months	Raised ICP	Mass in cerebellar vermis with mild hydrocephalus	Gross total resection	Craniospinal radiation+ chemotherapy	No active disease at last follow-up
Sachdeva <i>et al.</i> <sup>[7]</sup>	28, male	14 days	Raised ICP	Cerebellar mass	Gross total resection	Craniospinal radiation+ chemotherapy	Lost to follow-up
Rao <i>et al.</i> <sup>[6]</sup>	40, male	3 months	Raised ICP	Vermian mass	Near total resection	None	Accidental self-extubation with in hospital death on 21st post-op day
Mahapatra <i>et al.</i> <sup>[5]</sup>	24, female	6 months	Raised ICP, bilateral cerebellar signs, Right-sided lower cranial nerve palsies	Midline posterior fossa tumor extending to CP angle with gross hydrocephalus	VP shunt, near total tumor excision(brain stem infiltrated)	Craniospinal radiation, chemotherapy	Well for 2 years; local recurrence; expired within 3 years of treatment
Fatih <i>et al.</i> <sup>[4]</sup>	31, female	2 months	Raised ICP, right cerebellar signs	right cerebellar hemispheric mass, extending through the supratentorial area via the tentorium	Gross total resection	none	Recurrence within 2 months
Present case	32, male	2 months	Right hemi paresis with right cerebellar signs	right middle cerebellar peduncle lesion extending to right CP angle, no hydrocephalus, no evidence of spinal seeding	Near total excision	Cranial radiation	Under follow-up

**Figure 3:** Postcontrast T1-W axial MRI image showing complete excision of tumor in follow-up

weeks to months.<sup>[6]</sup> The recommended treatment includes radical surgery and craniospinal irradiation.<sup>[12-14,20]</sup> However, the survival period is very short despite surgery and radiation and has ranged from 4 days to 1 year.<sup>[6]</sup> Nevertheless, radiation does seem to prolong the period of survival.<sup>[21]</sup> Jaiswal *et al.*<sup>[21]</sup> reported a case of MMB with long survival after gross total resection along with craniospinal radiation and chemotherapy.

## Conclusions

Medulloblastoma, an aggressive variant of medulloblastoma, usually seen in children less than 10 years of age, presenting in an adult is extremely rare. Histologically the tumors have a combination of different components. Despite multimodality treatment, the overall outcome is poor.

## References

1. Marinesco G, Goldstein M. Sur une forme anatomique, non encore decrite, de medulloblastoma, medulloblastoma. *Ann Anat Pathol* 1933;10:513-5.
2. Helton KJ, Fouladi M, Boop FA, Perry A, Dalton J, Kun L, *et al.* Medulloblastoma: A radiographic and clinicopathologic analysis of six cases and review of the literature. *Cancer* 2004;101:1445-54.
3. Lindberg E, Persson A, Ora I, Mertens F, Englund E, Gisselsson D. Concurrent gain of 17q and the MYC oncogene in a medulloblastoma. *Neuropathology* 2007;27:556-60.
4. Fatih B, Selçuk P, Özlem Y, Necmettin P. An adult case of medulloblastoma extending to the supratentorial area. *Sinir Sistemi Cerrahisi Derg* 2008;1:126-9.
5. Mahapatra AK, Sinha AK, Sharma MC. Medulloblastoma: A rare cerebellar tumour in children. *Childs Nerv Syst* 1998;14:312-6.
6. Rao C, Friedlander ME, Klein E, Anzil AP, Sher JH. Medulloblastoma in an adult. *Cancer* 1990;65:157-63.
7. Sachdeva M, Vankalakunti M, Rangan A, Radotra BD, Chhabra R, Vasishta RK. The role of immunohistochemistry in

- medullomyoblastoma-A case series highlighting divergent differentiation. *Diagn Pathol* 2008; 3:18.
8. Lantos PL, Vendenberg SR, Kleihues P. Tumours of the nervous system. In: Graham DI, Lantos PL, editors. *Greenfield's Neuropathology*. Sixth ed. Cambridge: Edward Arnold; 1997. p. 706-7.
  9. Ingraham FD, Bailey OT. Cystic teratomas and teratoid tumour of the central nervous system in infancy and childhood. *J Neurosurg* 1946;3:511-32.
  10. Misugi K, Liss L. Medulloblastoma with cross striated muscle: A fine structural study. *Cancer* 1970;25:1279-85.
  11. Banerjee AK, Kak VK. Teratoid tumour the cerebellum. *J Pathol* 1973;111:285-7.
  12. Chowdhury C, Roy S, Mahapatra AK, Bhatia R. Medulloblastoma: A teratoma. *Cancer* 1985;55:1495-500.
  13. Russell DS, Rubinstein LJ. Pathology of the tumours of the nervous system. Fourth ed. London: Edward Arnold; 1977. p. 26-7.
  14. Lewis AJ. Medulloblastoma with striated muscle fiber: Case report. *J Neurosurg* 1973;38:642-6.
  15. Willis RA. Pathology of tumours of children. Edinburgh London: Oliver and Boyd; 1962. p. 67-75.
  16. Kartha C, Shankar SK, Roy S. Skeletal muscle in the leptomeninges. *Neurol India* 1980;28:74-6.
  17. Walter GF, Brucher JM. Ultra structural study of medullomyoblastoma. *Acta Neuropathol (Berl)* 1979;48:211-4.
  18. Lenon VA, Patterson S. Neuroectoderm markers retained in phenotypical skeletal muscle cells arising from a glial cell line. *Nature* 1979;281:586-8.
  19. Bojin PJ, Ebels E. A case of medullomyoblastoma. *Acta Neuropathol (Berl)* 1963;2:309-11.
  20. Smith TW, Davidson RI. Medullomyoblastoma: A histologic, immunohistochemical and ultra structural study. *Cancer* 1984;54:323-32.
  21. Jaiswal AK, Jaiswal S, Mahapatra AK, Sharma MC. Unusually long survival in a case of medullomyoblastoma. *J Clin Neurosci* 2005;12:961-3.

**How to cite this article:** Bansal S, Borkar SA, Suri A, Sharma MC, Mahapatra AK. Medullomyoblastoma: A rare case in an unusual location in an atypical age group. *Asian J Neurosurg* 2016;11:315-6.

**Source of Support:** Nil, **Conflict of Interest:** None declared.