

## CASE REPORT

# Lethal penetrating stab injury to the vertebral artery: A case report with review of literature

Avijit Sarkari, Pankaj K. Singh, Ashok K. Mahapatra

Department of Neurosurgery, JPN Apex Trauma Centre, All India Institute of Medical Sciences, New Delhi, India

## ABSTRACT

The vertebral arteries are rarely injured in penetrating neck trauma due to their deep location in the foramen transversarium. These injuries in isolation are not associated with neurological deficits or ischemic changes on radiology as the collaterals are usually sufficient. We report a case of fatal unilateral vertebral artery stab injury leading to bilateral cerebellar and brainstem infarction. The carotid Doppler ruled out the presence of any carotid artery injury. Life-threatening injuries are possible in the presence of hypoplastic contralateral vertebral artery or inadequate flow from the anterior circulation not making up for the deficit. This emphasizes that thorough evaluation and timely management of suspected injuries to even a single vertebral artery should be undertaken.

**Key words:** Brainstem injury, stab wound, stroke, vertebral artery injury

## Introduction

Penetrating injuries of the vertebral artery are a rare phenomenon mainly because of the deep location of the vessel in the bony canal. Injury of this vessel has not been associated with neurological deficits. The collaterals are usually sufficient to not cause an ischemic stroke.<sup>[1]</sup> A majority are clinically silent or have a late presentation as arteriovenous fistula, false aneurysms, or neurological deficits. However, a case of cerebellar infarction has been reported.<sup>[2]</sup> We report a rare case of isolated penetrating stab injury to vertebral artery that expired due to cerebellar and brainstem infarction. This emphasizes that thorough evaluation and timely management of suspected injuries to even a single vertebral artery should be undertaken.

## Case Report

A 40-year-old male was brought to casualty with history of getting stabbed in the right side of neck from behind

with a large household knife. The patient reached casualty almost 24 h after the incidence in an exsanguinated condition with BP 80/52 and gasping respiratory efforts. The patient was quadriplegic with a GCS of E2 V1 M5. The patient was immediately intubated and vasopressors were started. A puncture wound was present in zone II area on the right side of neck over the sternocleidomastoid. There was no active bleed from the neck wound. Both carotids were palpable and a Doppler evaluation of neck vessels showed flow in both carotids. After stabilization, the patient was shifted to CT room. NCCT head showed infarct of bilateral cerebellar hemispheres and the brainstem [Figure 1]. NCCT cervical spine showed fracture of right foramen transversarium and right lamina of C6 vertebra [Figure 2]. CT angiography was planned but the patient had a cardiac arrest in the CT room from which he was revived and immediately taken to ICU. He expired after 12 h.

## Discussion

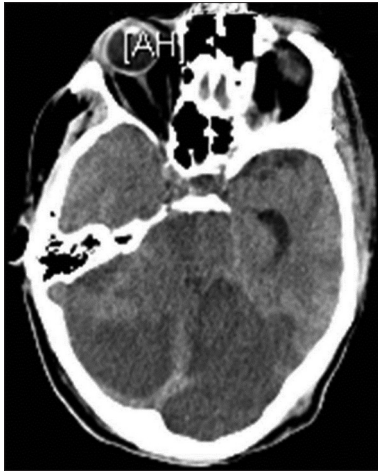In penetrating trauma, the most commonly injured structures in the neck are the vessels, followed by the spinal cord, the aerodigestive tracts, and nerves. Overall, zone II is the most commonly injured area (47%), followed by zone III (19%) and zone I (18%). In 16% of cases, there is involvement of more than one zone.<sup>[3]</sup> In cases with predominantly stab wounds, zone I is the most commonly injured area (44%), followed by zone II (29%) and zone III (27%).<sup>[3]</sup> Most stab wounds involve the left side of the neck (74% of cases), presumably due to the predominance of right-handed assailants.<sup>[3]</sup>

The reported incidence of vertebral artery injury in penetrating neck trauma varies from 1% to 7.4% which depends on the

Access this article online	
Quick Response Code:	Website: www.asianjns.org
	DOI: 10.4103/1793-5482.144192

### Address for correspondence:

Dr. Pankaj Kumar Singh, Room No 720, Department of Neurosurgery, All India Institute of Medical Sciences, Ansari Nagar, New Delhi - 110 029, India. E-mail: drpankajsingh11@gmail.com



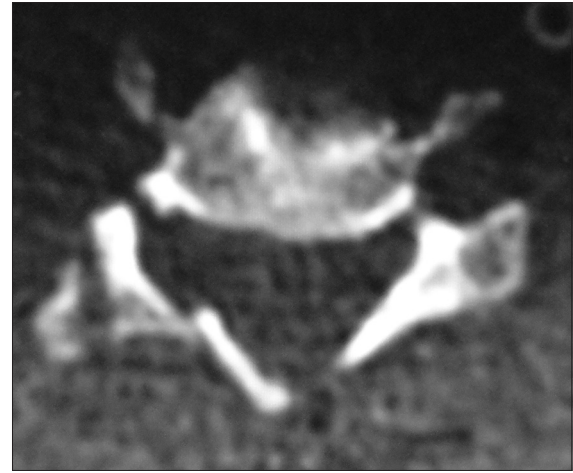
**Figure 1:** Bilateral cerebellar hemispheric and brainstem infarction

wounding mechanism.<sup>[4]</sup> The most common mechanism of penetrating injury is gunshot wounds, followed by stab wounds. Firearms are responsible for approximately 44%, stab wounds for approximately 40%, shotguns for approximately 4%, and other weapons for approximately 12% of all penetrating neck injuries.<sup>[3]</sup> Gunshot wounds were 3 times more likely to cause a large hematoma than stab wounds (20.6% vs. 6.7%), 2 times as likely to be associated with hypotension on admission (13.4% vs. 7.9%), 2 times as likely to result in a vascular injury (26.8% vs. 14.6%), and 13 times as likely to cause spinal cord injury (13.4% vs. 1.1%).

The injuries of the vertebral artery are far less common than those of the extracranial carotid arteries because of its protected anatomic location.<sup>[5]</sup> Injuries from stab wounds are much less common in all major studies.<sup>[3-5]</sup>

Vertebral artery injuries in hemodynamically and clinically stable patients are usually diagnosed at angiography, which together with embolization is a valuable option for both diagnosis and treatment.<sup>[6]</sup> This invasive method enabling the documentation of the exact injured site, the nature of the lesion and knowledge about the collateral cerebral circulation, remains the gold standard. Angiography combined with embolization may be used for both proximal and distal control of the bleeding and for false aneurysms and arteriovenous fistulas. However, routine angiography in asymptomatic patients is unnecessary, has a low yield, and does not offer any benefit over physical examination and other noninvasive investigations.<sup>[7]</sup>

Color flow Doppler in combination with careful clinical examination has been suggested as a reliable alternative to angiography.<sup>[3,8]</sup> It has the disadvantage of being operator-dependent and has some limitations in the visualization of the proximal left subclavian artery, especially in obese patients, the internal carotid artery near the base of the skull, and the segments of the vertebral artery under the bony part of the vertebral canal.<sup>[9]</sup>



**Figure 2:** Fractured right foramen transversarium, pedicle, and lamina of C6 vertebra due to penetrating stab injury

Helical CT angiography has shown very encouraging results comparable to the conventional angiography and has become an excellent initial investigation for suspected vascular injuries.<sup>[10]</sup> It has some limitations due to artifacts from metallic fragments or excessive air in the soft tissues. In these cases conventional angiography may be necessary for accurate evaluation.

In the presence of active bleeding from penetrating neck wounds, the patient should be placed in the Trendelenburg position to reduce the risk of air embolism in cases with venous injuries. Bleeding from the vessels behind the clavicle or near the base of the skull or the vertebral artery is often difficult to control by external pressure. In these cases, digital compression with a gloved index finger through the wound should be attempted. Balloon tamponade with a Foley catheter has been successfully used. In a situation with an actively bleeding vertebral artery with difficult vascular control, damage control surgery in the neck with packing is an option if bleeding can be controlled in this manner.<sup>[1,2]</sup> The collaterals are usually sufficient not to cause an ischemic stroke.

The reported case is a rare incidence of a lethal penetrating stab injury of unilateral vertebral artery causing neurological deficit, brainstem, and bilateral cerebellar infarct.

## **Conclusion**

Stab injuries of neck causing vertebral artery injuries are rare and are usually clinically silent with no neurological deficits and can be managed for bleeding by simple packing, interventional radiology, or other surgical techniques without causing ischemic stroke. However, the presence of adequate collateral blood flow is essential for above generalizations. Life-threatening injuries are possible in the presence of hypoplastic contralateral vertebral artery or inadequate flow from the anterior circulation not making up for the deficit.

## References

1. Firoozmand E, Velmahos GC. Extending damage-control principles to the neck. *J Trauma* 2000;48:541-3.
2. Parka JJ, Shima HS, Jeonga JH, Whangb SH, Kima JP, Jeona SY, *et al.* A case of cerebellar infarction caused by vertebral artery injury from a stab wound to the neck. *Auris Nasus Larynx* 2007;34:431-43.
3. Demetriades D, Theodorou D, Cornwell E, Berne TV, Asensio J, Belzberg H, *et al.* Evaluation of penetrating injuries of the neck: Prospective study of 223 patients. *World J Surg* 1997;21:41-8.
4. Roberts LH, Demetriades D. Vertebral artery injuries. *Surg Clin North Am* 2001;81:1345-56.
5. Pearce WH, Whitehill TA. Carotid and vertebral arterial injuries. *Surg Clin North Am* 1988;68:705-23.
6. Demetriades D, Theodorou D, Asensio J, Golshani S, Belzberg H, Yellin A, *et al.* Management options in vertebral artery injuries. *Br J Surg* 1996;83:83-6.
7. Eddy VA. Is routine arteriography mandatory for penetrating injury to zone I of the neck? Zone I Penetrating Neck Injury Study Group. *J Trauma* 2000;48:208-13.
8. Corr P, Abdool CA, Robbs J. Colour-flow ultrasound in the detection of penetrating vascular injuries of the neck. *S Afr Med J* 1999;899:644-6.
9. Montalvo BM, Leblang SD, Nunez DB Jr, Ginzburg E, Klose KJ, Becerra JL, *et al.* Color Doppler sonography in penetrating injuries of the neck. *AJNR Am J Neuroradiol* 1996;17:943-51.
10. Munera F, Soto JA, Palacio D, Velez SM, Medina E. Diagnosis of arterial injuries caused by penetrating trauma to the neck: Comparison of helical CT angiography and conventional angiography. *Radiology* 2000;216:356-62.

**How to cite this article:** Sarkari A, Singh PK, Mahapatra AK. Lethal penetrating stab injury to the vertebral artery: A case report with review of literature. *Asian J Neurosurg* 2016;11:317.

**Source of Support:** Nil, **Conflict of Interest:** None declared.