

## CASE REPORT

# Solitary plasmacytoma of temporal bone: A rare case report

 Ritesh Kumar, Narendra Kumar, Sandeep Mohindro<sup>1</sup>, B. D. Radotra<sup>2</sup>

 Departments of Radiotherapy and Oncology, <sup>1</sup>Neurosurgery and <sup>2</sup>Pathology, Postgraduate Institute of Medical Education and Research, Chandigarh, India

## ABSTRACT

Solitary plasmacytoma of base of skull is a rare disease. It presents with headache, swelling, and other vague symptoms. Systemic work-up to rule out multiple myeloma is necessary. Radiotherapy is the treatment of choice. We, here, present a case of solitary plasmacytoma of base of skull in right temporal bone in a 50-year-old female treated with surgery and radiotherapy.

**Key words:** Plasmacytoma, radiotherapy, temporal

## Introduction

Solitary bone plasmacytoma (SBP) is characterized by malignant proliferation of monoclonal plasma cells, constituting less than 5% of malignant plasma cell tumors.<sup>[1]</sup> SBP of temporal bone is extremely rare, and only a few case reports are mentioned in the English literature.<sup>[2-5]</sup> The standard recommended management is localized radiotherapy (RT). We, here, present a case of solitary plasmacytoma of right temporal bone in a 50-year-old female treated with surgery and RT.

## Case Report

A 50-year-old female patient presented in August 2010 with the complaints of right sided headache for three months, which was dull aching in character and was not associated with vomiting or visual disturbance. She had no history of seizures, sensory, or motor complaints. She was hypertensive for eight years and on regular antihypertensive medications. No other significant co-morbidities were present. On examination, there was a 4 × 3 cm diffuse swelling over right temporal region felt by deep palpation. Systemic and neurological examination was

within normal limits. Magnetic resonance imaging (MRI) brain showed an expansile osseous lesion (32 × 16 mm) seen along the floor of posterior cranial fossa, predominantly involving the posterior portion of right petrous temporal bone [Figure 1]. The mass was isointense to hyperintense on T1, isointense on T2 and showed homogeneous contrast enhancement. Computed tomography (CT) – temporal bone showed a locally destructive lesion involving the right mastoid air cells with complete disruption of the middle and inner ear anatomy and marked erosion of the affected bone [Figure 2]. In addition, there was contiguous involvement of the right lateral aspect of the foramen magnum and right occipital bone with associated soft tissue component. The lesion was causing erosion of the sinus and dural plates of the temporal bone with infratemporal extension of the disease process. Internal auditory canal was normal. Left temporal bone was normal. Both TM joints, carotid canal, jugular foraminae, round and oval were normal. She underwent right retromastoid suboccipital craniotomy and a biopsy with subtotal excision of bony tumor was done in September 2010. Post-operative recovery was uneventful. Histopathology revealed plasmacytoma with immunohistochemistry positive for CD 138 [Figures 3 and 4]. Further investigative work-up was done to rule out multiple myeloma. Hemoglobin, total leukocyte count, and differential counts were normal. Renal function tests and liver function

Access this article online	
Quick Response Code:	Website: www.asianjns.org
	DOI: 10.4103/1793-5482.144193

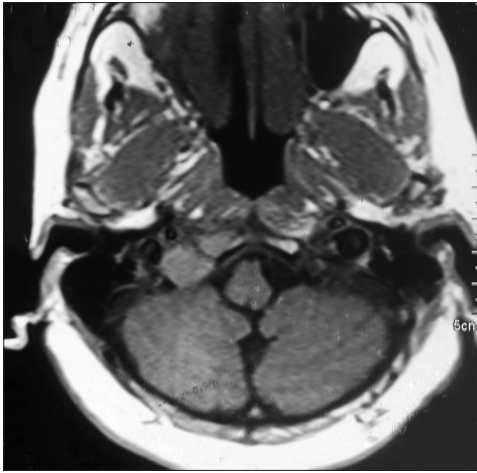
### Address for correspondence:

Dr. Ritesh Kumar, Department of Radiotherapy and Regional Cancer Centre, Postgraduate Institute of Medical Education and Research, Chandigarh, India. E-mail: riteshkr9@gmail.com

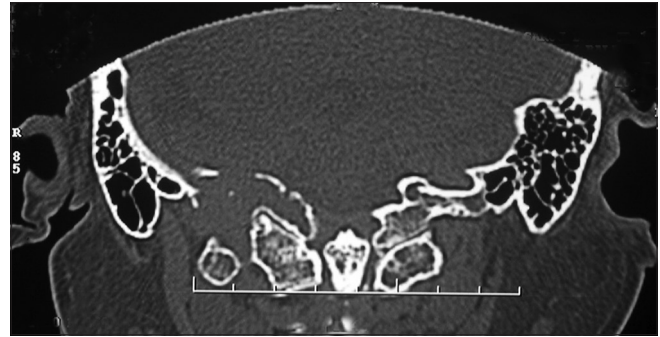
This is an open access article distributed under the terms of the Creative Commons Attribution-NonCommercial-ShareAlike 3.0 License, which allows others to remix, tweak, and build upon the work non-commercially, as long as the author is credited and the new creations are licensed under the identical terms.

**For reprints contact:** reprints@medknow.com

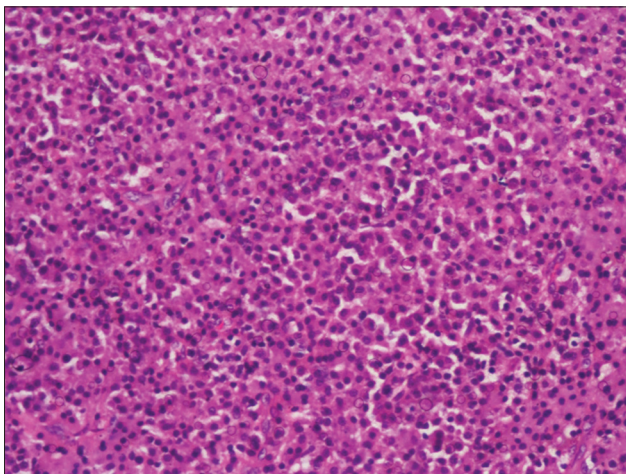
**How to cite this article:** Kumar R, Kumar N, Mohindro S, Radotra BD. Solitary plasmacytoma of temporal bone: A rare case report. Asian J Neurosurg 2017;12:95-7.



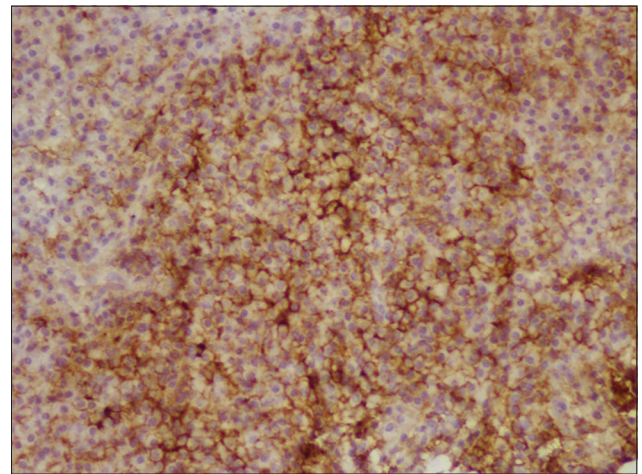
**Figure 1:** MRI showing expansile osseous lesion seen along the floor of posterior cranial fossa involving the posterior portion of right petrous temporal bone



**Figure 2:** CT—Temporal bone showing locally destructive lesion involving the right mastoid air cells with disruption and erosion of the right temporal bone



**Figure 3:** Microphotograph showing diffuse sheets of plasma cells. (Hematoxyline and Eosin stain)



**Figure 4:** Immunohistochemistry for CD 138 showing strong positivity in tumor cells

tests were normal. Skeletal survey did not reveal any other lytic lesion. Bone marrow aspiration and biopsy was unremarkable with only 3% plasma cells. Serum electrophoresis and urine electrophoresis did not show any M-protein. Thus, the final diagnosis made was solitary plasmacytoma of right temporal bone. She received external beam radiotherapy to the tumor site with a 2 cm margin at the dose of 50 Gy in 25 fractions in five weeks. Treatment was well tolerated, with only Grade II skin reaction. Further, she was kept on regular follow-up. Her last follow-up visit was in February 2012, and she was radiologically, clinically, and immunologically disease free.

## Discussion

Solitary bone plasmacytoma (SBP) is a rare malignancy and is characterized by malignant proliferation of monoclonal plasma cells. SBP constitutes less than 5% of malignant plasma cell tumors.<sup>[1]</sup> It is more common in males as compared to females (3:1) and median age of presentation is 55 years.<sup>[1]</sup> SBP of skull

is rare and the SBP of temporal bone is rarely mentioned in the literature with only a few case reports.<sup>[2-5]</sup>

These tumors most commonly occur as an expansile lytic mass and are localized in the spine twice as often as other bony sites.<sup>[6]</sup> The commonest presenting symptom is pain. More than 75% patients with apparent SBP progress to myeloma, with a median duration of two to three years and this proportion increases with passage of time.<sup>[1,7]</sup> Thus, patients with SBP require careful lifelong monitoring to detect progression to MM with routine assessment of symptoms and signs in conjunction with laboratory investigations. The median overall survival ranges from 7.5 to 12 years.<sup>[1]</sup>

The optimal treatment for most patients with SBP is moderate dose RT, approximately 40–50 Gy administered once daily at 1.8–2.0 Gy per fraction in a continuous course resulting in high local control rates of 83–96%.<sup>[7-11]</sup> The RT technique has evolved over the years, and it is not necessary to irradiate the entire medullary cavity of the bone in patients with SBP; rather, the lesion is treated with a more limited field with a 2–3 cm margin on the gross disease.<sup>[12,13]</sup> Mendenhall *et al.* recommended a minimum dose of 40 Gy after a dose–response analysis based

on review of literature including 81 patients. They reported a 6% local failure rate in patients with SBP treated with doses of 40 Gy or above in contrast to 31% for doses below 40 Gy.<sup>[14]</sup> Tsang *et al.* reported their experience of 32 patients with SBP treated with RT and concluded that tumor bulk was the most significant factor influencing local control and suggested that bulky SBP over 5 cm require higher dose or perhaps combined modality treatment for effective local control.<sup>[11]</sup> Our patient was a non-bulky solitary plasmacytoma of right temporal bone and was treated with RT dose of 50 Gy at 2 Gy per fraction.

The role of adjuvant chemotherapy is not clearly defined.<sup>[8,9,15]</sup> The addition of chemotherapy to radiotherapy in the treatment of SBP might, however, help in improving local control and preventing or delaying progression to MM, but there are insufficient data to support this recommendation.<sup>[16]</sup>

The role of surgery is limited in SBP and is indicated in cases with surgical instability or neurological compromise.<sup>[12,13]</sup> Our patient underwent surgery in form of subtotal excision or biopsy as pre-operative biopsy was not done in this case. However, the recommendation till date is that role of surgery is limited to biopsy only unless indicated.

Factors predicting progression to myeloma includes tumor size >5 cm, age  $\geq 60$  years, high M protein levels (1 g/dL), persistence of M protein after treatment and spine lesions.<sup>[11,17-19]</sup> None of the factors were present in the index case, and thus the long term chances of progression to multiple myeloma are less in the index case.

Assessment of response after local treatment with radiotherapy includes estimation of monoclonal protein levels, resolution or progression of symptoms and evidence of new lesions on imaging. The monoclonal protein was not detectable in the index case in her serum or urine at presentation and during follow-up. After a follow-up period of around one year, she is symptom free and has no clinical, radiological, or immunological evidence of disease. But she requires continuous further follow-up for early detection and treatment of any systemic relapse of disease. This is a rare case of SBP of temporal bone treated with involved field localized RT and will further aid in the awareness, diagnosis, and management of this rare diagnosis.

### Financial support and sponsorship

Nil.

### Conflicts of interest

There are no conflicts of interest.

## References

1. Dimopoulos MA, Mouloupoulos LA, Maniatis A, Alexanian R. Solitary plasmacytoma of bone and asymptomatic multiple myeloma. *Blood* 2000;96:2037-44.
2. Chiang SK, Canalis RF, Ishiyama A, Eversole LR, Becker DP. Plasmacytoma of the temporal bone. *Am J Otolaryngol* 1998;19:267-73.
3. Liao H, Wu Z, Xiao B. Plasmacytoma of the temporal bone. *Zhonghua Er Bi Yan Hou Tou Jing Wai Ke Za Zhi* 2005;40:936-8.
4. Ruenes R, Palacios E. Plasmacytoma of the petrous temporal bone. *Ear Nose Throat J* 2003;82:672.
5. Tanaka M, Shibui S, Nomura K, Nakanishi Y. Solitary plasmacytoma of the skull: A case report. *JPN J Clin Oncol* 1998;28:626-30.
6. Chang MY, Shih LY, Dunn P, Leung WM, Chen WJ. Solitary plasmacytoma of bone. *J Formos Med Assoc* 1994;93:397-402.
7. Bolek TW, Marcus RB, Mendenhall NP. Solitary plasmacytoma of bone and soft tissue. *Int J Radiat Oncol Biol Phys* 1996;36:329-33.
8. Mayr NA, Wen BC, Hussey DH, Burns CP, Staples JJ, Doornbos JF, *et al.* The role of radiation therapy in the treatment of solitary plasmacytomas. *Radiother Oncol* 1990;17:293-303.
9. Holland J, Trenkner DA, Wasserman TH, Fineberg B. Plasmacytoma. Treatment results and conversion to myeloma. *Cancer* 1992;69:1513-7.
10. Lieboss RH, Ha CS, Cox JD, Weber D, Delasalle K, Alexanian R. Solitary bone plasmacytoma: Outcome and prognostic factors following radiotherapy. *Int J Radiat Oncol Biol Phys* 1998;41:1063-7.
11. Tsang RW, Gospodarowicz MK, Pintilie M, Bezjak A, Wells W, Hodgson DC, *et al.* Solitary plasmacytoma treated with radiotherapy: Impact of tumor size on outcome. *Int J Radiat Oncol Biol Phys* 2001;50:113-20.
12. Hughes M, Soutar R, Lucraft H, Owen R, Bird J.(2009). Guidelines on the diagnosis and management of solitary plasmacytoma of bone, extramedullary plasmacytoma and multiple solitary plasmacytomas: 2009 update. Prepared by a working group of UKMF Guidelines Working Group. Web site: [http://www.bcshguidelines.com/pdf/SBP\\_guideline\\_update\\_FINAL\\_190109.pdf](http://www.bcshguidelines.com/pdf/SBP_guideline_update_FINAL_190109.pdf).
13. Soutar R, Lucraft H, Jackson G, Reece A, Bird J, Low E, *et al.* Guidelines on the diagnosis and management of solitary plasmacytoma of bone and solitary extramedullary plasmacytoma. *Br J Haematol* 2004;124:717-26.
14. Mendenhall CM, Thar TL, Million RR. Solitary plasmacytoma of bone and soft tissue. *Int J Radiat Oncol Biol Phys* 1980;6:1497-501.
15. Shih LY, Dunn P, Leung WM, Chen WJ, Wang PN. Localised plasmacytomas in Taiwan: Comparison between extramedullary plasmacytoma and solitary plasmacytoma of bone. *Br J Cancer* 1995;71:128-33.
16. Avilés A, Huerta-Guzmán J, Delgado S, Fernández A, Díaz-Maqueo JC. Improved outcome in solitary bone plasmacytoma with combined therapy. *Hematol Oncol* 1996;14:111-7.
17. Ozsahin M, Tsang RW, Poortmans P, Belkacémi Y, Bolla M, Dinçbas FO, *et al.* Outcomes and patterns of failure in solitary plasmacytoma: A multicenter Rare Cancer Network study of 258 patients. *Int J Radiat Oncol Biol Phys* 2006;64:210-7.
18. Wilder RB, Ha CS, Cox JD, Weber D, Delasalle K, Alexanian R. Persistence of myeloma protein for more than one year after radiotherapy is an adverse prognostic factor in solitary plasmacytoma of bone. *Cancer* 2002;94:1532-7.
19. Kyle RA. Monoclonal gammopathy of undetermined significance and solitary plasmacytoma. Implications for progression to overt multiple myeloma. *Hematol Oncol Clin North Am* 1997;11:71-87.