

CASE REPORT

Subdural actinomycoma presenting as recurrent chronic subdural hematoma

N. J. Ismail, G. M. Bot, S. Sahabi¹, S. Aliu, B. Usman, D. J. Shilong, J. O. Obande, B. B. Shehu

Department of Neurosurgery, Regional Centre for Neurosurgery, ¹Department of Pathology, Usmanu Danfodiyo University Teaching Hospital, P.M. B. 2370 Sokoto, Nigeria

ABSTRACT

Actinomycosis is a rare chronic bacterial infection of the central nervous system, and subdural actinomycoma is extremely rare. This case report brings to bear an uncommon association between subdural actinomycosis with chronic subdural hematoma. Subdural actinomycoma may present as a diagnostic conundrum and could be mistaken radiologically for either a subdural hematoma or an empyema.

Key words: Actinomycosis, actinomycoma, actinomycosis, subdural haematoma, subdural subdural actinomycoma

Introduction

Actinomycosis is a chronic bacterial infection which causes suppuration and a granulomatous inflammatory response, this disease rarely affects the central nervous system.^[1-4] It usually presents with external sinuses which may extrude “sulfur granule”. Actinomycosis is caused by *Actinomyces* species, which are gram positive filamentous branched bacteria that have the ability to break to coccobacilli. There are several species of actinomyces with *Actinomyces israeli* being the most common. Others include *A. naeslundii*, *A. dontolyticus*, *A. viscosus*, and *A. meyeri*. Actinomycosis has a worldwide distribution unrelated to geographical region, occupation, race, or age. Men are more commonly affected compared with women, with a male to female ratio of 3:1.^[4] Less than 100 cases of actinomycosis are reported annually by the Centers for Disease Control and Prevention.^[4] Actinomyces are normal commensals of the oral, abdominal, and pelvic cavity.^[1] The clinical forms of actinomycosis include cervicofacial, thoracic, abdominal, and the genital form in females.^[4]

Subdural hematomas encompass several distinct clinical

pathological conditions, with the only common feature being fluid in the subdural space. Chronic subdural hematoma is common in the elderly and infants; in the adult, it appears as dark and turbid like “Crank case oil”, while in the infants, it is lighter and watery. They are usually at least two weeks old but may present clinically months or years after a trivial injury.^[5] Chronic subdural hematoma has been a controversial neurosurgical topic in terms of the pathophysiology and treatment, since it was described by Virchow in 1875 as pachymeningitis hemorrhagica interna. Subdural hematomas may be of venous or arterial origin and often results from the tearing of a bridging vein between the cerebral cortex and a draining venous sinus. The incidence is about 1-2 per 100,000 per year; however, the incidence increases with age. Predisposing factors include advanced age, chronic alcoholism, epilepsy, coagulopathy, and intracranial shunting procedures.^[6]

Case Report

A 21-year-old student was presented two years ago with a two year history of occipital headache and progressive visual loss. He had a magnetic resonance imaging (MRI) which showed a cystic midline mass with a nodule in the posterior fossa with dilated lateral and third ventricles. He had a ventriculo-peritoneal shunt to divert cerebrospinal fluid and he was scheduled for a definitive surgery. However, the surgery could not hold due to logistic reasons until 15 months after presentation when he had a repeat CT scan which showed a left subdural hematoma in addition to the posterior fossa tumor. He then had a posterior fossa craniectomy with a left parietal burrhole and evacuation of the hematoma with intraoperative findings of a cystic cerebellar tumor with xanthochromic fluid, histology revealed a pleomorphic xanthoastrocytoma World Health Organization (WHO) grade II. Two months after the first burr hole, a repeat computed tomography (CT) scan was performed which showed

Access this article online

Quick Response Code:



Website:

www.asianjns.org

DOI:

10.4103/1793-5482.145051

Address for correspondence:

Dr. Gyang Markus Bot, Regional Centre for Neurosurgery, Usmanu Danfodiyo University Teaching Hospital, Sokoto, Nigeria.
E-mail: gyangbot@yahoo.co.uk

an isodense lesion in the left subdural space [Figure 1] which had a contrast enhancing ring [Figure 3] and a diagnosis of a subdural empyema was entertained. However, he had the second burr hole four months after the first one with findings of a left subdural haematoma. Another CT scan done 6 weeks after the second burr hole showed a lesion in the subdural space. Hence, the decision was made for a minicraniotomy, intraoperatively about 15 ml of “engine oil” like fluid, and a well formed membrane containing the chronic subdural hematoma with cheesy material extending from the left frontal to the left occipital region was found. Histology turned out to be actinomycosis. Post operatively, he had aphasia and seizures which were controlled. He was subsequently discharged and was on doxycillin for six weeks, and he made an uneventful recovery.

Discussion

Actinomycosis of the central nervous system (CNS) is rare.^[1,2] Cervicofacial actinomycosis accounts for about 50-60% cases of actinomycosis; these condition arises from poor oral hygiene

with tooth decay, periodontal disease, and gingivitis. The condition may be acute or subacute, presenting with a swelling in the submandibular and paramandibular region. The mandible is the commonest bone involved. Infection of cranial bones or the cervical spine leads to subdural empyema and invasion of the CNS. Actinomycosis of the brain may present as a brain abscess, meningitis/meningoencephalitis, and actinomycoma in 67%, 13%, and 7%, respectively.^[1] Subdural and extradural empyema was present in 6% of cases.^[1,7] Fever, pain, and leukocytosis may be the presenting features.^[4] However, cranial infections are usually of long duration and fever was not commonly present.^[1] Spread to the CNS is usually by direct invasion.

The mechanism by which chronic subdural hematoma forms is a matter of great interest and debate. One theory divides the pathophysiological events into two events; the formation of the vascularized membrane and liquefaction of the clot. The theories regarding the subsequent enlargement of the hematoma are numerous. The initial phase involves the proliferative response to the presence of blood in the subdural

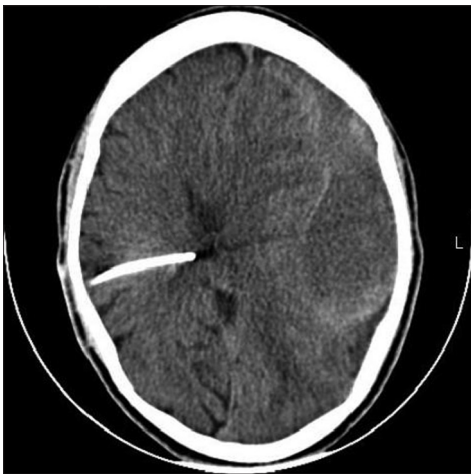


Figure 1: Lesion appears isodense on the left fronto-parietal area. This could be confused for subdural haematoma

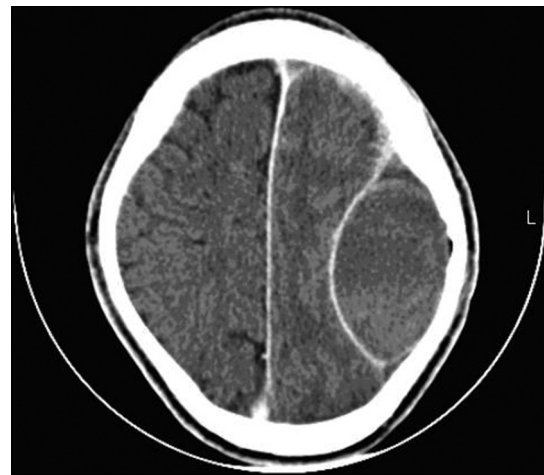


Figure 2: A contrast ring enhancing left parietal lesion which biconvex. This may be confused for an extradural abscess

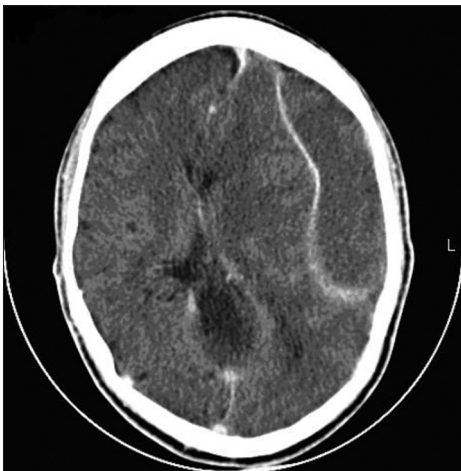


Figure 3: Contrast ring enhancing lesion in the left frontoparietal presenting like a subdural empyema

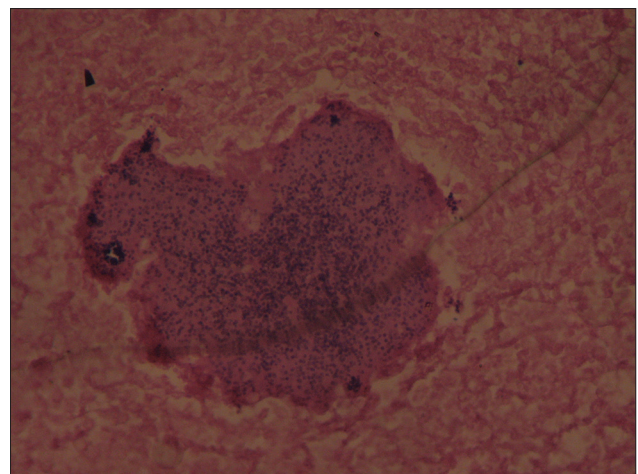


Figure 4: Multiple “sulphur like” granules. x 40 magnification

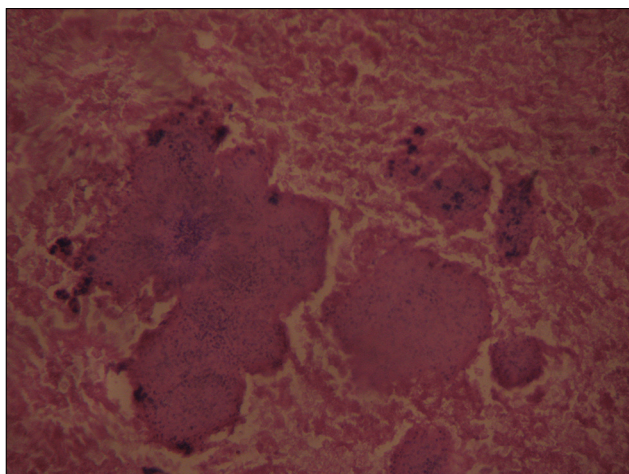


Figure 5: Multiple "sulphur like" granules. x40 magnification

space with subsequent invasion of the area by fibroblast from the dural forming an inner and outer membrane "encapsulating" the hematoma; this occurs about three weeks after the initial response. Amongst the theories of the enlargement is the development of an osmotic gradient which allows for movement of fluid into the hematoma, another is that the fragile neo-capillaries in the membrane rupture repeatedly leading to recurrent hemorrhage filling the cavity. A more recent theory which has been postulated which is based on the disordered hemostatic mechanism, leading to increased fibrinolytic activity within the membrane. In this theory, the initial hemorrhage leads to the release of tissue thromboplastin in the subdural space. This leads to the formation of local clot from thrombin and cross-linking of fibrin from fibrinogen. The clot subsequently leads to activation of the intrinsic fibrinolytic system which splits fibrin to fibrin degradation product affecting further clot formation. A defective clot is formed which leads to recurrent hemorrhage; this stimulates a non-specific proliferation and vascularization of the outer dural membrane, with activation of the extrinsic fibrinolytic system and perpetuation of a vicious cycle. This is the principle behind the drainage of hematomas to allow normal hemostatic process.^[6]

CT scan and MRI are important at arriving at a diagnosis. The diagnoses of these patients are made by culture, demonstration of "sulphur granules" in sinus drainage, or by biopsy and histology of the lesion [Figure 4 and Figure 5].^[8]

Penicillin is the drug of choice in this disease.^[8] It is given at a dose of 10 to 20 million units per day intravenously for six to eight weeks. Subsequently, oral penicillin, tetracycline, doxycycline,

erythromycin, lincomycin, or clindamycin could be given.^[9]

The treatment of subdural hematoma includes one of the following:

1. A twist drill craniostomy,
2. A burr hole and evacuation of hematoma, or
3. A craniotomy.

However, in recurrent hematomas a craniotomy is favored in order to remove the membrane. For the management of a subdural actinomycoma, we recommend a craniotomy.

This presents a rare bacterial infection of the CNS in which the intra operative findings was subdural actinomycoma. Actinomycomas though rare are usually seen in the brain parenchyma; however, this patient had a solid yellowish grey tumor in the subdural space. This report also highlights an extremely rare cause of recurrent subdural hematoma i.e., actinomycosis. It is also important to bear that a subdural actinomycoma may present to the radiologist as a diagnostic conundrum and be regarded as either a subdural hematoma, a subdural empyema, or even an extradural lesion [Figure 2].

References

1. Smego RA. Actinomycosis of the central nervous system. *Rev Infect Dis* 1987;9:855-65
2. Ferraz AC, Melo CV, Pereira EL, Stavale JN, Nogueira RG, Gabbai AA, *et al.* Actinomycosis of the central nervous system: A rare complication of cervicofacial actinomycosis. *Arq Neuropsiquiatr* 1993;51:358-62
3. Oh HM, Cheong WY, Tan KK, Sim CS, Jayaratnam FJ. Actinomycosis of the brain. *Ann Acad Med Singapore* 1991;20:808-11.
4. Bullock WE. Actinomycosis. In: Cecil Textbook of Medicine. 21st ed. 2000. In: Goldman L, Bennett JC (editors.). Philadelphia: WB Saunders: 2000. p.1714-5.
5. Crooks DA. Pathogenesis and biomechanics of traumatic intracranial haemorrhages. *Virchows Arch* 1991;418:479.
6. Wilberger JE. Chronic Subdural Haematoma In: Rengachary SS, Wilkin RH, Editors. *Neurosurgical Operative Atlas*. Illinois: American Association of Neurological Surgeons Chigcago; 1992;2:42-8.
7. King AD, Chan YL, Wong KS, Sung JJ, Fung K, Poon WS. Cranial actinomycosis. *Singapore Med J* 1998;39:465-57.
8. Carey ME. Infections of the spine and spinal cord. In: Youmans Neurological surgery, 4th Ed In: Youman JR (editor.). Philadelphia: WB Saunders: 1996;5:32991.
9. Nolan RL, Ross JD, Chapman SW. Thoracic Actinomycosis as spinal cord compress. *J Miss State Med Assoc* 1990;31:41

How to cite this article: Ismail NJ, Bot GM, Sahabi S, Aliu S, Usman B, Shilong DJ, *et al.* Subdural actinomycoma presenting as recurrent chronic subdural hematoma. *Asian J Neurosurg* 2015;10:129-31.

Source of Support: Nil, **Conflict of Interest:** None declared.