

CASE REPORT

Ossification of ligamentum flavum, a rare cause of myelopathy: First case report of a Lebanese patient

Antonios El Helou, Moussa Alaywan, Antonio Tarabay, Antoine Nachanakian

Departement of Neurosurgery, Saint George Hospital University Medical Centre, in Collaboration with Balamand University, Beirut, Lebanon

ABSTRACT

Ossification of ligamentum flavum (OLF) is a well-known pathology causing myelopathy, although it is a rare disease. The most commonly affected population is from the Far East and mainly Japanese. However, few reports and studies have shown the prevalence of the disease all over the world. We report the case of a 33-year-old man presenting with signs of progressive myelopathy. Magnetic resonance imaging (MRI) showed Th2-Th11 OLF with severe narrowing and intramedullary hypersignal at the level Th2-Th3. This is the first Lebanese case reported in the literature. A decompressive laminectomy with flavectomy was done. This case adds to the previous reported cases on the occurrence of the disease in different populations.

Key words: Myelopathy, ossification of ligamentum flavum, thoracic spinal cord

Introduction

Ossification of ligamentum flavum (OLF) is a well-known pathology causing myelopathy, although it is a rare disease.^[1] The most commonly affected population is from the Far East and mainly Japanese. However, few reports and studies have shown the prevalence of the disease all over the world. Low thoracic spine is the most affected region. But several cases of cervical, upper thoracic, and lumbar areas have been reported.^[2] OLF can be idiopathic or associated with metabolic or genetic disease.^[3] We are reporting the first Lebanese case of multiple levels OLF presenting with signs of progressively worsening myelopathy.

Case Report

A 33-year-old man with no previous medical or family history presented with back pain with progressively worsening gait. He reported 1 year history of progressively worsening

gait. First the walking distance decreased progressively, necessitating several episodes of rest in sitting or supine position. The previous month, the patient had become completely dependent with inability to stand and ambulate alone, with paresthesia starting at the level of the nipple and extending to both lower limbs. Neurological examination showed normal motor strength, deep tendon reflexes, and sensation in the upper limb. A 2/5 motor strength in the lower limb bilaterally and with the same strength in proximal and distal parts of the limb was present. In addition, hyperreflexia with Babinski sign were found in both lower limbs.

He was admitted as an emergency to our institution. A cervical–thoracic spine MRI [Figures 1-3] was done and showed Th2-Th11 OLF with intramedullary hypersignal at Th2–Th3 level. He was operated upon urgently by laminectomy and flavectomy extending from Th2 to Th10. Peroperatively, we were unable to do laminectomy in the conventional manner, which necessitated the use of high-speed drill due to the severely calcified ligamentum flavum. We were able to preserve the dura mater without any leakage of cerebrospinal fluid.

Postoperatively, motor strength improved progressively over 6 months with intensive physiotherapy program in a specialized center. Paresthesia resolved progressively, but hyperreflexia persisted [Figure 4].

Discussion

OLF is widely recognized as a primary cause of spinal cord compression.^[4] It could occur isolated or in combination with ossification of posterior longitudinal ligament which worsens

Access this article online	
Quick Response Code:	Website: www.asianjns.org
	DOI: 10.4103/1793-5482.145067

Address for correspondence:

Dr. Antonios El Helou, Division of Neurosurgery, Saint George Hospital University Medical Centre, in Collaboration with Balamand University, Youssef Surssock Street, Rmeil, Beirut, Lebanon.
E-mail: antonioselhelou@hotmail.com

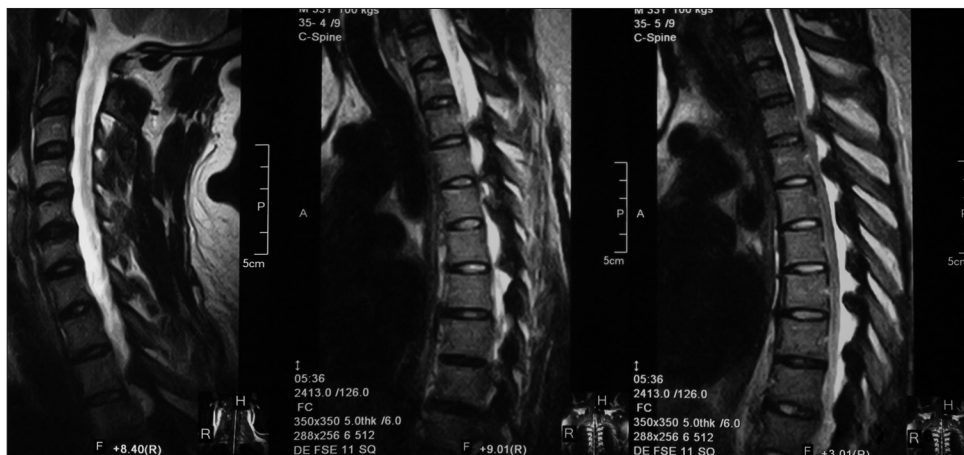

Figure 1: Sagittal T2-weighted image MRI of cervical and upper thoracic spine showing Th2–Th3 ligamentum flavum hypertrophy with intramedullary hypersignal associated with narrowed spinal canal all over the thoracic spinal cord

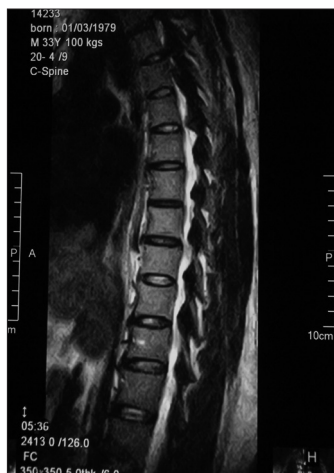

Figure 2: Sagittal T2-weighted image showing the rest of thoracic spinal canal with Th2–Th11 OLF

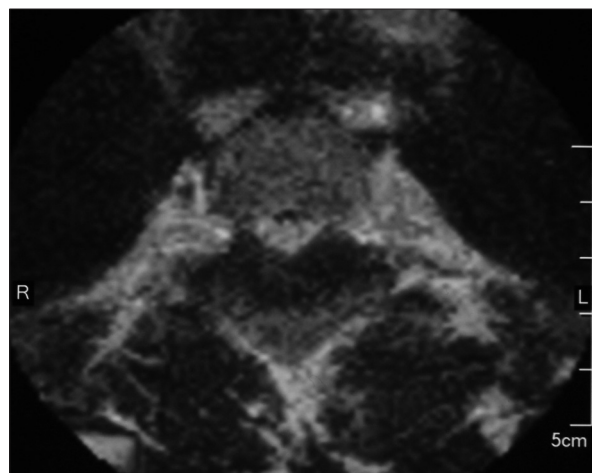


Figure 3: Axial T2-weighted image at Th2–Th3 level showing severe narrowing of spinal canal with OLF

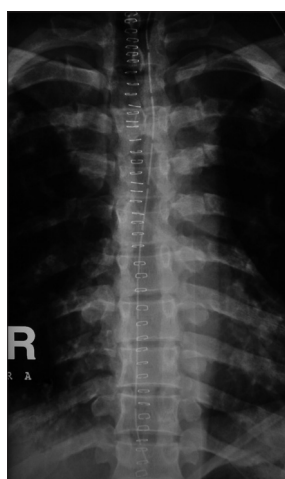

Figure 4: Antero-posterior thoracic spine X-ray postoperatively showing extended Th2–Th11 laminectomy

the spinal canal stenosis. OLF may be idiopathic or may occur in the context of other diseases such as ankylosing spondylitis

and Forestier’s disease. Our case was an idiopathic OLF; our patient did not present any other associated symptom.

Incidental OLF does occur in patients from the Middle East, as it was mentioned by Al-Orainy and Kolawole^[5] in their study done in Kuwait, but in general, it is asymptomatic and none of their patients was admitted for OLF problem. But in the Far East, it is a common cause of myelopathy.

It is true that our case is not exceptional, if not quite common, but the interest in this case appears relevant due to two reasons. The first one is the epidemiology, especially the extremely rare incidence of this disease and the targeted population, from the Middle East, as it is the first reported case of a Lebanese patient, while Japanese seem to be almost exclusively affected. The second level of interest is that thoracic OLF as a cause of cord compression is more common in the lower thoracic part. In our case, the main compression was at Th2–Th3 level. Also, on the other hand, none of the previously reported cases in the literature showed such a

diffuse OLF extending more than seven segments (in our case nine segments).

There is only one case in the literature reporting on OLF causing symptomatic spinal cord compression at Th2–Th3 level in Turkish people.^[2]

Mechanical factors have been postulated as predisposing factors.^[6] Our patient is an army officer and he has on continuous military training. This could explain the mechanical stress on his spinal cord. Thus, the OLF occurred at thoracic level, where stress and stretch forces are less compared to cervical and lumbar area, which is against the previously postulated theory.

Unfortunately, the ligamentum flavum specimen was not sent for pathological laboratory study. The location, sex, and age of patient did not raise any suspicion of pathological cause of the disease, such as calcium pyrophosphate dihydrate deposition disease.

Furthermore, previous studies showed the role of multiple growth factors [vascular endothelial growth factor (VEGF) and transforming growth factor] and proteins [bone morphogenetic proteins (BMPs) and cartilage derived morphogenetic protein-1] in the development of OLF.^[7] In our institution, it is not technically possible to do these laboratory tests for our patients.

Investigation tools used for diagnosis are spine CT scan that shows a bean-like high-density mass inside the ligamentum flavum^[8] and spine MRI where there is usually a dorsolateral low-signal mass appearance on both T1- and T2-weighted images.^[9] We have done a spine MRI in an emergency setting and we did not find that an additional spine CT scan could be helpful for therapeutic strategy changes.

For thoracic OLF, fenestration or *en bloc* laminectomies are usually performed. The ossified ligament should be removed carefully because there might be an ossification of the dura mater.^[10]

The overall prognosis depends on the severity of myelopathy,^[11,12] though the postoperative improvement is directly related to the preoperative status of the patient and his response to physical rehabilitation therapy.

Conclusion

Although rare, OLF, even at high thoracic levels, should be considered as a cause of spinal cord compression in all patients. Its prevalence is higher in the Far East patients, but it does occur in different ethnic groups. The extension all over the thoracic spinal cord in a continuous manner makes this case unique.

References

1. Miyasaka K, Kaneda K, Ito T, Takei H, Sugimoto S, Tsuru M. Ossification of spinal ligaments causing thoracic radiculomyelopathy. *Radiology* 1982;143:463-8.
2. Sucu HK, Bezircioglu H. Ossification of the ligamentum flavum at the upper thoracic spine: Case report. *Turk Neurosurg* 2004;14:49-51.
3. Wang W, Kong L. Ossification of ligamentum. *J Neurosurg Spine* 2007;6:96.
4. Inoue H, Seichi A, Kimura A, Endo T, Hoshino Y. Multiple-level ossification of the ligamentum flavum in the cervical spine combined with calcification of the cervical ligamentum flavum and posterior atlanto-axial membrane. *Eur Spine J* 2012 Oct 6. [Epub ahead of print] 2012.
5. Al-Oraiy IA, Kolawole T. Ossification of the ligament flavum. *Eur J Radiol* 1998;29:76-82.
6. Kruse JJ, Awasthi D, Harris M, Waguespack A. Ossification of the ligamentum flavum as a cause of myelopathy in North America: Report of three cases. *J Spinal Disord* 2000;13:22-25.
7. Fotakopoulos G, Alexiou GA, Mihos E, Voulgaris S. Ossification of the Ligamentum Flavum in cervical and thoracic spine. Report of three cases. *Acta Neurol Belg* 2010;110:186-9.
8. Miyasaka K, Kaneda K, Sato S, Iwasaki Y, Abe S, Takei H, et al. Myelopathy due to ossification or calcification of the ligamentum flavum: Radiologic and histologic evaluations. *AJNR Am J Neuroradiol* 1983;4:629-32.
9. Xiong L, Zeng QY, Jinkins JR. CT and MRI characteristics of ossification of the ligamenta flava in the thoracic spine. *Eur Radiol* 2001;11:1798-802.
10. Inamasu J, Bernard G. A review of factors predictive of surgical outcome for ossification of the ligamentum flavum of the thoracic spine. *J Neurosurg Spine* 2006;5:133-9.
11. Ben Hamouda BK, Jemel H, Haouet S, Khaldi M. Thoracic myelopathy caused by ossification of the ligamentum flavum: A report of 18 cases. *J Neurosurg* 2003;99 (2 Suppl):157-61.
12. Bouchakour M, Stambouli A, Bentifour M, Benamara M, Beloud M. Hypertrophy of ligamentum flavum of the thoracic spine and spinal cord compression. *Panarab Journal of Neurosurgery* 2011;15:85,86.

How to cite this article: El Helou A, Alaywan M, Tarabay A, Nachanakian A. Ossification of ligamentum flavum, a rare cause of myelopathy: First case report of a Lebanese patient. *Asian J Neurosurg* 2016;11:180-1.

Source of Support: Nil, **Conflict of Interest:** None declared.