

CASE REPORT

Esthesioneuroblastoma with intracranial extension: A non-surgical approach

Sarah Bobby Thomas, Deepak Balasubramaniam¹, K. R. Hiran³, M. Dinesh, K. Pavithran²

Departments of Radiation Oncology, ¹Head and Neck Oncology, and ²Medical Oncology, ³Pathology, Amrita Institute of Medical Sciences and Research Centre Edapally, Elammakara, Kochi, Kerala, India

ABSTRACT

Esthesioneuroblastoma is a rare tumor arising from the olfactory mucosa of upper respiratory tract. The primary modality of treatment has been surgery with craniofacial resection followed by post-operative radiotherapy. There are only a few reported cases of non-surgical approaches. We report a case of esthesioneuroblastoma with intracranial extension treated with Vincristine, Adriamycin, Cyclophosphamide, Ifosfamide, Etoposide protocol followed by radiation with 5 years of follow-up. This is the first reported case using this chemotherapy schedule.

Key words: Chemo radiation, esthesioneuroblastoma, intracranial extension

Introduction

Esthesioneuroblastoma, also known as olfactory neuroblastoma is a rare and aggressive malignant neoplasm that originates in the olfactory epithelium of the upper nasal cavity accounting for 3-6% of intranasal tumors.^[1] Surgical resection and post-operative radiotherapy is the standard of care.^[2] Advanced cases with intracranial extension pose a surgical challenge. Chemotherapy can be used in the Neoadjuvant and adjuvant setting. We report the case of a 13-year-old girl with esthesioneuroblastoma having intracranial extension treated using neoadjuvant chemotherapy followed by radiation.

Case Report

A 13-year-old female presented with recurrent nasal bleeding of 1 year duration and progressive nasal obstruction of 2 months duration. Clinical examination revealed a mass in the left nostril. Computed tomography (CT) brain scan showed a soft-tissue density mass in left maxillary sinus with destruction of nasal septum and medial wall of left orbit.

A biopsy reported a small round blue cell neoplasm [Figure 1]. Immunohistochemistry showed diffuse strong positivity for S100 [Figure 2] and Synaptophysin [Figure 3]. It was negative for Cytokeratin, Desmin, Leukocyte common antigen, CD99 and Vimentin, consistent with Esthesioneuroblastoma, Hyams Grade2. Magnetic resonance imaging (MRI) [Figure 4] showed a lesion involving primarily left nasal cavity and bilateral posterior ethmoidal sinuses. The nasal septum, osteo meatal complex and ostea of frontal sinuses were also involved with occluded ostium of frontal sinuses leading to accumulation of secretions in left maxillary sinus and frontal sinus. MRI also showed extension to the left orbit, optic canal, cavernous sinus, and anterior cranial fossa. She was staged as Kadish Stage C.

After discussion in the multi-disciplinary tumor board, it was decided to offer her Neoadjuvant chemotherapy and adjuvant radiotherapy. She received chemotherapy with VAdRC-IE protocol (Vincristine 2 mg/m² Day 1, Adriamycin 75 mg/m² Day 1, Cyclophosphamide 1200 mg/m² Day 1, alternating with Ifosfamide 1800 mg/m² D1-D5, Etoposide 100 mg/m² Day 1-day 5 Q 3 weekly). She was reassessed with a CT Brain after six cycles, which revealed near complete response to chemotherapy [Figure 5]. Radiation was delivered using a 3D conformal plan to a total dose of 6000 cGy in 30 fractions. The target volume included the pre-chemotherapy tumor volume with margins. She tolerated treatment well except for Grade 1 skin reactions. She has been on regular follow-up with annual CT scans [Figure 6]. With 60 months of follow-up she continues to be disease free without any delayed complications of therapy.

Access this article online	
Quick Response Code:	Website: www.asianjns.org
	DOI: 10.4103/1793-5482.145087

Address for correspondence:

Dr. Sarah Bobby Thomas, Department of Radiation Oncology, Amrita Institute of Medical Sciences and Research Centre, Edapally, Elammakara, Kochi - 682 041, Kerala, India.
E-mail: drbsarah@gmail.com

Discussion

Esthesioneuroblastoma is a rare tumor originating in the upper nasal cavity. Craniofacial resection with adjuvant radiation is the

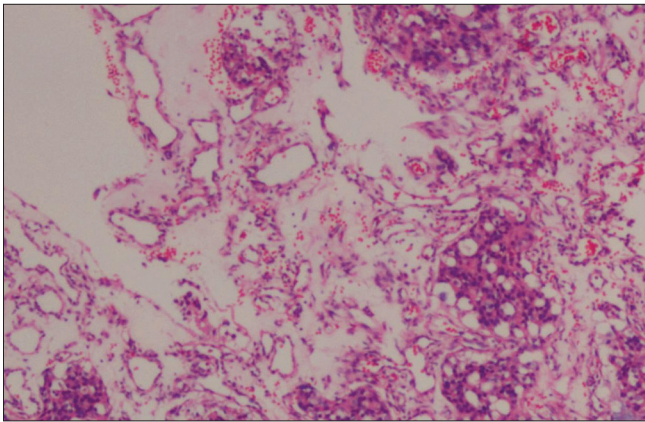


Figure 1: Pathology (H and E, x40)

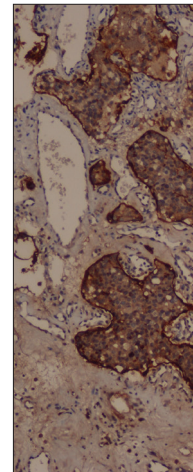


Figure 2: S 100

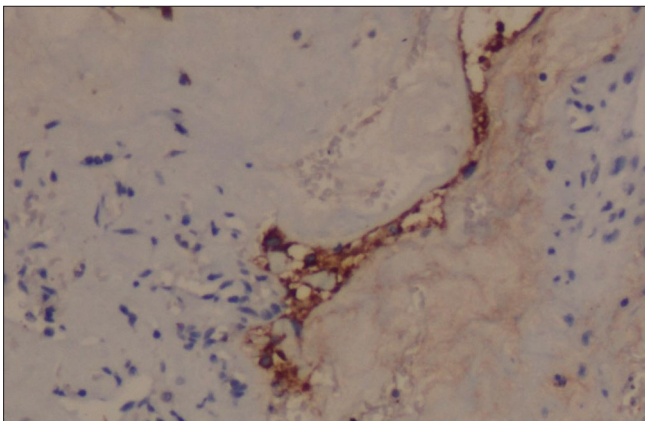


Figure 3: Synaptophysin

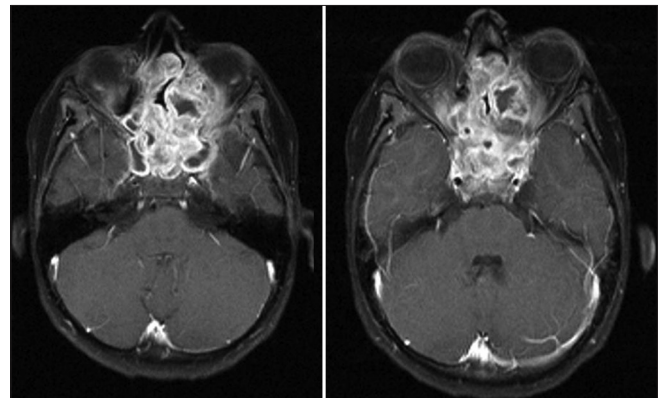


Figure 4: Magnetic resonance imaging with contrast showing intracranial extension

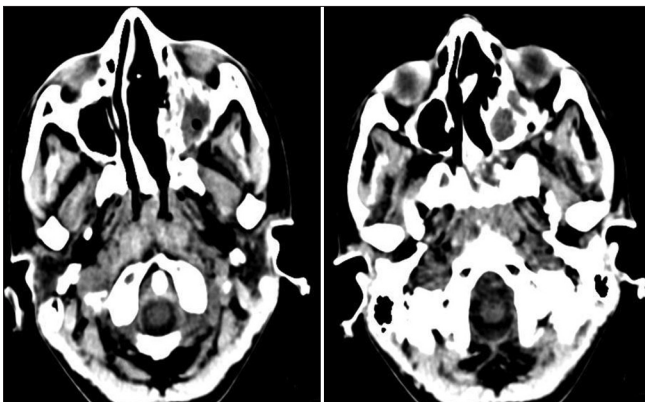


Figure 5: Computed tomography images post chemotherapy showing complete response

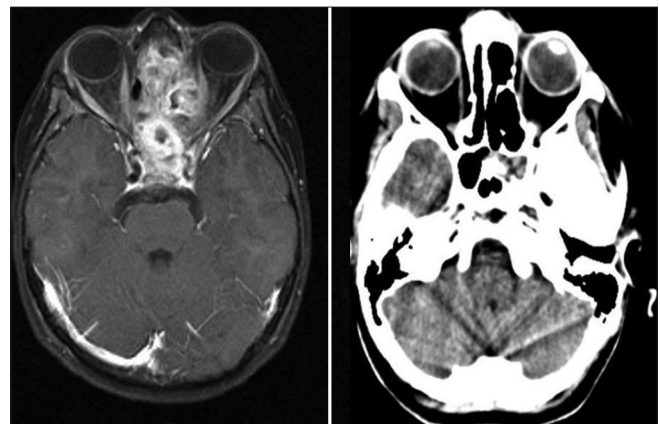


Figure 6: Pretreatment MRI on the left. 3 years post chemoradiation computed tomography scan showing no evidence of disease

most accepted approach in resectable cases. Limited surgery with non-craniofacial resection followed by chemotherapy and radiation have also been reported.^[3] Chemotherapy along with radiation has been used in the management of Esthesioneuroblastoma in an effort to decrease the morbidity of surgery with mixed results. Esthesioneuroblastoma is moderately radiosensitive to post-operative doses of 60-66 Gy. Neoadjuvant chemotherapy followed by radiation and craniofacial resection has been advocated by the University of Virginia for Kadish Stage C.^[4]

At Harvard a nonsurgical approach included neoadjuvant chemotherapy using Cisplatin and Etoposide followed by proton therapy showing excellent results.^[5]

Mishima *et al.* achieved a complete response in eight out of 12 patients with an aggressive multi agent chemotherapy schedule.^[6] Turano *et al.* reported a case successfully treated

using the same regimen, alternating Cisplatin Etoposide with Doxorubicin, Ifosfamide and Vincristine.^[7]

We however chose to use VAdRC IE, a schedule commonly employed for primitive neuroectodermal tumors. Our patient, an adolescent girl, the first ever reported case with this chemotherapy schedule showed an excellent response, which was consolidated with radiotherapy. This case report highlights the use of definitive chemoradiation in Esthesioneuroblastoma as a possible curative option. Further avenues of research are needed to demonstrate the efficacy of chemo radiation in this rare neuronal cancer.

References

1. Svane-Knudsen V, Jørgensen KE, Hansen O, Lindgren A, Marker P. Cancer of the nasal cavity and paranasal sinuses: A series of 115 patients. *Rhinology* 1998;36:12-4.
2. Lund VJ, Howard D, Wei W, Spittle M. Olfactory neuroblastoma: Past, present, and future? *Laryngoscope* 2003;113:502-7.
3. Rastogi M, Bhatt M, Chufal K, Srivastava M, Pant M, Srivastava K, *et al.* Esthesioneuroblastoma treated with non-craniofacial resection surgery followed by combined chemotherapy and radiotherapy: An alternative approach in limited resources. *Jpn J Clin Oncol* 2006;36:613-9.
4. Loy AH, Reibel JF, Read PW, Thomas CY, Newman SA, Jane JA, *et al.* Esthesioneuroblastoma: Continued follow-up of a single institution's experience. *Arch Otolaryngol Head Neck Surg* 2006;132:134-8.
5. Dulguerov P, Allal AS, Calcaterra TC. Esthesioneuroblastoma: A meta-analysis and review. *Lancet Oncol* 2001;2:683-90.
6. Mishima Y, Nagasaki E, Terui Y, Irie T, Takahashi S, Ito Y, *et al.* Combination chemotherapy (cyclophosphamide, doxorubicin, and vincristine with continuous-infusion cisplatin and etoposide) and radiotherapy with stem cell support can be beneficial for adolescents and adults with esthesioneuroblastoma. *Cancer* 2004;101:1437-44.
7. Turano S, Mastroianni C, Manfredi C, Biamonte R, Ceniti S, Liguori V, *et al.* Advanced adult esthesioneuroblastoma successfully treated with cisplatin and etoposide alternated with doxorubicin, ifosfamide and vincristine. *J Neurooncol* 2010; 98:131-5.

How to cite this article: Thomas SB, Balasubramaniam D, Hiran KR, Dinesh M, Pavithran K. Esthesioneuroblastoma with intracranial extension: A non-surgical approach. *Asian J Neurosurg* 2016;11:313.

Source of Support: Nil, **Conflict of Interest:** None declared.