

CASE REPORT

Transorbital penetrating brain injury by a wooden stick: A neuro-ophthalmologic emergency

Sanjay Kumar Behera, Souvagya Panigrahi, Sudhansu Sekhar Mishra, Satya Bhusan Senapati

Department of Neurosurgery, S.C.B. Medical College and Hospital, Cuttack, Odisha, India

ABSTRACT

Accidental penetrating brain injury through transorbital route is an unusual occurrence in emergency practice of civilian cases. At time, it could be potentially life threatening. We report an interesting case of transorbital penetrating brain injury with a wooden stick in a 44-year-old male epileptic patient. The stick was removed successfully through transorbital exploration, without any neurovascular complications. The pertinent literature is reviewed and emergent management of such cases is discussed.

Key words: Penetrating brain injury, transorbital route, wooden stick

Introduction

Accidental penetrating brain injury is relatively uncommon representing about 0.4% of all head injuries.^[1] Adult calvarium acts as a protective barrier favoring this low incidence. However, areas of skull bone where the bone is thin such as temporal region, orbital surface are more likely to break and cause these injuries to happen.^[1] Transorbital penetrating brain injury secondary to a non-projectile foreign body is a rare incident. Narrating such a rare case of transorbital penetrating brain injury with a wooden stick in an epileptic patient is interesting to report. As there is significant lack of data pertaining to the management of penetrating brain damage by foreign body, it is pertinent to understand the mechanism, anatomy, and treatment of such injuries.

Case Report

A 44-year-old male presented to our emergency department with injury to his right eye. History revealed that he was a known epileptic patient and had an episode of convulsion while traveling with his bike. He fell down and a broken wooden

piece entered into his right eye. On physical examination, the patient had a pulse rate of 104 per minute and blood pressure of 110/76 mm Hg. His Glasgow Coma Scale (GCS) score, on admission, was 15. Left pupil was normal in size and reacting to light, whereas right eye globe was ruptured with a wooden stick *in situ*. There was a lacerated wound over his right eye with loss of vision. Rest of the neurological examination findings were within normal limits. He was resuscitated promptly according to the advanced trauma life support system.

Initial computerized tomography (CT) scan of the head shows pneumocephalus [Figure 1]. CT scan of orbit in both coronal and axial plane with multiplanar reformation shows the presence of a foreign body present in the right orbital cavity. The foreign body extended to contralateral frontal lobe traversing through the roof and medial orbital wall abutting the posterior surface. Trajectory of the foreign body was from right orbital roof to right frontal region [Figure 2].

The patient was immediately shifted to operating room for emergency exploration. Transorbital exploration of the wound was done. The wooden stick was removed carefully without further brain damage [Figure 3]. Debridement of bone fragments, hair, and other debris followed by enucleation of right eyeball was done with the help of ophthalmologic team. Postoperative course was uneventful and there was no cerebrospinal fluid (CSF) fistula. The patient recovered and was discharged on postoperative day 8 with GCS of 15. At six-month follow-up, he was doing well.

Discussion

Transorbital penetrating brain injury secondary to a non-projectile foreign body is a rare incident. Intracranial complications in these cases can include cerebral contusion,

Access this article online	
Quick Response Code:	Website: www.asianjns.org
	DOI: 10.4103/1793-5482.145092

Address for correspondence:

Dr. Souvagya Panigrahi, Mch, Senior Resident (Academic)
Department of Neurosurgery, S.C.B. Medical College and Hospital,
Cuttack, Odisha - 753 007, India. E-mail: souvagya.ms@gmail.com

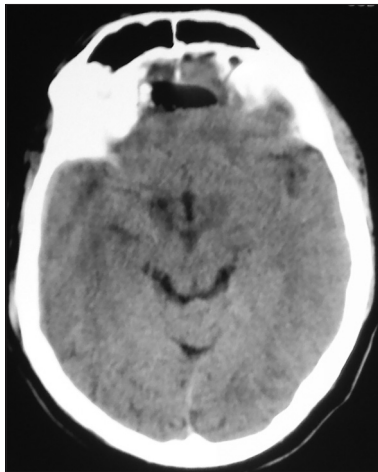

Figure 1: CT scan of head in axial plane showing pneumocephalus involving both frontal lobe

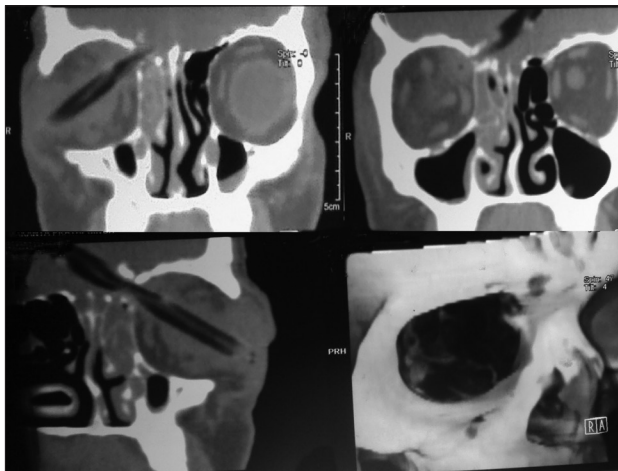


Figure 2: CT scan of head and orbit in coronal plane with multiplanar reformation showing trajectory of the foreign body, extending from right orbital cavity through the roof to contralateral frontal region

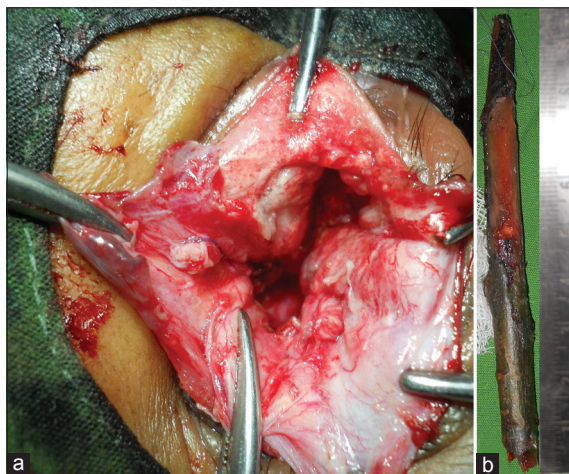


Figure 3: Operative photograph showing transorbital exploration (a) and extracted wooden stick (b)

CSF fistulas, pneumocephalus, orbital cellulites, carotid-cavernous sinus fistula, brain stem injury, and intracranial

hemorrhage. Central nervous system infection is a later complication that has to be kept in mind. The direction of the penetration is the major determinant of the type of injury.

The orbit is a bony pyramid-shaped structure with thin walls that are vulnerable to injury. Foreign bodies typically penetrate the orbit from the medial canthus and usually pass through the optic canal and superior orbital fissure to lodge in the ipsilateral or contralateral side of the cranium.^[2] The most frequent path of penetration is via the roof of the orbit due to the fragile structure of the superior orbital plate of the frontal bone, often resulting in frontal lobe damage, as it was found in our case.

The pathophysiology is similar to closed head injuries causing cerebral contusion or intracranial hemorrhage, but there is more likelihood chance of infection.^[3] Direct crushing and laceration along the tract of penetrating injury is the initial event. As in closed head injury, intracranial pressure is likely to increase due to swelling or bleeding due to crushing of brain tissue, but most deaths are caused by damage to blood vessels which can lead to hemorrhage and ischemia.

Studies with Positron emission tomography (PET) scanning and transcranial Doppler imaging have shown that changes in cerebral blood flow, such as hypoperfusion and vasospasm, can follow penetrating head injury. These changes can last for two weeks.^[3] Sometimes, in penetrating injuries, the brain releases thromboplastin, which can lead to problems with blood clotting.^[4] Although blunt head trauma does not present a risk of shock due to hemorrhage, penetrating head trauma does.^[5]

A person with a penetrating head injury may be evaluated using X-ray, CT scan, or magnetic resonance tomography (MRI). However, MRI can only be used when the penetrating object would not be magnetic, because MRI uses magnetism and could move the object, causing further injury.^[3] When there is a suspicion of transorbital penetration, the clinical examination must be supplemented by orbital and cerebral CT scan with both axial and coronal sections of the orbit. However, scanning artifacts from metal objects can sometimes limit visualization of brain tissue and brain damage along the trajectory of the penetrating object.

The most appropriate management in the field is to leave the transorbital object *in situ* and transport the patient to the trauma center carefully. Intravenous fluids are given and efforts are taken to maintain high blood oxygen levels.^[3] Management of patients with transorbital brain injuries and foreign bodies *in situ* should follow basic surgical principles, including removal of the object under direct vision in order to reduce further brain tissue damage by the foreign bodies catching on bone fragments.^[6] Following removal of the foreign body, thorough debridement with removal of all involved skull bone and foreign materials, hematoma evacuation followed by careful hemostasis along the trajectory, and meticulous

dural closure to reduce the possibility of CSF fistula are mandatory.^[7] Except in high-velocity injuries, most penetrating injuries, regardless of size of penetrating bodies, are rarely associated with major neurological symptoms. Early surgical exploration is likely to be successful in cases of retained foreign body. A transorbital or transcranial approach can be chosen depending on the location of the fragment.

We believe that after adequate resuscitation, prompt craniotomy for decompression and meticulous hemostasis for vascular injuries under direct vision should be the goal of management.

Conclusion

In conclusion, transorbital penetrating brain injury caused by a wooden stick is a rare but fatal event. High index of suspicion toward the presence of foreign bodies and emergent surgical intervention is to be considered in spite of consistent lack of evidence on CT scan. Retrieval should be performed on the operating table under direct vision only after preoperative imaging of neurovascular structures.

References

1. Paiva WS, Saad F, Cravalhal ES, Amorim RL, Figueiredo EG, Teixeira MJ. Transorbital stab penetrating brain injury: Report of a case. *Ann Ital Chir* 2009;80:463-5.
2. Davis GA, Holmes AD, Kulg GL. Delayed presentation of transorbital intracranial pen. *J Clin Neurosci* 2000;7:545-8.
3. Domenicucci M, Qasho R, Ciappetta P, Vangelista T, Delfini R. Surgical treatment of penetrating orbito-cranial injuries. Case report. *J Neurosurg Sci* 1999;43:229-34.
4. Lin HL, Lee HC, Cho DY. Management of transorbital brain injury. *J Chin Med Assoc* 2007;70:36-8.
5. Kitakami A, Kirikae M, Kuroda K, Ogawa A. Transorbital-transpetrosal penetrating cerebellar injury – case report. *Neurol Med Chir (Tokyo)* 1999;39:150-2.
6. Seex K, Koppel D, Fitzpatrick M, Pyott A. Trans-orbital penetrating head injury with a door key. *J Craniomaxillofac Surg* 1997;25:353-5.
7. O'Neill OR, Gilliland G, Delashaw JB, Purtzer TJ. Transorbital penetrating head injury with a hunting arrow: Case report. *Surg Neurol* 1994;42:494-7.

How to cite this article: Behera SK, Panigrahi S, Mishra SS, Senapati SB. Transorbital penetrating brain injury by a wooden stick: A neuro-ophthalmologic emergency. *Asian J Neurosurg* 2016;11:321-2.

Source of Support: Nil, **Conflict of Interest:** None declared.