

Chronic subdural hematoma

Yad R. Yadav, Vijay Parihar, Hemant Namdev, Jitin Bajaj

Department of Neurosurgery, NSCB Medical College, Jabalpur, Madhya Pradesh, India

ABSTRACT

Chronic subdural hematoma (CSDH) is one of the most common neurosurgical conditions. There is lack of uniformity in the treatment of CSDH amongst surgeons in terms of various treatment strategies. Clinical presentation may vary from no symptoms to unconsciousness. CSDH is usually diagnosed by contrast-enhanced computed tomography scan. Magnetic resonance imaging (MRI) scan is more sensitive in the diagnosis of bilateral isodense CSDH, multiple loculations, intrahematoma membranes, fresh bleeding, hemolysis, and the size of capsule. Contrast-enhanced CT or MRI could detect associated primary or metastatic dural diseases. Although definite history of trauma could be obtained in a majority of cases, some cases may be secondary to coagulation defect, intracranial hypotension, use of anticoagulants and antiplatelet drugs, etc., Recurrent bleeding, increased exudates from outer membrane, and cerebrospinal fluid entrapment have been implicated in the enlargement of CSDH. Burr-hole evacuation is the treatment of choice for an uncomplicated CSDH. Most of the recent trials favor the use of drain to reduce recurrence rate. Craniotomy and twist drill craniostomy also play a role in the management. Dural biopsy should be taken, especially in recurrence and thick outer membrane. Nonsurgical management is reserved for asymptomatic or high operative risk patients. The steroids and angiotensin converting enzyme inhibitors may also play a role in the management. Single management strategy is not appropriate for all the cases of CSDH. Better understanding of the nature of the pathology, rational selection of an ideal treatment strategy for an individual patient, and identification of the merits and limitations of different surgical techniques could help in improving the prognosis.

Key words: Chronic subdural hematoma, intracranial subdural hematoma, operative surgical procedure, subdural hematoma

Introduction

Chronic subdural hematoma (CSDH) is one of the most common neurosurgical conditions. The preferred surgical method continues to attract debate. There is lack of uniformity about the treatment strategies, such as the role of burr hole, twist drill, craniotomy, etc., in CSDH amongst various surgeons. There is also disagreement about the use of drain, irrigation, and steroid.^[1,2]

The annual incidence of CSDH is about 1-5.3 cases per 100,000 population. The incidence is increasing due to increase in aging

population, associated medical diseases such as hemodialysis, anticoagulant, and/or antiplatelet therapy.^[3,4] Although the surgical techniques are simple, recurrences remain one of the challenges in the treatment. This review is based on last 21 years search (upto May 2012) on Pubmed and Google.

Presentation

The presentation of CSDH could vary from no symptoms to headache, seizures, decreased memory, and confusion. Patients could have difficulty in speech, swallowing, and walking. There may be weakness or numbness of arms, legs, and face.

The CSDHs are usually characterized by history of head trauma, which is usually a trivial trauma. Some cases could be secondary to defective coagulation, after lumbar puncture (LP), etc., CSDH should be suspected in a patient who presents with unusually persistent headache after spinal anesthesia or LP. CSDH should be taken into account as an important differential diagnosis in reversible dementia. The differentiation between CSDH and dementia could be difficult when it is associated with the hallucinations.^[5]

CSDH generally occurs in elderly although it may present in young patients. It may rarely be seen in infants. The presence of bilateral CSDH in an infant raises the suspicion

Access this article online

Quick Response Code:



Website:

www.asianjns.org

DOI:

10.4103/1793-5482.145102

Address for correspondence:

Dr. Yad Ram Yadav, Department of Neurosurgery,
 NSCB (Government) Medical College, Jabalpur, Madhya Pradesh,
 India. E-mail: yadavyr@yahoo.co.in

of non-accidental trauma and presents a difficult diagnostic challenge because of the legal and social implications. Glutaric aciduria type 1 should be considered in the differential diagnosis of bilateral CSDHs in infants. Some CSDHs of infancy may have a congenital etiology.^[6]

The CSDHs are usually on the most curved frontal or occipital convexity. Bilateral CSDH is common in patients with symmetrical frontal and occipital cranial vault. In asymmetrical cranium, CSDHs are usually on the side of the most curved frontal or occipital convexity which is more frequently on the left side.^[7] Although CSDHs are usually on the convexities, interhemispheric CSDH can also be seen.

Isolated third nerve palsy may also be seen in CSDH. Movement disorders such as choreoathetoid and parkinsonism could be associated with subdural hematomas (SDHs). Pressure effects, neurotransmitter abnormality, and ischemia have been postulated as reasons for this type of presentation. Elderly people suffering from subacute progressive parkinsonism should undergo computed tomography (CT) studies to differentiate it from primary parkinsonism. This parkinsonism is usually completely cured after successful evacuation of the hematomas.^[8] Catatonia could be observed in CSDH. Resolution of the blepharospasm has been observed after evacuation of CSDH. CSDH can cause voiding dysfunctions with small bladder capacity and high-amplitude overactive detrusor contractions with an intact sphincteric response. Spinal CSDH may co-exist with intracranial SDH. Magnetic resonance imaging (MRI) of the spine is indicated in suspicious patients with cranial CSDH.^[9]

Radiology

CSDH is usually diagnosed by CT scan. Hematomas are usually hypodense, but isodense or mixed density lesions are also observed. Although these are usually concavo-convex, rarely they may mimic acute epidural hematomas. These CSDHs could be globular, rarely, due to severe craniocerebral disproportion secondary to associated thin cerebral mantle. Huge hemispheric CSDH, occupying whole cerebral hemisphere and compressing the falx with almost complete obliteration of ipsilateral lateral ventricle, has been reported.^[10]

The calcified CSDHs, though rare, could mimic calvarial mass. Contrast images are essential to find out any associated primary or metastatic dural disease.^[11] The formula $1/2abc$ has been validated to be a relatively reliable method in the estimation of acute subdural, intracerebral, and epidural hematoma. This method could underestimate some CSDH. The formula $2/3Sh$ can be used to estimate SDH volume.^[12] In this, the largest axial hematoma slice area (S) and depth (h) are multiplied by $2/3$. This is a simple, precise, and convenient method for the estimation of volume in all the types of hematomas.

Bilateral isodense CSDH may cause considerable difficulty in diagnosis by CT scan. MRI could help in making the diagnosis of such lesions.^[13] MRI is more sensitive than CT in determining the size and internal structures of CSDH, such as multiple loculations and intrahematoma membranes. Fresh bleeding, hemolysis, and hemoglobin changes can also be observed by MRI. The diffusion tensor imaging can examine anisotropic changes of the pyramidal tracts displaced by CSDH. These anisotropic changes are considered to be caused by a reversible distortion of neuron and vasogenic edema by the hematoma. These changes in the affected pyramidal tract correlate to motor weakness in CSDH.^[14] The diffusion-weighted imaging and enhanced MR imaging are useful for diagnosing infected SDH. Contrast-enhanced MRI could detect neomembranes, thick and extensive membranes, or solid clot.

Differential Diagnosis

SDH could be seen in association with primary dural diseases or metastasis. Such lesions could be missed and could be the cause of recurrence in CSDH. A contrast-enhanced brain CT scan is recommended to diagnose dural metastases. Rosai–Dorfman disease may be mistaken for a CSDH on imaging. This disease is an uncommon, benign systemic histioproliiferative disease characterized by massive lymphadenopathy, particularly in the head and neck region, and is often associated with extranodal involvement. CSDH can also develop in multifocal fibrosclerosis (MFS) which is a rare disorder of unknown etiology, characterized by chronic inflammation with dense fibrosis and lymphoplasmacytic infiltration into the connective tissue of various organs. The mechanism of the formation of CSDH is presumed to involve reactive granular membrane together with subdural collection. On the other hand, the extramedullary erythropoiesis within CSDH can be confused with metastatic malignant tumors, such as lymphoma, carcinoma, and malignant melanoma.

Etiology

Although majority of the CSDHs are due to trauma, intracranial hypotension and defective coagulations could also be responsible.

Post-traumatic

Definite history of trauma could be obtained in majority of the cases. Majority of these cases have mild head injury, although moderate to severe injury could be the causative factor in some cases. This injury could be trivial and may go unnoticed. Some cases could occur after neurosurgical operations. The thin walls of bridging veins, circumferential arrangement of collagen fibers, and a lack of outer reinforcement by arachnoid trabecules contribute to the more fragile nature of bridging vein in the subdural portion as compared to the subarachnoid portion. Repeated injury on the head during play may be the cause of CSDH in children.

CSDH can evolve from acute SDH or subdural effusion (SDE).^[15] Matrix metalloproteinase is thought to play a role in the development of CSDH. About half of the asymptomatic traumatic SDE ultimately evolve into CSDHs. Rupture of bridging veins, bleeding from the hygroma wall due to neocapillaries, vascular hyperpermeability, increased fibrinolysis, and increasing protein content in the hygroma are some of the explanations of the pathogenesis of traumatic SDE evolving into CSDH. Inflammatory cytokines are elevated in SDE and CSDH, as compared with peripheral venous blood. It is hypothesized that SDE and CSDH are different stages, with different appearances, of the same inflammatory reaction.^[16]

Intracranial hypotension

The cerebrospinal fluid (CSF) leakage could cause intracranial hypotension which could lead to CSDH formation.

Spontaneous intracranial hypotension

Spontaneous intracranial hypotension could be the cause of CSDH, especially in young to middle-aged patients, without preceding trauma or hematological disorders. MRI scans of the spine and radionuclide cisternography are useful in the evaluation of intracranial hypotension.^[17] The presence of an underlying spontaneous spinal CSF leak should be considered in CSDH, even among the elderly taking anticoagulants.

CSF rhinorrhea

CSF rhinorrhea could be the cause of the intracranial hypotension leading to CSDH.^[18]

Intracranial hypotension following lumbar puncture, spinal anesthesia, and spine surgery

The possibility of an intracranial SDH as a complication of puncture of the dura mater should be suspected, especially in post LP headache of more than 1 week. Neuroimaging is necessary after 1 week of LP if the patient continues to have headache. CSDH should be considered when postpartum patients, who have received epidural anesthesia, present with mild to severe, persistent, and non-postural headache.^[19] CSDH could occur after microdissectomy complicated by delayed CSF leak.

Intracranial hypotension due to the sudden decompression of intracranial lesion

CSDH can develop due to intracranial hypotension secondary to sudden decompression of intracranial pathologies, such as suprasellar arachnoid cyst fenestration and endoscopic third ventriculostomy.^[20]

Coagulopathy, anticoagulants, and antiplatelet drugs

CSDH could develop in the presence of potential hemorrhagic diathesis due to the deficiency of clotting factors. Factor XIII (FXIII) deficiency may play a pathophysiological role in spontaneous CSDH. FXIII activity should be investigated because it may predict rebleeding events after treatment.

FXIII substitution may prevent recurrence in individuals with considerably low FXIII activity.^[21] CSDH could develop in patients receiving antiplatelet and anticoagulation therapy.^[22]

Pathology

CSDH consists of an outer membrane, hematoma cavity, and an inner membrane. Hematoma fluid is usually liquid that does not clot. Usually hematomas are liquefied, but mixed lesions with solid components are also seen. The higher concentrations of fibrinogen and D-dimer are seen in the layered and mixed types of CSDH. The fibrinolytic factors appear to be associated with evolution in CSDHs with heterogeneous density.^[23]

Usually there is no infection in these hematomas, but the CSDH is a potential site for bacterial infection. The possibility of infected SDH should be considered when a patient has features of infection.^[24]

The developing hematoma capsule shows gradual changes in cellular and vascular organization with progression in hematoma age. Initial changes include angiogenic and aseptic inflammatory reactions. It is followed by fibroblasts-proliferation and development of collagen fibrils. Young hematomas (15-21 days after trauma) show numerous capillaries, suggesting formation of new blood vessels. Older hematomas (40 days after trauma) usually show numerous capillaries and thin-walled sinusoids accompanied by patent, larger diameter blood vessels. Blood vessels are frequently occluded by clots in the fibrotic outer membrane of 60 or more days old hematoma.^[25] The outer capsule may calcify or ossify in some cases.

CSDHs cause decrease in the blood flow in the underlying brain. The drainage of the hematoma results in the improvement of cerebral blood flow and clinical recovery.^[26] The CSDH could be associated with reversible distortion of the underlying nerve fibers and vasogenic edema.^[14] Cranial CSDH could be associated with spinal CSDH in intracranial hypotension.^[9]

Expansion of Hematoma

The pathology of the enlargement of the CSDH is very complex. It is likely that multiple factors are responsible for the maintenance and enlargement of the CSDH, the relative importance of which varies from case to case. There is a great variety of subdural fluid types, ranging from bright red liquid through to thick engine oil to light serous fluid. Similarly, some CSDHs contain a very thick outer membrane, whereas in others the membrane is hardly visible with the naked eye.

The complex nature of CSDH pathology can be explained by the recurrence of hematoma even after complete removal of hematoma and outer membrane where as even the partial removal of the clot can lead to complete resolution of the hematoma and the membrane.^[27]

Rebleeding, exudates from the outer membrane, osmotic theory, and rapid enlargement due to CSF entrapment are considered as possible causes of expansion of hematomas.

Rebleeding

The CSDH enlarges from recurrent bleeding in the subdural space, caused by local angiogenesis, inflammation, defective coagulation, and ongoing fibrinolysis. Rebleeding from thin-walled sinusoidal blood vessels in the outer neomembrane has been proposed.^[28] Ito *et al.* estimated that the new hemorrhages accounted for about 6.7% of the hematoma content.^[29]

Coagulopathy, anticoagulants, and anti-platelet drugs

Excessive coagulation in the hematoma is considered for the progressive enlargement of CSDH. High fibrinogen degradation product (FDP) has been detected due to hyperfibrinolysis in CSDH. There is reduction in clotting factors II, V, VII, VIII, IX, X, XI, and XII.^[28] High tissue plasminogen activator (tPA) concentrations in the subdural fluid and outer membrane could cause rebleed and such patients have a relatively high probability of recurrence.^[30] Plasminogen activator inhibitor type I (PAI-1) deficiency could be responsible for recurrent CSDH.^[31]

Local inflammation and angiogenesis

Local inflammatory process in CSDH results in the formation of a granulation tissue often referred to as the external or outer membrane.^[16]

Significantly higher levels of the proinflammatory (interleukin (IL)-2R, IL-5, IL-6, and IL-7) and anti-inflammatory mediators (IL-10 and IL-13) have been reported in CSDH fluid, as compared with systemic levels. The proinflammatory tumor necrosis factor (TNF)- α , IL-1 β , IL-2, and IL-4 are significantly lower in hematoma fluid, compared with systemic levels. The ratios between proinflammatory and anti-inflammatory cytokines are significantly higher in CSDH as compared to systemic levels. These findings suggest that the local hyper-inflammatory and low anti-inflammatory responses exist simultaneously. They also suggest poorly coordinated innate immune responses at the site of CSDH. This response may lead to propagation of local inflammatory process which could contribute to formation and progression of CSDH.^[32] Local inflammation seems to be responsible for continuous bleeding by capillary exudation in the earlier phase. Various inflammatory markers such as IL-6, IL-10, and chemokines have been found to be elevated in CSDH and are implicated in the genesis of CSDH.^[33,34]

Angiogenesis appears to render maturation of the outer membrane by sprouting vascular networks in the later phase of CSDH formation. Enhanced expression of angiogenic growth factors such as vascular endothelial growth factor (VEGF) and basic fibroblast growth factor (bFGF) in the

outer membrane is associated with expansion of CSDH and recurrence.^[33] Hypoxia-inducible factor-1 α (HIF-1 α) release and VEGF could be responsible for excessive development of fragile microvessels and hyperpermeability, resulting in the enlargement of CSDH.^[35] The cyclooxygenase-2 (COX-2) pathway has been shown to influence angiogenic factors. COX-2 may play a crucial role during the development of CSDHs.^[36]

Chemokines as markers of local inflammation and angiogenesis are elevated in CSDH. The biological activity of chemokine ligand 2 (CCL2) and chemokine ligand CXCL8 may promote neovascularization within the outer membrane, and a compensatory angiostatic activity of chemokine ligand 9 (CXCL9) and chemokine ligand 10 (CXCL10) may contribute to repairing in this disorder.^[37]

Increased exudates from outer membrane

Exudation from microcapillaries in the outer membrane of CSDH could play an important role in the pathophysiology and the growth of CSDH.^[38] The increased aquaporin 1 (AQP1), responsible for water transport in the outer membrane of CSDH, might be the source of the increased fluid accumulation in CSDH enlargement.^[39]

Osmotic theory

The osmotic theory of the maintenance and growth of CSDH, introduced by Gardner and later modified by Zollinger and Gross, has been largely abandoned after Weir's publications.

CSF entrapment

The SDH's enlargement could be due to flow of CSF through some areas of the inner membrane and entrapment of CSF in the cavity.^[40]

Risk Factors for CSDH

The risk factors of CSDH include long-term heavy alcohol use, long-term use of aspirin, anti-inflammatory drugs such as ibuprofen, or anticoagulant medication. The diseases associated with reduced blood clotting, head injury, and old age also increase the risk.

The incidence of CSDH is more in arachnoid cyst. The incidence of this complication is about 6.5% in the temporal cysts.^[41] The patients with arachnoid cyst should avoid violent sports to reduce the incidence of intracranial hemorrhage. Aneurysm may rupture into an arachnoid cyst and may present as a CSDH. Such aneurysms may rupture during burr-hole drainage of CSDH.^[42]

Treatment

Surgery is the treatment of choice in most of the CSDHs. Some of these patients could be managed conservatively, especially small hematomas after antiplatelet drug use. There are observations of the normal mean subdural pressure in CSDH.^[43]

Some of the small CSDHs after antiplatelet drug use can be managed conservatively by stopping the antiplatelet drugs and follow-up with repeat CT scans. When surgery is necessary, its delay, if patient's condition permits, allows metabolizing the drug and platelet renewal. This delay could minimize the risk of hemorrhage. If urgent burr holes are indicated, measures to improve platelet function should be undertaken.^[44] There is general agreement that significant coagulopathy should be reversed expeditiously in CSDH before surgery is undertaken.^[45]

Recombinant activated factor VII (rFVIIa) has recently gained popularity for rapid reversal of coagulopathy during CSDH surgery. Some of the patients with normal International Normalized Ratio (INR) can have excessive intraoperative coagulopathic bleeding. Normal INR should not be a deterrent for patients to receive rFVIIa in the setting of strong neurosurgical suspicion for underlying clinical coagulopathy.^[46] There is increased risk of intraoperative bleeding in patients who are on anticoagulants. There is also a risk of complications if anticoagulants are stopped in some patients. The optimal time to restart full-dose anticoagulation, when indicated, after recently drained CSDH, is yet to be decided.^[45]

Spontaneous Resolution

CSDHs with idiopathic thrombocytopenic purpura may resolve spontaneously or with medical treatment. Surgery might be deferred except in emergency conditions or in patients with neurological deficit. Close neurological and radiological observation along with the medical treatment could be appropriate in patients with normal neurological findings.^[47] Nontraumatic SDHs or hygromas in infants can often experience significant resolutions within several months without surgical treatment.^[48] Spontaneous resolution of post-traumatic CSDH in patients without any associated coagulopathy, though rare, can occur. Careful conservative treatment can be considered if the patient's neurological and physical conditions allow.^[49]

Administration of platelet-activating factor receptor antagonist, Etizolam, can promote CSDH resolution, especially in the stage of hygroma. Surgery is recommended if the patient presents with motor weakness.^[50] A Kampo medicine (Japanese traditional herbal medicine), Gorei-san, has been found to be a useful option in the conservative treatment of CSDHs, with no or minimum symptoms in CSDH.^[51] Coagulation factor deficiency should be investigated and corrected to prevent recurrence.^[21] The development of anti-COX-2 treatment options could reduce morbidity and recurrence rate in CSDH.^[36]

Seizure Prophylaxis

Although there is conflicting evidence about seizure prophylaxis in CSDH, anti-epileptic drug (AED) prophylaxis

could be given in higher-risk patients.^[45] The mortality is high in postoperative seizure cases, therefore seizure prophylaxis should be given in high-risk patients (low Glasgow Coma Scale (GCS) and preoperative cognitive impairment).^[52] Lower mean GCS on admission is predictive of seizures in CSDH.^[53] The preoperative AED prophylaxis is likely to reduce the incidence of postoperative seizures in CSDH.^[54]

Role of Steroid in CSDH

Although surgery is required in CSDH with moderate or severe neurological deficit, corticosteroids could be used in mild neurological deficit subgroups. The current evidence neither supports nor refutes the use of corticosteroids in CSDH.^[55] Although there is a lack of well-designed trials that support or refute the use of corticosteroids in CSDH, five observational studies suggest that corticosteroids might be beneficial in the treatment of CSDH.^[56] Extended preoperative corticosteroid use along with the burr-hole craniostomy is associated with a lower recurrence rate.^[57] Postoperative use of corticosteroid has been associated with better survival.^[58] The use of corticosteroids does not seem to be related to higher incidence of complications and treatment-related death.^[57] Dexamethasone has been found to be safe option and it has cured or improved two-thirds of the patients in retrospective studies. The true effectiveness of the therapy as compared to surgical treatment should be tested in a prospective randomized trial.^[59] Steroid treatment in patients with co-morbidity is a good option.^[60] The oral corticosteroid therapy is very effective in CSDH due to MFS.

The role of appropriate hydration in subarachnoid hemorrhage is well recognized. Intravenous fluid administration of at least 2000 ml for 3 days postoperatively has been found to be associated with better clinical outcome and reduced recurrence in CSDH.^[61] The appropriate fluid delivery may facilitate brain re-expansion, thus avoiding hematoma recurrence and accelerating patient recovery.

Surgery

Surgery is the best option in moderate to large hematoma with neuro deficit. One surgical technique may not be appropriate for all CSDHs. The selection of an ideal treatment strategy for an individual patient should be the target.^[62] Removal of CSDH is enough in most of the patients with associated arachnoid cysts.^[63]

Anesthesia

Burr-hole surgery can be done under local anesthesia in most of the patients. The surgery for CSDH under monitored anesthesia using conscious sedation has been found to be safe and effective in some cases. Conscious sedation using monitored anesthesia care may facilitate patient comfort and surgical competence in CSDH.^[64]

Head Position After Surgery

The incidence of the atelectasis, pneumonia, decubitus ulcer, and deep vein thrombosis could be more if patients are kept in supine position postoperatively, especially in elderly. A 30° head-up position soon after operation in CSDH does not significantly affect the outcome and recurrence.^[65] Early mobilizing after surgery could prevent postoperative pneumonia and urinary tract infection without increasing the risk of recurrence in elderly patients of 65 years or more.^[66] Some authors, on the other hand, do not recommend upright position soon after surgery because the incidence of postoperative atelectasis, pneumonia, decubitus ulcer, and deep vein thrombosis is the same in 30°-40° sitting position and supine position, but the recurrence rates are significantly more in upright position.^[67]

The Subdural Evacuating Port System

The subdural evacuating port system (SEPS) is a technique for the treatment of hygromas, chronic and subacute SDHs. SEPS can be done at the bedside under local anesthesia using a small drill hole. SEPS allows for the gradual re-expansion and recovery of the brain. This port does not enter the subdural space and avoids the risk of brain penetration. There is no need for irrigation in this system. SEPS provides a closed system for hematoma evacuation by gradual decompression using a uniform negative extradural pressure. The SEPS is a safe and effective alternative treatment option in elderly or sick patients who might not tolerate the physiological stress of a craniotomy or burr hole under general anesthesia. It is more effective in the hypodense subdural collections as compared to the mixed density collections. Significant bleeding after SEPS insertion, though uncommon, can occur.^[68] The efficacy and safety of SEPS is similar to that of other twist drill or burr-hole methods.^[69] The appearance of the winged cannula in the diploic space helps the radiologist to identify it.^[70]

Another minimally invasive technique of placement of hollow screws, under local anesthesia, could be an effective treatment in most cases of the CSDH. About 20% may need burr-hole surgery after treatment with hollow screws.^[71]

Drainage

Considerable body of evidence supporting the use of external drainage after evacuation of primary CSDH exists in most of the reported series.^[72-77] Santarius *et al.*,^[75] Ramachandran *et al.*,^[78] Wakai *et al.*,^[79] Tsutsumi *et al.*,^[80] Gurelik *et al.*^[81] and Sarnivvad *et al.*^[82] reported 9.3%, 4%, 5%, 3.1%, 10.5%, and 16% recurrence rates, respectively, in the drainage group, as compared to 24%, 30%, 33%, 17%, 19%, and 26%, respectively, in without drain group [Chart 1]. Continuous drainage therapy for CSDH is superior to the one-time drainage method, with shorter post-op hospitalization and low recurrence.^[73,74]

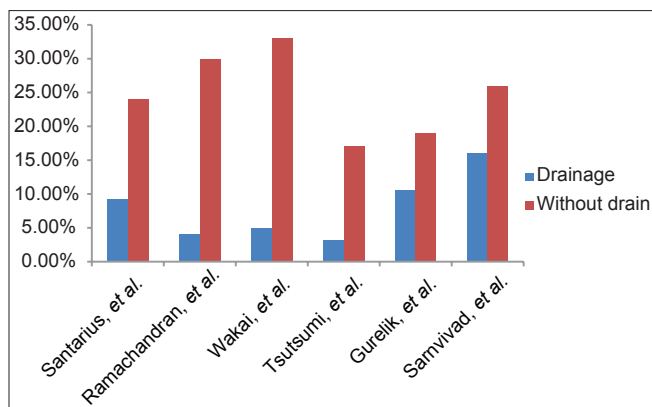


Chart 1: Recurrence rate with and without drainage

Santarius *et al.*^[75] also reported lower 6 months mortality of 8.6% in the drain group, as compared to 18.1% when drain was not used. On the other hand, there was no significant difference in the postoperative recurrence and the complication rates in drainage and without drainage groups in other studies.^[83,84] Advocates of no drain group argue that placing a drain could lead to complications such as brain injury, hemorrhage from neomembranes, and infection without reducing recurrence. Subdural empyemas have been reported after subdural drain.^[84-88] Postoperative infection in the subgaleal space has also been reported after drainage.^[89]

Types of Drainage

Various types of the drainage, such as the subdural, the subperiosteal, and the subgaleal drainage, are being used for continuous drainage after surgery. Now there are reports of better results when the drain is left above the skull as compared to when it is kept under the dura. Both the subdural and subperiosteal methods are found to be highly effective, but the mortality and serious complications are less in subperiosteal drainage.^[90] The subperiosteal closed drainage system is a technically easy, safe, and cost-efficient treatment strategy for CSDH. The absence of a drain in direct contact with the hematoma capsule may reduce the risk of postoperative seizure and limit the secondary spread of infection to intracranial compartments.^[91] Although the mortality and the complications of the subperiosteal drain were lower than the subdural drain, the recurrence rate was more in subperiosteal drain as compared to subdural drain in some reports.^[90,91]

Subgaleal suction drain is also an effective, simple, and safe method. It significantly reduces the incidence of recurrence.^[89] Although subgaleal drainage generally avoids the risk of an acute hemorrhage from neomembrane injury, which may occur during introduction and the removal of a subdural drain, there is a report of one acute SDH after drain.^[89] It also reduces the chances of brain parenchymal injury which could result from a blind placement of the subdural drain.

Duration of Drainage

There are controversies regarding duration of drainage in CSDH. There are reports in favor of 48-h closed drainage system, as compared to longer period drainage.^[92] Not only is the bed rest reduced, but the rate of morbidities is also significantly decreased.^[93] On the other hand, high recurrence rate was observed in less than 3 days drainage group as compared to more than 3 days drainage group. Prolonged duration of drainage did not increase the frequency of infection. The 3 days of drainage seem to be necessary, especially for elderly patients of 60 years and more. It is presumed that it takes at least 3 days of drainage for the termination of the vicious cycle and resolution of the hematoma by the restoration of a normal balance between coagulation and fibrinolysis after surgery.^[94]

Irrigation

There is controversy regarding the use of irrigation in CSDH. Irrigation and drainage are aimed to reduce recurrence in CSDH.^[81] The burr-hole drainage with irrigation is associated with good outcomes and lower recurrence rate, as compared to drainage alone.^[95] Irrigation with large amount of fluid during surgery may reduce the recurrence rate in CSDH.^[96] On the other hand, the outcome with or without irrigation has been found to be the same in CSDH managed by the drainage system.^[97]

Twist Drill Craniostomy

The TDC drainage is indicated in high-risk surgical candidates in non-septated CSDH.^[45] TDC can be performed at the bedside and is effective in treating CSDHs.^[98] The results of TDC in terms of recurrence rates, morbidity, and mortality, are the same as compared to burr-hole craniostomy.^[99,100]

Although TDC for evacuation of a CSDH is a rapid and minimally invasive procedure, it carries the risk due to its blind nature. Some of these patients can have inadequate drainage, brain penetration, acute epidural hematoma, and catheter folding. High recurrence rate was observed in TDC.^[101] These complications can be prevented by doing some modifications in the technique. Size of the drill and irrigation catheter should be more to avoid inadequate drainage. The increased angle of skull penetration can reduce brain penetration chances. The risk of extradural hematoma due to separation of dura mater from skull can be reduced by pointed drill and entry of subdural space by sudden push. Insertion of catheter with Kirschner wire can prevent catheter folding.^[102] Posterior positioning of the drill at parietal tuberosity can reduce brain penetration chances. Skull entry at the most curved position on the skull could also prevent brain penetration. This allows direct entry of the catheter in hematoma cavity only, rather than brain. One of the major concerns in TDC is bleeding from dura mater, especially from middle meningeal artery. Dural penetration at

the middle meningeal artery should be avoided by suitable entry point 1 cm anterior to the coronal suture at the level of the superior temporal line.^[103]

Burr-hole

Burr-hole craniostomy is the most efficient choice for surgical drainage of uncomplicated CSDH [Table 1]. Burr-hole craniostomy is associated with a low recurrence rate and lesser complications.^[100,104-107] Treatment of CSDH through a burr-hole irrigation and closed-system drainage under local anesthesia is simple, safe, and effective.^[108] Surgeons differ in their choice regarding usage of one or two burr holes. The one burr hole craniostomy with closed drainage could be sufficient to evacuate CSDH with lower or similar recurrence rate, as compared to two burr hole group.^[109-111] On the other hand, treatment of CSDH with one burr hole has been found to be associated with a significantly higher postoperative recurrence rate, longer hospitalization length, and higher wound infection rate, as compared to treatment with two burr hole.^[112]

Biopsy of Dura Mater

Malignancy could be associated with CSDH. Resection of the involved dura and biopsy is obligatory for the diagnosis and appropriate palliative management of such patients. It should be suspected especially in recurrent lesions.^[113]

Craniotomy

Craniotomy is indicated in CSDH with significant membranes,^[45] multiloculated,^[114] organized,^[115,116] and calcified or ossified CSDH.^[117-119] Although an ossified membrane could be excised^[118] or drilled by high-speed air drilling,^[119] the optimal surgical procedure for such CSDH has not been established because it is hard to obtain brain re-expansion after surgery. The residual rigid inner and outer membranes facilitate dead space and hematoma recurrence. Multiple tenting procedures could help in obliteration of the dead space in a large CSDH to prevent recurrence.^[117]

Small craniotomy with irrigation and closed-system drainage can be considered as one of the treatment options in CSDH.^[120] Duration of postoperative hospital stay, complications, and recurrence rate have been found to be statistically lower in small craniotomy group as compared to one or two burr hole craniostomy group. Large craniotomy with extended membranectomy technique could be required to reduce the recurrence rate in non-liquefied hematoma, multilayer intrahematoma loculations, and organized or calcified CSDH, as compared to small craniotomy with partial membranectomy technique.^[121]

Endoscopic Treatment

Endoscopic treatment is indicated in removal of solid clots under direct vision in organized and multiloculated CSDH.^[122,123] Endoscopic treatment could make the procedure safer with

Table 1: Summary of the management of chronic subdural hematoma

Treatment	Surgery is the treatment of choice in most of the symptomatic patients with neuro deficit Nonsurgical management is reserved for small asymptomatic or high operative risk patients, especially in small hematomas associated with antiplatelet or anticoagulant drugs use Significant coagulopathy should be reversed expeditiously before surgery is undertaken The steroids and ACE inhibitors may also play a role in the management of chronic subdural hematoma (CSDH)
Head position after surgery	Controversy exists about ideal head position after surgery Early mobilizing and 30°-40° sitting after surgery could prevent postoperative complications without increasing the risk of recurrence, especially in elderly patients
Burr hole	Burr-hole craniostomy is the most efficient choice for surgical drainage of uncomplicated CSDH
Craniotomy	Craniotomy is indicated in significant membranes, in multiloculated, organized, calcified or ossified CSDH
Twist drill	Twist drill craniostomy drainage is indicated in high-risk surgical candidates in non-septated CSDH
Endoscopic management	Endoscopic treatment could be indicated in organized and in multiloculated CSDH
Biopsy of dura mater	Biopsy is required for the diagnosis and appropriate palliative management, especially in recurrent lesions and thick outer membrane
Drainage	Most of the recent trials favor the use of drain to reduce recurrence rate
Type of drain	The drain above the skull (subperiosteal or subgaleal) is better as compared to subdural drain
Prognosis	The mortality is about 2% in CSDH. Long-term mortality continues up to 1 year after treatment in elderly patients due to associated chronic diseases The prognosis of CSDH depends on the age, GCS at presentation, and associated illnesses like cardiac and renal failure
Complications and avoidance	Recurrence, development of new intracranial hematoma, infection, seizure, cerebral edema, tension pneumocephalus, and failure of the brain to expand Slow and simultaneous bilateral decompression of massive CSDHs is recommended to prevent secondary intracranial hematoma Tension pneumocephalus can be prevented by saline replacement, use of suction drain, avoiding nitrous oxide anesthesia, and positioning of burr hole at the highest point during closure. The risk of pneumocephalus can be reduced by the skin closure immediately after cessation of spontaneous blood efflux, Valsalva maneuver, and use of gravity in 30° Trendelenburg position
Recurrence and its avoidance	Recurrences could be due to primary or metastatic dural pathology, intracranial hypotension, thick outer membrane, brain remaining at a depth at the end of evacuation of hematoma, high levels of tissue plasminogen activator in the subdural fluid and outer membrane, lower GCS, pneumocephalus, high- or mixed-density hematoma, higher concentrations of IL-6 in the fluid, enhanced expression of vascular endothelial growth factor and basic fibroblast growth factor in the outer membrane, more linoleic acid concentration in fluid, antiplatelet or anticoagulant drugs, and infection Replacement of the hematoma with oxygen or saline, continuous postoperative drainage, treatment of intracranial hypotension, embolization of vascular capsule, irrigation of the cavity with thrombin solution and tissue plasminogen activator, and correction of defective coagulation in appropriate case could avoid recurrences Continuous drainage, proper postoperative hydration, excision of the constricting thick membrane, prevention of pneumocephalus, and use of gravity can help the brain to re-expand

GCS – Glasgow coma scale

enhanced intraoperative visualization. It may allow the identification and destruction of neomembranes.

Prognosis

The mortality rate is about 2% in CSDH.^[106] Although CSDH is a benign disease, it is usually associated with other underlying chronic diseases. Long-term mortality continues up to 1 year after treatment in elderly patients due to these associated chronic diseases.^[124] The prognosis in CSDH depends on the age, GCS at presentation, and associated illnesses like cardiac and renal failure. Prognosis is superior in better preoperative GCS^[125] and in younger^[126] patients. Duration of symptoms does not have any effect on the mortality or morbidity.^[78]

Complications

CSDH could be associated with recurrence, infection, new intracranial hematoma, seizure, cerebral edema, tension

pneumocephalus, and failure of the brain to expand due to cranio-cerebral disproportion.^[127] Although there is a potential risk of pneumocephalus after all surgical techniques in the treatment of CSDH, it is seen in 11% of cases.^[106] Tension pneumocephalus could occur after evacuation of a CSDH.^[128,129] The amount of subdural air is correlated negatively with the resolution of a CSDH.^[130] It impedes the adhesion between the inner and outer membranes, prolonging the widening of the subdural space, thus promoting postoperative re-accumulation. The subgaleal or subdural drain could minimize recurrences by preventing the collection of subdural air.^[89] Intraoperative saline flushing, positioning of burr hole at the highest point on the skull, and avoiding nitrous oxide anesthesia could help in preventing pneumocephalus.^[128,131] The risk of pneumocephalus can be reduced by the skin closure immediately after cessation of spontaneous blood efflux. Valsalva maneuver and use of gravity in 30° Trendelenburg position, rather than suction, are helpful in avoiding

pneumocephalus.^[66] Brain herniation through membrane can also be seen.^[132] Microorganisms like *Klebsiella pneumoniae* may directly infect the subdural space.^[133]

New Intracranial Hematoma

Intracerebral and intraventricular hemorrhages can develop after removal of CSDHs. Possible mechanisms include a sudden increase in cerebral blood flow within fragile cerebral vessels, defective vascular autoregulation, and damage to the cerebrovascular tree. Asymmetrical and rapid decompression could lead to vascular disruption and/or sudden increase in cerebral blood flow.^[134] Combined epidural and intracerebral hemorrhage can occur immediately after evacuation of bilateral CSDH.^[135] Hematomas could develop on the opposite side^[136] or at any remote^[137] place. Slow and simultaneous bilateral decompression of massive CSDHs is recommended to prevent secondary intracranial hematoma.^[134]

Recurrence

Incidence of recurrence is between 5 and 33% after surgery.^[72,106,138] Late recurrences are more common in the aged patients. Recurrence is significantly more common in the thick hematomas. Early recurrence is defined as return of symptoms or re-accumulation of the hematoma after a surgery within 3 months. Late recurrence can be defined as reappearance or enlargement of a liquefied hematoma or persistent CSDH 3 months after surgery.^[139]

Etiology of Recurrences

The etiologies of hematoma recurrence are not exactly known. Many factors seem to be responsible for the recurrence. Removal of outer membrane does not eliminate the risk of recurrence while partial removal of hematoma could lead to total disappearance of membrane and hematoma.^[27] Postoperative midline shift of 5 mm or more, diabetes mellitus, preoperative seizure, and preoperative width of 20 mm or more are the predictors of recurrence in CSDH. The rate of recurrence is lower in the homogeneous and the trabecular type, as compared to the laminar or multilayered type hematoma.^[138] High- and mixed-density lesions are associated with a high incidence of recurrence.^[140]

Primary and metastatic diseases of the dura mater can give rise to malignant SDE and recurrence.^[113] Intracranial hypotension could give rise to recurrence in CSDH.^[141] MRI of the spine and/or radionuclide cisternography is useful in the evaluation of intracranial hypotension and to avoid recurrences.^[17] Thick subdural membranes visualized during surgery and brain remaining in the depth at the end of surgery are associated with increased recurrence.^[78] Lower GCS and presence of intracranial air 7 days after surgery are related with increased recurrence in CSDH.^[142,143]

High levels of tPA in the subdural fluid and outer membrane have a relatively high probability of recurrence.^[30] Angiogenic growth factors and inflammatory cytokines are associated with increased recurrence. Higher concentration of IL-6 in the subdural fluid or enhanced expression of VEGF and bFGF in the outer membrane is more likely to be associated with recurrence. Local inflammation seems to be responsible for continuous bleeding by capillary exudation in the earlier phase, whereas angiogenesis appears to render maturation of the outer membrane by sprouting vascular networks in the later phase.^[33,144]

Change in fatty acid composition with more linoleic acid is associated with rebleeding.^[145] Antiplatelet or anticoagulant drugs might facilitate the recurrence of CSDH.^[146] Irrigation with small amount of fluid during surgery may increase the recurrence rate of CSDH.^[96] Poor brain re-expansion rate could be responsible for a higher recurrence rate in CSDH, especially in bilateral hematoma.^[147] Continuous drainage, proper postoperative hydration, prevention of pneumocephalus, and use of gravity can help the brain to re-expand. Excision of the constricting thick membrane in selected patients can help the brain to re-expand. The recurrence could be due to entrapment of CSF in the hematoma cavity through some areas of the inner membrane.^[40] *Campylobacter fetus* infection could play a role in the recurrence of hematoma because of its vessel tropism.^[148]

Methods to Reduce Recurrence

Replacement of the hematoma with oxygen is a useful method for the treatment of CSDH, which has been associated with reduced recurrence rate.^[149] A subgaleal suction drainage allows continuous drainage of the remaining hematoma and has been found to be associated with low rate of recurrence and complications. It is relatively less invasive and can be used in high-risk patients.^[89] Intravenous fluid administration of at least 2000 ml for 3 days postoperatively has been found to be associated with reduced recurrence in CSDH.^[61]

Simultaneous closure of the CSF dural fistula at the time of evacuation of a coexisting CSDH should be the optimal management. Management of only CSDH without repair of CSF leak could result in recurrence.^[18] Embolization of the middle meningeal artery is considered to be useful to eliminate the blood supply to hematoma capsule and prevent recurrence in intractable recurrent cases.^[150,151]

The angiotensin converting enzyme (ACE) inhibitor treatment lowers the risk of recurrence in CSDH. This could be due to an anti-angiogenic mechanism of ACE inhibitors.^[152] It has been seen that the inadequate amount of hematoma evacuation is associated with recurrence: Irrigation with thrombin solution^[153] and the addition of tPA in the irrigation fluid^[154] reduced the recurrence rate. This increases the amount of drainage after hematoma

evacuation, especially in residual solid clot. Irrigation with large amount of fluid during surgery reduces the recurrence rate in CSDH.^[96] Deficiency of coagulation factors such as factor XIII could be responsible for the recurrence. FXIII substitution may prevent recurrence in individuals with considerably low FXIII activity.^[21] Recurrent CSDH could be due to PAI-1 deficiency. PAI-1 deficiency can be treated with an oral course of aminocaproic acid.^[31]

References

- Santarius T, Lawton R, Kirkpatrick PJ, Hutchinson PJ. The management of primary chronic subdural haematoma: A questionnaire survey of practice in the United Kingdom and the Republic of Ireland. *Br J Neurosurg* 2008;22:529-34.
- Cenic A, Bhandari M, Reddy K. Management of chronic subdural hematoma: A national survey and literature review. *Can J Neurol Sci* 2005;32:501-6.
- Karibe H, Kameyama M, Kawase M, Hirano T, Kawaguchi T, Tominaga T. Epidemiology of chronic subdural hematoma. *No Shinkei Geka* 2011;39:1149-53.
- Krupa M. Chronic subdural hematoma: A review of the literature. Part 1. *Ann Acad Med Stetin* 2009;55:47-52.
- Jobse IC, Feitsma MT. Presentation of chronic subdural hematoma in the elderly. *Tijdschr Gerontol Geriatr* 2011;42:139-43.
- Galaznik JG. A case for an in utero etiology of chronic SDH/effusions of infancy. *J Perinatol* 2011;31:220-2.
- Kim BG, Lee KS, Shim JJ, Yoon SM, Doh JW, Bae HG. What determines the laterality of the chronic subdural hematoma? *J Korean Neurosurg Soc* 2010;47:424-7.
- Bostantjopoulou S, Katsarou Z, Michael M, Petridis A. Reversible parkinsonism due to chronic bilateral subdural hematomas. *J Clin Neurosci* 2009;16:458-60.
- Hagihara N, Abe T, Kojima K, Watanabe M, Tabuchi K. Coexistence of cranial and spinal subdural hematomas: Case report. *Neurol Med Chir (Tokyo)* 2010;50:333-5.
- Mishra A, Ojha BK, Chandra A, Srivastava C, Singh SK. Giant unusual shaped chronic subdural hematoma in a patient with untreated congenital hydrocephalus. *Asian J Neurosurg* 2011;6:121-2.
- Cheng YK, Wang TC, Yang JT, Lee MH, Su CH. Dural metastasis from prostatic adenocarcinoma mimicking chronic subdural hematoma. *J Clin Neurosci* 2009;16:1084-6.
- Zhao KJ, Zhang RY, Sun QF, Wang XQ, Gu XY, Qiang Q, et al. Comparisons of 2/3Sh estimation technique to computer-assisted planimetric analysis in epidural, subdural and intracerebral hematomas. *Neurol Res* 2010;32:910-7.
- Agrawal A. Bilateral biconvex frontal chronic subdural hematoma mimicking extradural hematoma. *J Surg Tech Case Rep* 2010;2:90-1.
- Yokoyama K, Matsuki M, Shimano H, Sumioka S, Ikenaga T, Hanabusa K, et al. Diffusion tensor imaging in chronic subdural hematoma: Correlation between clinical signs and fractional anisotropy in the pyramidal tract. *AJNR Am J Neuroradiol* 2008;29:1159-63.
- Park SH, Lee SH, Park J, Hwang JH, Hwang SK, Hamm IS. Chronic subdural hematoma preceded by traumatic subdural hygroma. *J Clin Neurosci* 2008;15:868-72.
- Feng JF, Jiang JY, Bao YH, Liang YM, Pan YH. Traumatic subdural effusion evolves into chronic subdural hematoma: Two stages of the same inflammatory reaction? *Med Hypotheses* 2008;70:1147-9.
- Takahashi T, Senbokuya N, Horikoshi T, Sato E, Nukui H, Kinouchi H. Refractory chronic subdural hematoma due to spontaneous intracranial hypotension. *No Shinkei Geka* 2007;35:799-806.
- Poonnoose SI, Manjooran RP, Mathew J, Ramachandran P. Chronic subdural haematoma associated with nontraumatic CSF rhinorrhea: A management challenge. *J Clin Neurosci* 2007;14:281-3.
- Fujii M, Arai T, Matsuoka Y, Karakama J, Morimoto T, Ohno K. Postpartum chronic subdural hematoma following spinal anesthesia: Case report. *No Shinkei Geka* 2010;38:563-8.
- Tekin T, Colak A, Kutlay M, Demircan MN. Chronic subdural hematoma after endoscopic third ventriculostomy: A case report and literature review. *Turk Neurosurg* 2012;22:119-22.
- Bosche B, Molcanyi M, Noll T, Kochanek M, Kraus B, Rieger B, et al. Occurrence and recurrence of spontaneous chronic subdural haematoma is associated with a factor XIII deficiency. *Clin Neurol Neurosurg* 2012.
- Vuk A, Stancić V, Rincić G, Ledinsky M, Grbac L, Stancić N. Nontraumatic bilateral subdural hematoma caused by antiaggregation therapy: Case report and review of the literature. *Acta Clin Croat* 2010;49:163-8.
- Park SH, Kang DH, Park J, Hwang JH, Hwang SK, Sung JK, et al. Fibrinogen and D-dimer analysis of chronic subdural hematomas and computed tomography findings: A prospective study. *Clin Neurol Neurosurg* 2011;113:272-6.
- Iimura Y, Tsutsumi S, Mitome Y, Nonaka Y, Abe Y, Yasumoto Y, et al. Infantile chronic subdural hematoma infected by *Escherichia coli*: Case report. *Neurol Med Chir (Tokyo)* 2010;50:482-4.
- Moskala M, Goscinski I, Kaluza J, Polak J, Krupa M, Adamek D, et al. Morphological aspects of the traumatic chronic subdural hematoma capsule: SEM studies. *Microsc Microanal* 2007;13:211-9.
- Kaplan M, Erol FS, Bozgeyik Z, Koparan M. The effectiveness of simple drainage technique in improvement of cerebral blood flow in patients with chronic subdural hemorrhage. *Turk Neurosurg* 2007;17:202-6.
- Krupa M. Chronic subdural hematoma: A review of the literature. Part 2. *Ann Acad Med Stetin* 2009;55:13-9.
- Shim YS, Park CO, Hyun DK, Park HC, Yoon SH. What are the causative factors for a slow, progressive enlargement of a chronic subdural hematoma? *Yonsei Med J* 2007;48:210-7.
- Ito H, Yamamoto S, Saito K, Ikeda K, Hisada K. Quantitative estimation of hemorrhage in chronic subdural hematoma using the ⁵¹Cr erythrocyte labeling method. *J Neurosurg* 1987;66:862-4.
- Katano H, Kamiya K, Mase M, Tanikawa M, Yamada K. Tissue plasminogen activator in chronic subdural hematomas as a predictor of recurrence. *J Neurosurg* 2006;104:79-84.
- Rughani AI, Holmes CE, Penar PL. A novel association between a chronic subdural hematoma and a fibrinolytic pathway defect: Case report. *Neurosurgery* 2009;64:E1192; discussion E1192.
- Stanisic M, Aasen AO, Pripp AH, Lindegaard KF, Ramm-Petersen J, Lyngstadaas SP, et al. Local and systemic pro-inflammatory and anti-inflammatory cytokine patterns in patients with chronic subdural hematoma: A prospective study. *Inflamm Res* 2012;61:845-92.
- Hong HJ, Kim YJ, Yi HJ, Ko Y, Oh SJ, Kim JM. Role of angiogenic growth factors and inflammatory cytokine on recurrence of chronic subdural hematoma. *Surg Neurol* 2009;71:161-5.
- Wada T, Kuroda K, Yoshida Y, Ogasawara K, Ogawa A, Endo S. Local elevation of the anti-inflammatory interleukin-10 in the pathogenesis of chronic subdural hematoma. *Neurosurg Rev* 2006;29:242-5.
- Nanko N, Tanikawa M, Mase M, Fujita M, Tateyama H, Miyati T, et al. Involvement of hypoxia-inducible factor-1 α and vascular endothelial growth factor in the mechanism of development of chronic subdural hematoma. *Neurol Med Chir (Tokyo)* 2009;49:379-85.
- Hara M, Tamaki M, Aoyagi M, Ohno K. Possible role of cyclooxygenase-2 in developing chronic subdural hematoma. *J Med Dent Sci* 2009;56:101-6.
- Stanisic M, Lyngstadaas SP, Pripp AH, Aasen AO, Lindegaard KF, Ivanovic J, et al. Chemokines as markers of local inflammation and angiogenesis in patients with chronic subdural hematoma: A prospective study. *Acta Neurochir (Wien)* 2012;154:113-20.
- Tokmak M, Iplikcioglu AC, Bek S, Gökdoğan CA, Erdal M. The role of exudation in chronic subdural hematomas. *J Neurosurg* 2007;107:290-5.
- Basaldella L, Perin A, Orvieto E, Marton E, Itskovich D, Dei Tos AP, et al. A preliminary study of aquaporin 1 immunolocalization in chronic subdural hematoma membranes. *J Clin Neurosci* 2010;17:905-7.
- Kannuki SG, Shirakawa N, Toi H. Rapid recurrence of chronic subdural hematoma by CSF entrapment. *No Shinkei Geka* 2009;37:567-72.
- Wester K, Helland CA. How often do chronic extra-cerebral hematomas occur in patients with intracranial arachnoid cysts? *J Neurol Neurosurg Psychiatry* 2008;79:72-5.

42. Mishra SK, Prasad M, Ghosh I, Bhattacharya RN. Incidental aneurysmal rupture during burrhole drainage for chronic subdural hematoma. *Neurol India* 2011;59:308-9.
43. Sundström T, Helland CA, Aarhus M, Wester K. What is the pressure in chronic subdural hematomas? A prospective, population-based study. *J Neurotrauma* 2012;29:137-42.
44. Mascarenhas L. Illustration of the impact of antiplatelet drugs on the genesis and management of chronic subdural hematoma. *Neurochirurgie* 2012;58:47-51.
45. Ducruet AF, Grobelny BT, Zacharia BE, Hickman ZL, Derosa PL, Anderson K, *et al.* The surgical management of chronic subdural hematoma. *Neurosurg Rev* 2012;35:155-69.
46. McClelland S 3rd, Won EK, Lam CH. Utilization of recombinant activated factor VII for intracranial hematoma evacuation in coagulopathic nonhemophilic neurosurgical patients with normal international normalized ratios. *Neurocrit Care* 2007;7:136-9.
47. Seçkin H, Kazanci A, Yigitkanli K, Simsek S, Kars HZ. Chronic subdural hematoma in patients with idiopathic thrombocytopenic purpura: A case report and review of the literature. *Surg Neurol* 2006;66:411-4.
48. Hellbusch LC. Benign extracerebral fluid collections in infancy: Clinical presentation and long-term follow-up. *J Neurosurg* 2007;107(Suppl 2):119-25.
49. Marcikić M, Hreckovski B, Samardžić J, Martinović M, Rotim K. Spontaneous resolution of post-traumatic chronic subdural hematoma: Case report. *Acta Clin Croat* 2010;49:331-4.
50. Hirashima Y, Kurimoto M, Nagai S, Hori E, Origasa H, Endo S. Effect of platelet-activating factor receptor antagonist, etizolam, on resolution of chronic subdural hematoma: A prospective study to investigate use as conservative therapy. *Neurol Med Chir (Tokyo)* 2005;45:621-6.
51. Miyagami M, Kagawa Y. Effectiveness of Kampo medicine Gorei-San for chronic subdural hematoma. *No Shinkei Geka* 2009;37:765-70.
52. Battaglia F, Lubrano V, Ribeiro-Filho T, Pradel V, Roche PH. Incidence and clinical impact of seizures after surgery for chronic subdural haematoma. *Neurochirurgie* 2012;58:230-4.
53. Huang YH, Yang TM, Lin YJ, Tsai NW, Lin WC, Wang HC, *et al.* Risk factors and outcome of seizures after chronic subdural hematoma. *Neurocrit Care* 2011;14:253-9.
54. Grobelny BT, Ducruet AF, Zacharia BE, Hickman ZL, Andersen KN, Sussman E, *et al.* Preoperative antiepileptic drug administration and the incidence of postoperative seizures following burr hole-treated chronic subdural hematoma. *J Neurosurg* 2009;111:1257-62.
55. Zarkou S, Aguilar MI, Patel NP, Wellik KE, Wingerchuk DM, Demaerschalk BM. The role of corticosteroids in the management of chronic subdural hematomas: A critically appraised topic. *Neurologist* 2009;15:299-302.
56. Berghauer Pont LM, Dirven CM, Dippel DW, Verweij BH, Dammers R. The role of corticosteroids in the management of chronic subdural hematoma: A systematic review. *Eur J Neurol* 2012 May 29 (Epub ahead of print).
57. Berghauer Pont LM, Dammers R, Schouten JW, Lingsma HF, Dirven CM. Clinical factors associated with outcome in chronic subdural hematoma: A retrospective cohort study of patients on pre-operative corticosteroid therapy. *Neurosurgery* 2012;70:873-80.
58. Dran G, Berthier F, Fontaine D, Rasenrarijao D, Paquis P. Effectiveness of adjuvant corticosteroid therapy for chronic subdural hematoma: A retrospective study of 198 cases. *Neurochirurgie* 2007;53:477-82.
59. Delgado-López PD, Martín-Velasco V, Castilla-Díez JM, Rodríguez-Salazar A, Galacho-Harriero AM, Fernández-Arconada O. Dexamethasone treatment in chronic subdural haematoma. *Neurocirugía (Astur)* 2009;20:346-59.
60. Sun TF, Boet R, Poon WS. Non-surgical primary treatment of chronic subdural haematoma: Preliminary results of using dexamethasone. *Br J Neurosurg* 2005;19:327-33.
61. Janowski M, Kunert P. Intravenous fluid administration may improve post-operative course of patients with chronic subdural hematoma: A retrospective study. *PLoS One* 2012;7:e35634.
62. Santarius T, Kirkpatrick PJ, Koliaş AG, Hutchinson PJ. Working toward rational and evidence-based treatment of chronic subdural hematoma. *Clin Neurosurg* 2010;57:112-22.
63. Domenicucci M, Russo N, Giugni E, Pierallini A. Relationship between supratentorial arachnoid cyst and chronic subdural hematoma: Neuro-radiological evidence and surgical treatment. *J Neurosurg* 2009;110:1250-5.
64. Guzel A, Kaya S, Ozkan U, Ufuk Aluclu M, Ceviz A, Belen D. Surgical treatment of chronic subdural haematoma under monitored anaesthesia care. *Swiss Med Wkly* 2008;138:398-403.
65. Ishfaq A, Ahmed I, Bhatti SH. Effect of head positioning on outcome after burr hole craniostomy for chronic subdural haematoma. *J Coll Physicians Surg Pak* 2009;19:492-5.
66. Kurabe S, Ozawa T, Watanabe T, Aiba T. Efficacy and safety of postoperative early mobilization for chronic subdural hematoma in elderly patients. *Acta Neurochir (Wien)* 2010;152:1171-4.
67. Abouzari M, Rashidi A, Rezaei J, Esfandiari K, Asadollahi M, Aleali H, *et al.* The role of postoperative patient posture in the recurrence of traumatic chronic subdural hematoma after burr-hole surgery. *Neurosurgery* 2007;61:794-7.
68. Kenning TJ, Dalfino JC, German JW, Drazin D, Adamo MA. Analysis of the subdural evacuating port system for the treatment of subacute and chronic subdural hematomas. *J Neurosurg* 2010;113:1004-10.
69. Rughani AI, Lin C, Dumont TM, Penar PL, Horgan MA, Tranmer BI. A case-comparison study of the subdural evacuating port system in treating chronic subdural hematomas. *J Neurosurg* 2010;113:609-14.
70. Lollis SS, Wolak ML, Mamourian AC. Imaging characteristics of the subdural evacuating port system, a new bedside therapy for subacute/chronic subdural hematoma. *AJNR Am J Neuroradiol* 2006;27:74-5.
71. Krieg SM, Aldinger F, Stoffel M, Meyer B, Kreutzer J. Minimally invasive decompression of chronic subdural haematomas using hollow screws: Efficacy and safety in a consecutive series of 320 cases. *Acta Neurochir (Wien)* 2012;154:699-705.
72. Santarius T, Qureshi HU, Sivakumaran R, Kirkpatrick PJ, Kirolos RW, Hutchinson PJ. The role of external drains and peritoneal conduits in the treatment of recurrent chronic subdural hematoma. *World Neurosurg* 2010;73:747-50.
73. Kiyamaz N, Yilmaz N, Mumcu C. Controversies in chronic subdural hematoma: Continuous drainage versus one-time drainage. *Med Sci Monit* 2007;13:CR240-3.
74. Komotar RJ, Starke RM, Connolly ES. The role of drain placement following chronic subdural hematoma evacuation. *Neurosurgery* 2010;66:N15-6.
75. Santarius T, Kirkpatrick PJ, Ganesan D, Chia HL, Jalloh I, Smielewski P, *et al.* Use of drains versus no drains after burr-hole evacuation of chronic subdural haematoma: A randomised controlled trial. *Lancet* 2009;374:1067-73.
76. Carlsen JG, Cortnum S, Sørensen JC. Recurrence of chronic subdural haematomata with and without post-operative drainage. *Br J Neurosurg* 2011;25:388-90.
77. Weigel R, Schmiedek P, Krauss JK. Outcome of contemporary surgery for chronic subdural haematoma: Evidence based review. *J Neurol Neurosurg Psychiatry* 2003;74:937-43.
78. Ramachandran R, Hegde T. Chronic subdural hematomas: Causes of morbidity and mortality. *Surg Neurol* 2007;67:367-72.
79. Wakai S, Hashimoto K, Watanabe N, Inoh S, Ochiai C, Nagai M. Efficacy of closed-system drainage in treating chronic subdural hematoma: A prospective comparative study. *Neurosurgery* 1990;26:771-3.
80. Tsutsumi K, Maeda K, Iijima A, Usui M, Okada Y, Kirino T. The relationship of preoperative magnetic resonance imaging findings and closed system drainage in the recurrence of chronic subdural hematoma. *J Neurosurg* 1997;87:870-5.
81. Gurelik M, Aslan A, Gurelik B, Ozum U, Karadag O, Kars HZ. A safe and effective method for treatment of chronic subdural haematoma. *Can J Neurol Sci* 2007;34:84-7.
82. Sarnivud P, Chiewchanvechakul W, Chumnanvej S. Chronic subdural hematoma: Drainage vs. no drainage. *J Med Assoc Thai* 2011;94:1352-6.
83. Javadi A, Amirjamshidi A, Aran S, Hosseini SH. A randomized controlled trial comparing the outcome of burr-hole irrigation with and without drainage in the treatment of chronic subdural hematoma: A preliminary report. *World Neurosurg* 2011;75:731-6.

84. Ahmed S, Agrawal D, Kale SS, Mahapatra AK. A comparative study of treatment of chronic subdural hematoma: Burr hole drainage versus continuous closed drainage. *The Indian Journal of Neurotrauma* 2011;8:17-24.
85. Nayil K, Ramzan A, Sajad A, Zahoor S, Wani A, Nizami F, *et al.* Subdural hematomas: An analysis of 1181 Kashmiri patients. *World Neurosurg* 2012;77:103-10.
86. Reinges MH, Hasselberg I, Rohde V, Küker W, Gilsbach JM. Prospective analysis of bedside percutaneous subdural tapping for the treatment of chronic subdural haematoma in adults. *J Neurol Neurosurg Psychiatry* 2000;69:40-7.
87. Rohde V, Graf G, Hassler W. Complications of burr-hole craniostomy and closed-system drainage for chronic subdural hematomas: A retrospective analysis of 376 patients. *Neurosurg Rev* 2002;25:89-94.
88. Mori K, Maeda M. Surgical treatment of chronic subdural hematoma in 500 consecutive cases: Clinical characteristics, surgical outcome, complications, and recurrence rate. *Neurol Med Chir (Tokyo)* 2001;41:371-81.
89. Gazzeri R, Galarza M, Neroni M, Canova A, Refice GM, Esposito S. Continuous sub galeal suction drainage for the treatment of chronic subdural haematoma. *Acta Neurochir (Wien)* 2007;149:487-93.
90. Bellut D, Woernle CM, Burkhardt JK, Kockro RA, Bertalanffy H, Kraysenbühl N. Subdural drain age versus subperiosteal drainage in burr-hole trepanation for symptomatic chronic subdural hematomas. *World Neurosurg* 2012;77:111-8.
91. Zumofen D, Regli L, Levivier M, Kraysenbühl N. Chronic subdural hematomas treated by burr hole trepanation and a subperiosteal drainage system. *Neurosurgery* 2009;64:1116-21.
92. Sindou M, Ibrahim I, Maarrawi J. Chronic sub-dural hematomas: Twist drill craniostomy with a closed system of drainage, for 48 hours only, is a valuable surgical treatment. *Acta Neurochir (Wien)* 2010;152:545-6.
93. Ibrahim I, Maarrawi J, Jouanneau E, Guenot M, Mertens P, Sindou M. Evacuation of chronic subdural hematomas with the Twist-Drill technique: Results of a randomized prospective study comparing 48-h and 96-h drainage duration. *Neurochirurgie* 2010;56:23-7.
94. Yu GJ, Han CZ, Zhang M, Zhuang HT, Jiang YG. Prolonged drainage reduces the recurrence of chronic subdural hematoma. *Br J Neurosurg* 2009;23:606-11.
95. Ishibashi A, Yokokura Y, Adachi H. A comparative study of treatments for chronic subdural hematoma: Burr hole drainage versus burr hole drainage with irrigation. *Kurume Med J* 2011;58:35-9.
96. Tahsim-Oglou Y, Beseoglu K, Hänggi D, Stummer W, Steiger HJ. Factors predicting recurrence of chronic subdural haematoma: The influence of intraoperative irrigation and low-molecular-weight heparin thromboprophylaxis. *Acta Neurochir (Wien)* 2012;154:1063-8.
97. Zakaraia AM, Adnan JS, Haspani MS, Naing NN, Abdullah JM. Outcome of 2 different types of operative techniques practiced for chronic subdural hematoma in Malaysia: An analysis. *Surg Neurol* 2008;69:608-15.
98. Horn EM, Feiz-Erfan I, Bristol RE, Spetzler RF, Harrington TR. Bedside twist drill craniostomy for chronic subdural hematoma: A comparative study. *Surg Neurol* 2006;65:150-3.
99. Escosa Baé M, Wessling H, Salca HC, de Las Heras Echeverría P. Use of twist-drill craniostomy with drain in evacuation of chronic subdural hematomas: Independent predictors of recurrence. *Acta Neurochir (Wien)* 2011;153:1097-103.
100. Gökmen M, Sucu HK, Ergin A, Gökmen A, Bezircio Lu H. Randomized comparative study of burr-hole craniostomy versus twist drill craniostomy; surgical management of unilateral hemispheric chronic subdural hematomas. *Zentralbl Neurochir* 2008;69:129-33.
101. Mondorf Y, Abu-Owaimer M, Gaab MR, Oertel JM. Chronic subdural hematoma: Craniotomy versus burr hole trepanation. *Br J Neurosurg* 2009;23:612-6.
102. Sucu HK, Gökmen M, Ergin A, Bezircioğlu H, Gökmen A. Is there a way to avoid surgical complications of twist drill craniostomy for evacuation of a chronic subdural hematoma? *Acta Neurochir (Wien)* 2007;149:597-9.
103. Hwang SC, Im SB, Kim BT, Shin WH. Safe entry point for twist-drill craniostomy of a chronic subdural hematoma. *J Neurosurg* 2009;110:1265-70.
104. Lega BC, Danish SF, Malhotra NR, Sonnad SS, Stein SC. Choosing the best operation for chronic subdural hematoma: A decision analysis. *J Neurosurg* 2010;113:615-21.
105. Liu Y, Xia JZ, Wu AH, Wang YJ. Burr-hole craniotomy treating chronic subdural hematoma: A report of 398 cases. *Chin J Traumatol* 2010;13:265-9.
106. Sikahall-Meneses E, Salazar-Pérez N, Sandoval-Bonilla B. Chronic subdural hematoma. Surgical management in 100 patients. *Cir Cir* 2008;76:199-203.
107. Krupa M. Comparison of two surgical methods as to early results in chronic subdural hematoma. *Ann Acad Med Stetin* 2009;55:39-47.
108. Soto-Granados M. Treatment of chronic subdural hematoma through a burr hole. *Cir Cir* 2010;78:203-7.
109. Han HJ, Park CW, Kim EY, Yoo CJ, Kim YB, Kim WK. One vs. Two Burr Hole Craniostomy in Surgical Treatment of Chronic Subdural Hematoma. *J Korean Neurosurg Soc* 2009;46:87-92.
110. Khadka NK, Sharma GR, Roka YB, Kumar P, Bista P, Adhikari D, *et al.* Single burr hole drainage for chronic subdural haematoma. *Nepal Med Coll J* 2008;10:254-7.
111. Kansal R, Nadkarni T, Goel A. Single versus double burr hole drainage of chronic subdural hematomas. A study of 267 cases. *J Clin Neurosci* 2010;17:428-9.
112. Taussky P, Fandino J, Landolt H. Number of burr holes as independent predictor of postoperative recurrence in chronic subdural haematoma. *Br J Neurosurg* 2008;22:279-82.
113. Mirsadeghi SM, Habibi Z, Meybodi KT, Nejat F, Tabatabai SA. Malignant subdural effusion associated with disseminated adenocarcinoma: A case report. *Cases J* 2008;1:328.
114. White M, Mathieson CS, Campbell E, Lindsay KW, Murray L. Treatment of chronic subdural haematomas: A retrospective comparison of minicraniectomy versus burr hole drainage. *Br J Neurosurg* 2010;24:257-60.
115. Isobe N, Sato H, Murakami T, Kurokawa Y, Seyama G, Oki S. Six cases of organized chronic subdural hematoma. *No Shinkei Geka* 2008;36:1115-20.
116. Rocchi G, Caroli E, Salvati M, Delfini R. Membranectomy in organized chronic subdural hematomas: Indications and technical notes. *Surg Neurol* 2007;67:374-80.
117. Juan WS, Tai SH, Hung YC, Lee EJ. Multiple tenting techniques improve dead space obliteration in the surgical treatment for patients with giant calcified chronic subdural hematoma. *Acta Neurochir (Wien)* 2012;154:707-10.
118. Kaplan M, Akgün B, Seçer HI. Ossified chronic subdural hematoma with armored brain. *Turk Neurosurg* 2008;18:420-4.
119. Oda S, Shimoda M, Hoshikawa K, Shiramizu H, Matsumae M. Organized chronic subdural haematoma with a thick calcified inner membrane successfully treated by surgery: A case report. *Tokai J Exp Clin Med* 2010;35:85-8.
120. Lee JK, Choi JH, Kim CH, Lee HK, Moon JG. Chronic subdural hematomas: A comparative study of three types of operative procedures. *J Korean Neurosurg Soc* 2009;46:210-4.
121. Kim JH, Kang DS, Kim JH, Kong MH, Song KY. Chronic subdural hematoma treated by small or large craniotomy with membranectomy as the initial treatment. *J Korean Neurosurg Soc* 2011;50:103-8.
122. Mobbs R, Khong P. Endoscopic-assisted evacuation of subdural collections. *J Clin Neurosci* 2009;16:701-4.
123. Takahashi S, Yazaki T, Nitori N, Kano T, Yoshida K, Kawase T. Neuroendoscope-assisted removal of an organized chronic subdural hematoma in a patient on bevacizumab therapy: Case report. *Neurol Med Chir (Tokyo)* 2011;51:515-8.
124. Miranda LB, Braxton E, Hobbs J, Quigley MR. Chronic subdural hematoma in the elderly: Not a benign disease. *J Neurosurg* 2011;114:72-6.
125. Amirjamshidi A, Abouzari M, Rashidi A. Glasgow Coma Scale on admission is correlated with postoperative Glasgow Outcome Scale in chronic subdural hematoma. *J Clin Neurosci* 2007;14:1240-1.
126. Krupa M, Stachura K, Moskala M. A comparison of the results of treatment in young and elderly patients with chronic subdural hematoma depending on the method of surgery. *Ann Acad Med Stetin* 2009;55:39-45.

127. Dinc C, Iplikcioglu AC, Bikmaz K, Navruz Y. Intracerebral haemorrhage occurring at remote site following evacuation of chronic subdural haematoma. *Acta Neurochir (Wien)* 2008;150:497-9.
128. Shaikh N, Masood I, Hanssens Y, Louon A, Hafiz A. Tension pneumocephalus as complication of burr-hole drainage of chronic subdural hematoma: A case report. *Surg Neurol Int* 2010;1:p.ii,27.
129. Cummins A. Tension pneumocephalus is a complication of chronic subdural hematoma evacuation. *J Hosp Med* 2009;4:E3-4.
130. Nagata K, Asano T, Basugi N, Tango T, Takakura K. Studies on the operative factors affecting the reduction of chronic subdural hematoma, with special reference to the residual air in the hematoma cavity. *No Shinkei Geka* 1989;17:15-20.
131. Aung TH, Wong WK, Mo HP, Tsang CS. Management of chronic subdural haematoma: Burr hole drainage, replacement with Hartmann's solution, and closed-system drainage. *Hong Kong Med J* 1999;5:383-6.
132. Acakpo-Satchivi L, Luerssen TG. Brain herniation through an internal subdural membrane: A rare complication seen with chronic subdural hematomas in children. Case report. *J Neurosurg* 2007;107(Suppl 6):485-8.
133. Bakar B, Sungur C, Tekkok IH. Bilateral chronic subdural hematoma contaminated with *Klebsiella pneumoniae*: An unusual case. *J Korean Neurosurg Soc* 2009;45:397-400.
134. Park KJ, Kang SH, Lee HK, Chung YG. Brain stem hemorrhage following burr hole drainage for chronic subdural hematoma-case report. *Neurol Med Chir (Tokyo)* 2009;49:594-7.
135. Akhaddar A, Ajja A, Elmostarchid B, Boucetta M. Combined epidural and intracerebral hematomas after evacuation of bilateral chronic subdural hematoma. *Neurochirurgie* 2008;54:728-30.
136. Moon KS, Lee JK, Kim TS, Jung S, Kim JH, Kim SH, *et al.* Contralateral acute subdural hematoma occurring after removal of calcified chronic subdural hematoma. *J Clin Neurosci* 2007;14:283-6.
137. Kobayashi S, Mutoh T, Ishikawa T, Moroi J, Tamagawa N, Yoshioka S, *et al.* Remote cerebellar hemorrhage after single burr hole drainage of chronic subdural hematoma of the elderly. *No Shinkei Geka* 2011;39:755-61.
138. hon KH, Lee JM, Koh EJ, Choi HY. Independent predictors for recurrence of chronic subdural hematoma. *Acta Neurochir (Wien)* 2012;154:1541-8.
139. Oh HJ, Lee KS, Shim JJ, Yoon SM, Yun IG, Bae HG. Postoperative course and recurrence of chronic subdural hematoma. *J Korean Neurosurg Soc* 2010;48:518-23.
140. Nagatani K, Takeuchi S, Sakakibara F, Otani N, Nawashiro H. Radiological factors related to recurrence of chronic subdural hematoma. *Acta Neurochir (Wien)* 2011;153:1713.
141. Kristof RA, Grimm JM, Stoffel-Wagner B. Cerebrospinal fluid leakage into the subdural space: Possible influence on the pathogenesis and recurrence frequency of chronic subdural hematoma and subdural hygroma. *J Neurosurg* 2008;108:275-80.
142. Amirjamshidi A, Abouzari M, Eftekhar B, Rashidi A, Rezaii J, Esfandiari K, *et al.* Outcomes and recurrence rates in chronic subdural haematoma. *Br J Neurosurg* 2007;21:272-5.
143. Sakakibara F, Tsuzuki N, Uozumi Y, Nawashiro H, Shima K. Chronic subdural hematoma—recurrence and prevention. *Brain Nerve* 2011;63:69-74.
144. Funai M, Osuka K, Usuda N, Atsuzawa K, Inukai T, Yasuda M, *et al.* Activation of PI3 kinase/Akt signaling in chronic subdural hematoma outer membranes. *J Neurotrauma* 2011;28:1127-31.
145. Kubota M, Narita K, Nakagomi T, Tamura A, Hisaki H, Shimasaki H, *et al.* Fatty acid composition of the chronic subdural hematoma: With reference to its recurrence. *J Clin Neurosci* 1998;5:63-5.
146. Torihashi K, Sadamasa N, Yoshida K, Narumi O, Chin M, Yamagata S. Independent predictors for recurrence of chronic subdural hematoma: A review of 343 consecutive surgical cases. *Neurosurgery* 2008;63:1125-9.
147. Kung WM, Hung KS, Chiu WT, Tsai SH, Lin JW, Wang YC, *et al.* Quantitative assessment of impaired postevacuation brain re-expansion in bilateral chronic subdural haematoma: Possible mechanism of the higher recurrence rate. *Injury* 2012;43:598-602.
148. Dost L, Denes E, Hidri N, Ploy MC, Barraud O, Moreau JJ, *et al.* Chronic subdural hematoma infected by *Campylobacter fetus*: Case report. *Neurochirurgie* 2012;58:52-4.
149. Takeda N, Sasaki K, Oikawa A, Aoki N, Hori T. A new simple therapeutic method for chronic subdural hematoma without irrigation and drainage. *Acta Neurochir (Wien)* 2006;148:541-6.
150. Ishihara H, Ishihara S, Kohyama S, Yamane F, Ogawa M, Sato A, *et al.* Experience in endovascular treatment of recurrent chronic subdural hematoma. *Interv Neuroradiol* 2007;13(Suppl 1):141-4.
151. Mino M, Nishimura S, Hori E, Kohama M, Yonezawa S, Midorikawa H, *et al.* Efficacy of middle meningeal artery embolization in the treatment of refractory chronic subdural hematoma. *Surg Neurol Int* 2010;1:78.
152. Weigel R, Hohenstein A, Schlickum L, Weiss C, Schilling L. Angiotensin converting enzyme inhibition for arterial hypertension reduces the risk of recurrence in patients with chronic subdural hematoma possibly by an antiangiogenic mechanism. *Neurosurgery* 2007;61:788-92.
153. Shimamura N, Ogasawara Y, Naraoka M, Ohnkuma H. Irrigation with thrombin solution reduces recurrence of chronic subdural hematoma in high-risk patients: Preliminary report. *J Neurotrauma* 2009;26:1929-33.
154. Neils DM, Singanallur PS, Wang H, Tracy P, Klopfenstein J, Dinh D, *et al.* Recurrence-free chronic subdural hematomas: A retrospective analysis of the instillation of tissue plasminogen activator in addition to twist drill or burr hole drainage in the treatment of chronic subdural hematomas. *World Neurosurg* 2012;78:145-9.

How to cite this article: Yadav YR, Parihar V, Namdev H, Bajaj J. Chronic subdural hematoma. *Asian J Neurosurg* 2016;11:330-42.

Source of Support: Nil, **Conflict of Interest:** None declared.