

CASE REPORT

Intradural teratoma in a neonate with meningomyelocele

Anand Pandey, Saroj Chooramani Gopal, Vijayendra Kumar, Ajay Narayan Gangopadhyay, Shiv Prasad Sharma

Department of Pediatric Surgery, Institute of Medical Sciences, Banaras Hindu University, Varanasi, Uttar Pradesh, India

ABSTRACT

Meningomyelocele is a common congenital problem. The teratoma is a neoplasm composed of tissues foreign to the part in which they arise. An intradural teratoma within a meningomyelocele is a very rare association. We report a case of intradural teratoma with a brief review of the relevant literature.

Key words: Intradural, meningomyelocele, teratoma

Introduction

Teratoma as defined by Willis,^[1] is a true tumor or neoplasm composed of multiple tissues of a kind, foreign to the part from which it arises. They have the potential to develop malignancy and it can arise in any part of the body. In the spinal cord, teratoma account for about 0.2-0.5% of the spinal tumors.^[2] In the present case, the teratoma was present within the meningomyelocele (MMC), a very rare association. Hence, it is being reported with a brief review of the literature.

Case Report

A 7-days-old male baby was admitted to our department with lumbosacral MMC of 4 × 4 cm in size from which CSF was leaked. On examination, the neural tissue was visible inside the thin membranes. The leak occurred spontaneously on the sixth day during nursing and the patient was brought to the department within 8 hours. The neurological examination of patient showed anal incontinence and decreased movements of the left lower limb. The spine X-ray showed bony defect from vertebra L3 to S1. As CSF was leaked from the MMC, it

was planned for immediate operation without waiting for MRI.

The patient was operated upon for MMC, with the help of magnifying lens because operating microscope was not available. A transverse elliptical incision was made around the lesion and after removing the subcutaneous tissue, the pedicle was dissected carefully. On opening the sac, a globular mass, adhered to the neural tissue was noticed inside it [Figure 1]. It was removed carefully and sent for histopathology. The dura was closed carefully. The vertebral defect was covered primarily by muscle sheath.

The postoperative period was uneventful. The patient was discharged on tenth postoperative day after stitch removal. The follow-up of the patient is satisfactory except for slight weakness of the left lower limb. The power of lower limbs was 5/5 on right side and 4/5 on left side. The histopathology of the removed mass revealed it to be a teratoma [Figures 2 and 3].

Discussion

The coincidence of a MMC and a neoplasm is rare, and only limited reports on the concurrence of a teratoma within a MMC have been published.^[3-5] The others terms used are teratomatous cyst and teratoid tumor.^[5] Radiologically, mixed solid and cystic morphology, fat signal and areas of calcification in as patient of MMC can suggest the presence of teratoma.^[5] The intraoperative detection of a cystic portion of a MMC without direct connection to the spinal canal can be a possible sign of coexisting teratoma.^[3]

The teratoma can occur anywhere in the spinal cord, the commonest site being lumbar, conus and thoraco-lumbar regions.^[5-7] It has been suggested that the occurrence of teratoma and the MMC is not a coincidence.^[8] The various theories postulated are neoplastic transformation of misplaced primordial germ cells from the yolk sac, an ectodermal-to-

Access this article online

Quick Response Code:



Website:

www.asianjns.org

DOI:

10.4103/1793-5482.145111

Address for correspondence:

Prof. Saroj Chooramani Gopal, Department of Pediatric Surgery, Institute of Medical Sciences, Banaras Hindu University, Varanasi - 221 005, Uttar Pradesh, India.
E-mail: dranand27@rediffmail.com

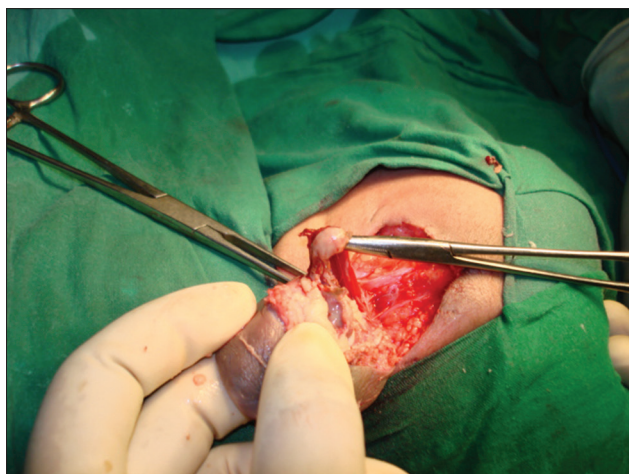

Figure 1: Teratoma being dissected from MMC

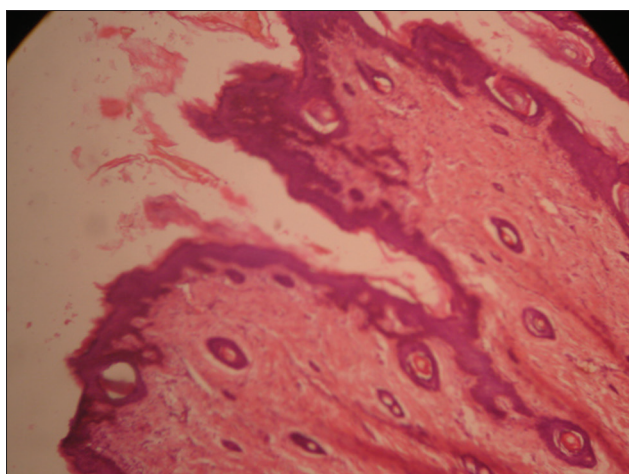


Figure 2: Epithelial structures seen in microphotograph (H and E, x400)

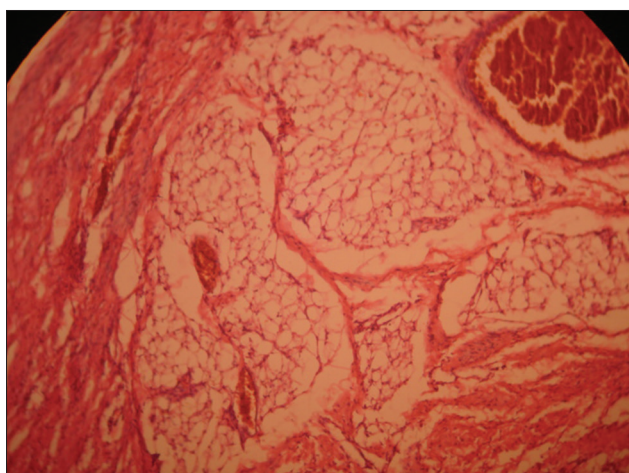


Figure 3: Fat and muscle cells in microphotograph (H and E, x400)

endodermal adhesion forms during gastrulation and the notochord splits around that adhesion or persistence of the neurenteric canal, which would leave a connection of

pluripotent cells between the ectoderm and the endoderm.^[8] The role of primitive streak in the occurrence of the teratoma has also been suggested. In our case, as the teratoma occurred with a MMC, we like others^[8,9] believe it to be due to dysembryogenic mechanism and not neoplastic as postulated by Gregorios *et al.*^[10]

The teratoma contains differentiated elements derived from all three germinal layers. The ectoderm is frequently represented by skin and skin adnexa and neural tissue. The mesoderm derived tissues such as cartilage, bones, fat, fibrous, tissue and smooth muscle cells. The endodermal elements consist of respiratory and gastrointestinal epithelium.^[11] Tibbs *et al.*^[12] have stated that the term teratoma should be reserved for tissues representing all the three germ cell layers. In our patient, the teratoma was intradural and consisted of skin and skin appendages, muscle and fat cells along with endothelial lining of unknown origin.

There is a report of malignancy developing in the teratoma within a lipomeningocele.^[13] The presence of carcinoid has also been noticed.^[14] There might be a possibility of nerve roots tethering to the teratoma, hence, operation must be cautious. The patients must be called for regular follow-up. As such teratoma inside an MMC is a benign neoplasm, without any recurrence after standard surgery for an MMC.^[3]

To conclude, teratoma inside an MMC is a rare neoplasm that, on identification, must be removed carefully. The histopathology is necessary to make the accurate diagnosis. The prognosis is good.

References

1. Willis RA. Pathology of tumors. London: Butterworth; 1948.
2. Nonomura Y, Miyamoto K, Wada E, Hosoe H, Nishimoto H, Ogura H, Shimizu K. Intramedullary teratoma of the spine: report of two adult cases. *Spinal Cord* 2002;40:40-3.
3. Habibi J, Nejat F, Naeini PE, Mahjoub F. Teratoma inside a myelomeningocele. *J Neurosurg* 2007;106(6 Suppl):467-71.
4. Al-Sarraj ST, Parmar D, Dean AF, Phookun G, Bridges LR. Clinico-pathological study of seven cases of spinal cord teratoma: Spinal teratoma possible germ cell origin. *Histopathology* 1998;32:51-6.
5. Sharma MC, Jain D, Sarkar C, Suri V, Garg A, Singh M, *et al.* Spinal teratomas: A clinico-pathological study of 27 patients. *Acta Neurochir (Wien)* 2009;151:245-52.
6. Poeze M, Herpers MJ, Tjandra B, Freling G, Beuls EA. Intramedullary spinal teratoma presenting with urinary retention: Case report and review of the literature. *Neurosurgery* 1999;45:379-85.
7. Turgut M. Spinal intramedullary teratoma with exophytic components. *Neurosurg Rev* 2004;27:137-8.
8. Steinbok J. Thoracolumbar teratoma associated with meningocele: Common etiology or coincidence? *Child's Nerv Syst* 2002;18:302-3.
9. Koen JL, McLendon RE, George TM. Intradural spinal teratoma: Evidence for a dysembryogenic origin. Report of four cases. *J Neurosurg* 1998;89:844-51.
10. Gregorios JB, Green B, Page L, Thomsen S, Monforte H. Spinal cord tumors presenting with neural tube defects. *Neurosurgery* 1986;19:962-66.

11. Ozer H, Yuccer N. Myelomeningocele, Dermal sinus tract, Split cord malformation associated with extradural teratoma in a 30-month old girl. *Acta Neurochir* 1999;141:1123-24.
12. Tibbs PA, James HE, Rorke LB, Schut L, Bruce DA. Midline hamartomas masquerading as meningomyelocele or teratoma in the new born infant. *J Pediatr* 1976;89:928-33.
13. Mickle JP, McLenan JE. Malignant teratoma arising within a lipomeningocele. Case report. *J Neurosurg* 1975;43:761-76.
14. Fan X, Turner JE, Turner TM, Elrod JP, Clough JA, Howell EI, *et al.*

Carcinoid tumour development in an intramedullary spinal cord mature teratoma. *AJNR Am J Neuroradiol* 2001;22:1778-81.

How to cite this article: Pandey A, Gopal SC, Kumar V, Gangopadhyay AN, Sharma SP. Intradural teratoma in a neonate with meningomyelocele. *Asian J Neurosurg* 2016;11:323-4.

Source of Support: Nil, **Conflict of Interest:** None declared.

