

# A 10-year follow-up of transpedicular screw fixation and intervertebral autogenous posterior iliac crest bone graft or intervertebral B-Twin system in failed back surgery syndrome

Rafael Cincu, Francisco de Asis Lorente<sup>1</sup>, Joaquin Gomez<sup>1</sup>, Jose Eiras<sup>1</sup>, Amit Agrawal<sup>2</sup>

Departments of Neurosurgery, General University Hospital, Valencia, <sup>1</sup>Miguel Servet University Hospital, Zaragoza, Spain, <sup>2</sup>Neurosurgery, Narayana Medical College and Hospital, Chintareddy Palem, Nellore, India

## ABSTRACT

**Background:** The spine surgeons have been combining anterior and posterolateral fusion (circumferential fusion) as the final solution to treat spinal disorders and many have been using it to treat failed back surgery syndrome (FBSS). In present study, we analyzed and compared the clinical and radiological outcomes in patients with transpedicular screw fixation and intervertebral autogenous posterior iliac crest bone graft or in patients with transpedicular screw fixation and intervertebral B-Twin system for FBSS with a follow-up period of 10 years after the surgery.

**Materials and Methods:** This study was a retrospective case study performed on 55 patients with FBSS. Clinical and radiological changes were compared between the two groups of patients on the basis of improvement of back pain, radicular pain, and work capacity. Outcome was measured in terms of Oswestry Low Back Pain Disability Index, and the changes in pain and function were documented every year from before surgery until 2012. We analyzed the evolution of 55 cases of FBSS those underwent segmental circumferential posterior fusions from June 2001 to February 2003, operated by a single surgeon and followed up during 10 years until February 2012. The patients were divided into 2 groups: In 25 patients, posterolateral fusions with Legacy™ (Medtronic, Inc. NYSE: MDT) screws and intersomatic autogenous posterior iliac crest bone graft was performed, and, in 30 patients, posterolateral fusions with the same screws and intersomatic fusion B-Twin (Biomet Spain Orthopaedics, S.L.) system was performed. In all cases, we used posterior lumbar interbody fusion (PLIF)/transforaminal lumbar interbody fusion (TLIF) approach for intervertebral graft, and the arthrodesis was supplemented at intertransverse level with Autologous Growth Factor (AGF-MBA INCORPORADO, S.A.). The outcome was measured in terms of Oswestry Low Back Pain Disability Index, and the changes in pain and function were documented every year and compared from before surgery to the final follow-up visit. Preoperative and postoperative scores were available for all patients.

**Results:** The average age of these patients was comparable in both groups (mean age 42.6 versus 50.2 years). The average follow-up period was 200.6 months in the first group (screws and intersomatic bone) and 184.4 months in the second group (screws and B-Twin). In the autologous bone graft group, the CT scan and Rx study revealed loss of height of intervertebral space between 25% and 45% of 24 h postoperative height of intervertebral operated disc, and the patients

continued to lose the height until 20 months after the surgery. In the B Twin group, the CT scan and Rx study revealed a loss of height of the intervertebral level of 8-12% over a period of 9 months follow-up, followed by stability. A total of 31 patients (55%) had improved Oswestry Low Back Pain Disability Index >40% of the total possible points, although this did not reflect in PSI or return to work rate.

**Conclusions:** The patients with rigid fixation do well in terms of correction of lumbar lordosis, but they do not do well in terms of recurrence of pain. Furthermore, they need some kind of intervention to control pain after the first year after surgery. In patients in whom bone graft is used, although they do not maintain and

Videos available at [www.asianjns.org](http://www.asianjns.org)

### Access this article online

Quick Response Code:



Website:

[www.asianjns.org](http://www.asianjns.org)

DOI:

10.4103/1793-5482.145120

### Address for correspondence:

Dr. Rafael Cincu, Department of Neurosurgery, General University Hospital, Valencia, 14 48000, Spain. E-mail: [rafael.cincu@gmail.com](mailto:rafael.cincu@gmail.com)

sustain the lumbar lordosis in the long term, they have less recurrence of pain with less chances of intervention for pain control.

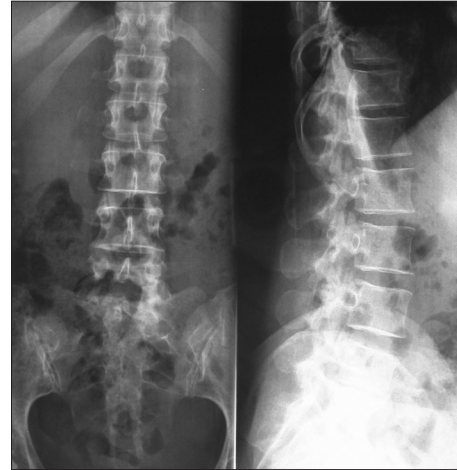**Key words:** Chronic low back pain, degenerative disc disease, failed back surgery syndrome, functional outcome, lumbar spinal fusion, spondylosis

## Introduction

Low back pain causes prolonged disability, anxiety, and discomfort and it is endemic in many western countries. It has been estimated that lifetime incidence of low back pain in United States is 60-80%.<sup>[1,2]</sup> The patients with low back pain account for approximately 85-90% of direct and indirect costs related to managing low back pain.<sup>[3-5]</sup> Failed back surgery syndrome (FBSS) is not actually a syndrome and is often used to describe the condition of patients who have not had a successful result with back surgery or spine surgery and have experienced continued pain after surgery. Many factors can contribute to FBSS including residual or recurrent disc herniation, persistent post-operative pressure on a spinal nerve root, scar tissue (fibrosis) tethering on a spinal nerve root, facet joint hyper mobility with instability, muscular deconditioning, depression, anxiety, and sleeplessness. Mechanical or chemical changes in degenerative intervertebral discs have been proposed to be the cause of low back pain without sciatica or neurological deficits and are referred as “discogenic” low back pain, a distinct entity than herniated disc causing sciatica.<sup>[6,7]</sup> Many spine surgeons have been combining anterior with posterolateral fusion (circumferential fusion) to treat other spinal disorders and have been using it like “final solution” to treat FBSS. The purpose of the current study was to evaluate and compare the clinical and radiological outcomes in patients with transpedicular screw fixation and intervertebral autogenous posterior iliac crest bone graft or with transpedicular screw fixation and intervertebral B-Twin system in FBSS and follow the patients for more than 10 years.

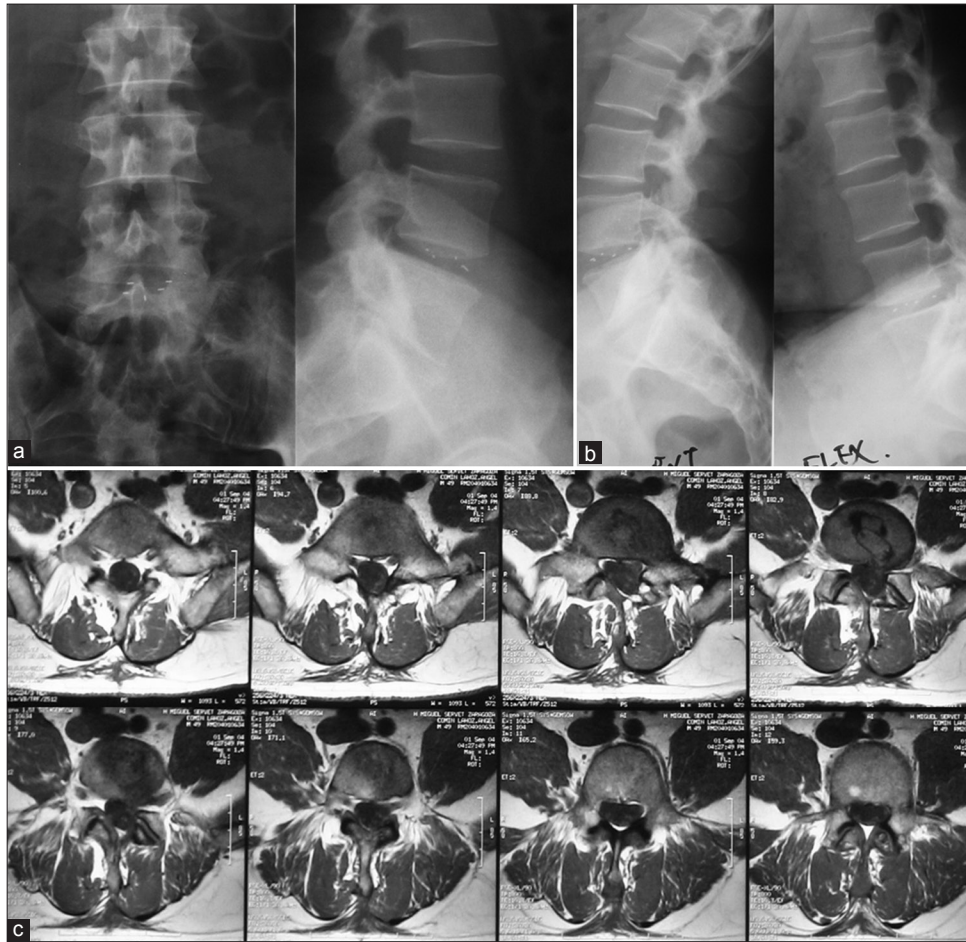
## Materials and Methods

In this retrospective study, we analyzed our experience with 55 FBSS patients [Figures 1-3] who underwent segmental circumferential posterior fusions between June 2001 and February 2003 and operated by a single surgeon and followed up for > 10 years. All the patients had severe low back pain with or without radicular or pseudoradicular pain. Lumbar spine instability was evaluated on standing lateral flexion-extension radiographs and fusion was considered demonstrable instability on imaging for degenerated disc disease and intractable low back pain. The instability could also be demonstrated in the surgical field [Video 1]. Provocative discography was performed to ensure the level responsible for pain and discard adjacent level, if deemed necessary. The patients were divided into

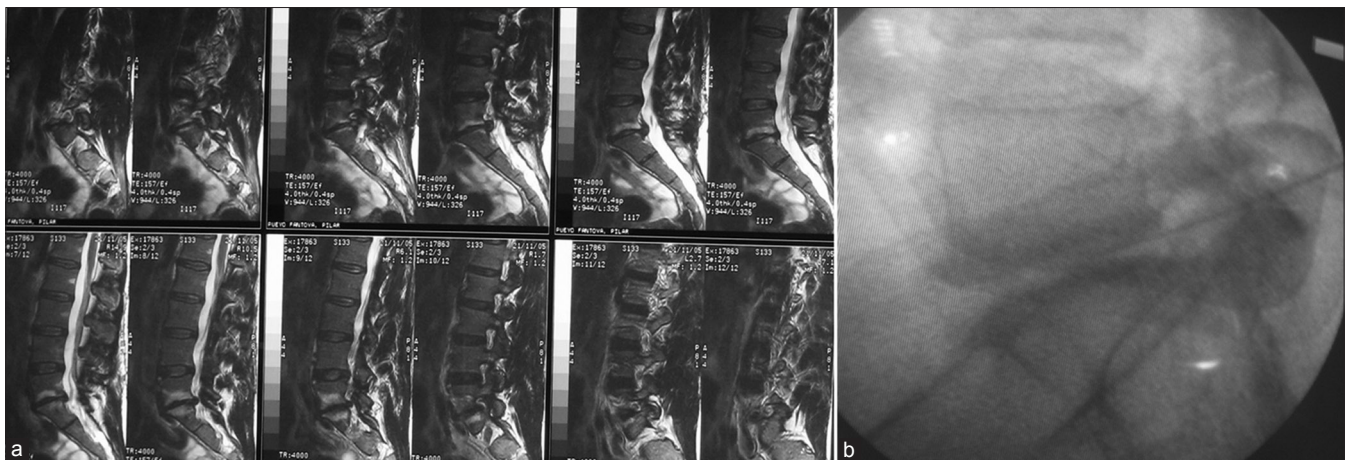

**Figure 1:** The extent of L5-S1 hemilaminectomy (both left and right) and how the resection was performed on the right side articular facet for a foraminal herniated nucleus pulposus (HNP)

2 groups. Total 25 patients had posterolateral fusions with Legacy™ (Medtronic, Inc. NYSE: MDT) screws and intersomatic autogenous posterior iliac crest bone graft, and 30 patients had posterolateral fusions with the same screws and intersomatic B-Twin (Biomet Spain Orthopaedics, S.L.) system. In all cases, we used posterior lumbar interbody fusion (PLIF)/transforaminal lumbar interbody fusion (TLIF) approach for intervertebral graft, and the arthrodesis was supplemented at intertransverse level with Autologous Growth Factor (AGF-MBA INCORPORADO, S.A.). Partial lateral facetectomies were performed in all cases to put screws. During surgery, the most difficult problem encountered was extensive fibrosis at the operative site. To overcome this, the dissection was always started at the normal level and the normal dura was identified. To begin with, the screws were inserted and, later on, nerve root decompression was performed and the dura was tried to identify from midline to lateral. Extensive fibrosis was released as and when necessary with safety and to avoid injury to the dura and neural structures. The foraminotomy was performed only at the level corresponding to that of the clinical level of the radiculopathy. Radiological and clinical improvements were compared between the 2 groups on the basis of improvement of back pain and work capacity.<sup>[8]</sup> The outcome was measured in terms of Oswestry Low Back Pain Disability Index<sup>[9]</sup> and the changes in pain and function were compared from before surgery to that in the final follow-up visit. Preoperative and postoperative scores were available for all patients.



**Figure 2:** (a) L4-L5 hemilaminectomy with a PDN intersomatic system; (b) Segmental instability at L4-L5 level in a dynamic lumbar study; (c) MR study showing the left side foraminal compromise at L4-L5 level



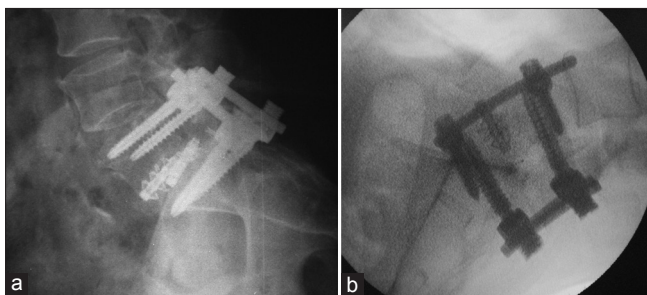
**Figure 3:** (a) L5-S1 segmental instability developing after 1 year partial L5-S1 laminectomy for L5-S1 central HNP; (b) Provocative discography performed as the patient was having pseudoradicular pain in legs

**Results**

The average age of these patients was comparable in both the groups (mean age: 42.6 versus 50.2 years). There were 7 (27%) patients with simple hemilaminectomy or laminectomy and discectomy in the previous surgery and 18 (73%) with

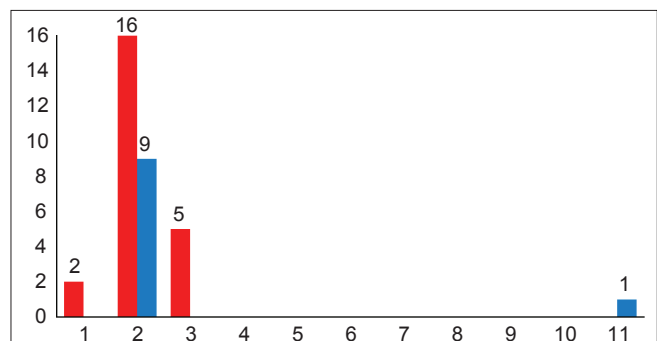
transpedicular arthrodesis (dynamic, rigid, or combined) or ligamentoplasty or semirigid posterior stabilization (Diam and Wallis interspinous device) in the previous surgery. There were 4 (15%) patients with simple hemilaminectomy or laminectomy and discectomy in the previous surgery and 26 (85%) with transpedicular

arthrodesis (dynamic, rigid, or combined) or semirigid posterior stabilization (Diam and Wallis interspinous device) in the previous surgeries in the second group. L5-S1 fusion was performed in 11 (44%) patients in the first group, L4-L5 fusion was performed in 5 (20%) patients, and L4-S1 was performed in 9 (36%) patients. L5-S1 fusion was performed in 10 (34%) in the second group, L4-L5 fusion was performed in 6 (20%) patients, and L4-S1 was performed in 14 (46%) patients. The average follow-up period was 200.6 months in the first group (screws and intersomatic bone) and 184.4 months in the second group (screws and B-Twin). In the autologous bone group, 3 patients had accidental dural tear. In the B Twin group, 2 patients had accidental dural tear during surgical exposure, but it not related to the B Twin introducer. In all cases of B Twin group, the restoration of lumbar lordosis could be achieved. In one case of the B Twin group, the B Twin was placed in position but could not be expanded properly or retrieved and was therefore left in the same place. Its position was further reinforced with cancellous bone chips. All patients had neurologic uneventful post-operative period. The complications included that, three superficial wound infections in the first group could be controlled with intravenous antibiotic for 3 weeks. In the second group, there were 3 cases of superficial wound infections, which were controlled with intravenous antibiotic for 3 weeks and 1 patient needed Freidrich debridement also. The patient's B Twin was not be expended properly and he was doing well at 3-months follow-up. His CT scan showed that the implant was not touching the dura or the nerve, but he still complained of radicular pain and was, therefore, referred to the pain clinic with moderate relief in his symptoms. After 1 year follow-up, the patient was referred again to us for recurrence of radicular pain in the same dermatome and with suspicion of B Twin movement inside the intervertebral space. We retired the B Twin and completed the arthrodesis by anterolateral fixation with screws [Figure 4a and b]. Two patients in the B Twin group presented with an accelerated degeneration in the upper level vertebral body and needed infiltration in the first 6-months follow-up. However, they did not respond to conservative management, and selective rizotomy was performed in the first year. These 2 patients also developed scoliotic deformity



**Figure 4:** (a) The B Twin not expended properly and in the first year follow-up migrated inside the intervertebral space and provoked radicular pain; (b) The B Twin was displaced and antero-lateral screws reinforcement arthrodesis was performed

and were operated 3 years after the first surgery and another level was fused at another hospital. However, 7 patients (28%) in the first group and 14 patients (46%) in the second group needed infiltration in superior articular facet or sacroiliac joint during the follow-up period between the first and third years of follow-up. In the second year, 4 patients were followed up: 2 patients in each group presented with recurrence of radicular pain and clinical signs of nerve root compression. One patient in B Twin group was re-operated and a foraminotomy was performed at that level in the third year of follow-up. In 2012, 1 patient of the first group was operated for a suprayacent bilateral foraminal estenosis and the fixation from L5-S1 until L4-S1 was completed with L4 laminectomy and bilateral foraminotomy 11 years after the surgery [Figure 5]. There were significant reductions in pain and significant improvements in functions in both the fusion groups and there were no significant differences between the two groups. A total of 14 (55%) patients in the first group and 18 (60%) in the second group had a Patient Satisfaction Index (PSI) of 1 or 2 and their surgeries were therefore considered successful. There was no difference in patient satisfaction between the groups. There was no difference in PSI between simple hemilaminectomy versus transpedicular screws revision surgeries. In addition, the number of levels fused did not directly influence the clinical outcomes. We observed no differences within each group or between the groups for one-level versus two-level fusions. There were 32 (58%) workers' compensation or in litigation for compensation, but only 7 (13%) of the injured workers received a compensation. A total of 7 patients in the first group returned to work, but none at the same place where they worked before the surgery, and 10 patients of the second group returned to work, but none in the same place as before the surgery. None of the patients were who were eligible for worker compensation returned to work after surgery. After a 24-months follow-up, 48 (86%) patients presented radiographic fusion: 20 (80%) patients in the first group and 28 (94%) in the second group. In the autologous bone graft group, the loss of height was 25-45% and patients continued to loose the height until 20 months after the surgery [Figures 6 and 7]. Over a period of 9-months follow-up, the loss of height of the intervertebral level in the B Twin group was of 8-12% and it stabilized in that position



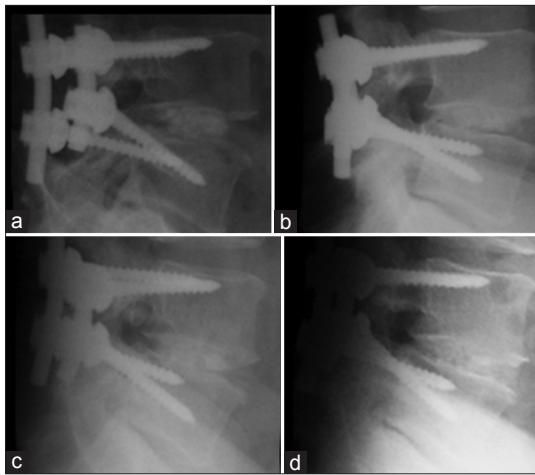
**Figure 5:** A 10-year follow-up and the incidence of back pain and leg pain that required invasive intervention

[Figures 8 and 9]. However, we did not find any correlation between the loss of height and the clinical outcome at the same level after surgery. In radiological control during the follow-up period, the fusion surgery has transferred problems to another level of the spine in 10 cases in the first group and 17 cases in the second group; we observed this change after 5-years follow-up. Only 1 patient in the first group and 2 patients in the second group referred to neurological claudication in the past 2 years. The claudication appears after >45 min walking, and conservative treatment was decided.

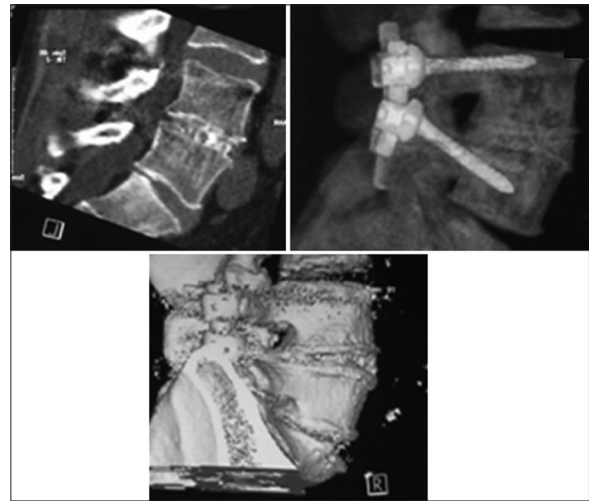
## Discussion

The post-operative causes of back pain could be deconditioning, muscle spasm, myofascial pain, spinal instability, diskogenic pain, facet arthropathy, infection, pseudarthrosis, loose hardware, arachnoiditis, trauma, wrong level fused, insufficient levels fused, pseudomeningocele, graft donor site


pain, and psychosocial factors. The post-operative causes of leg pain could be retained disk fragment, recurrent herniated nucleus pulposus, far lateral disk, lateral recess stenosis, inadequate decompression, wrong level decompressed, nerve root injury, retained foreign body, epidural fibrosis, arachnoiditis, synovial cyst, root sleeve meningocele, loose hardware, facet fracture, and psychosocial factors. Spine surgery was able to accomplish only two requirements: Decompress a nerve root that is pinched and stabilize a painful joint. Despite complete healing, substantial axial disc motion can continue with posterolateral fusion;<sup>[10]</sup> this lead to the concept of discogenic pain<sup>[11,12]</sup> and this pain may persist despite a solid posterolateral fusion.<sup>[11,13]</sup> Although the combined anterior interbody fusion and posterior fusion (360 fusion or circumferential fusion) was developed with the aim of enabling better correction with more space for adequate neural decompression, which gained popularity in the mid



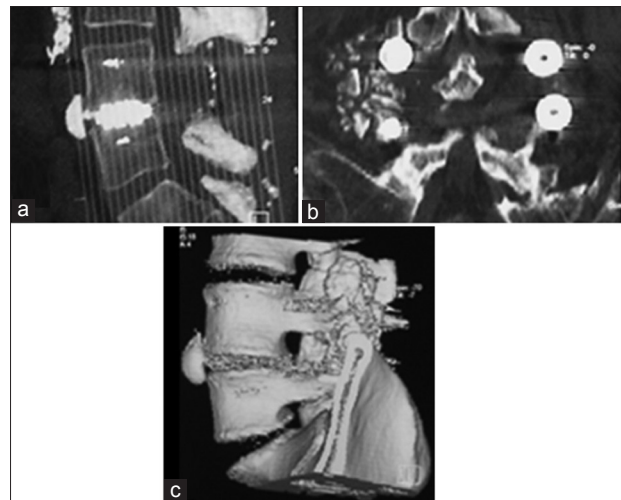
**Figure 6:** Follow-up X-ray images (a = 0, b = 3, c = 12, and d = 24 months, respectively) showing fusion but at the same time reduction in the disc (autologus bone graft)



**Figure 7:** Follow-up CT images with 3-D reconstruction showing solid fusion (autologus bone graft)



**Figure 8:** Follow-up X-ray images (a = 0, b = 3, c = 12 months, respectively) showing fusion (B-Twin system), but note lesser loss of disc space in comparison to autologus bone graft (compare with Figure 2)



**Figure 9:** Follow-up CT images with 3-D reconstruction showing solid fusion (B Twin system) (a) Sagittal image; (b) Axial image and (c) 3d reconstruction

1970s,<sup>[14-16]</sup> the implementation of this procedure has become widespread for the management of FBSS and discogenic pain in the last decade.<sup>[11,13]</sup> If the disc is suspected instead, it seems reasonable to remove this structure and replace it with a bone transplant using either PLIF or anterior lumbar interbody fusion (ALIF).<sup>[17-19]</sup> If pain is believed to be generated from disc and facets or both these structures or if the surgeon strives for maximum initial stability and bone transplant area, hypothetically, it should be better to fuse from both the behind and the front to create a “circumferential” (360) fusion.<sup>[13,20-22]</sup> While general controversy on the use of circumferential procedures in the management of degenerative disc disease prevails in the literature, many studies have nevertheless reported evidence that circumferential fusion may provide better results than posterolateral fusion.<sup>[11,23,24]</sup> A recent study indicated that patients with disc degeneration require some form of stabilization to support a posterolateral spinal fusion procedure.<sup>[25]</sup> It has been claimed that circumferential lumbar spinal fusion theoretically affords several advantages over posterolateral spinal fusion alone. One advantage of combined anterior and posterior stabilization is that it provides a more complete stability, which in turn would improve fusion rates.<sup>[24,26]</sup> These techniques may be supplemented by internal fixation, aiming at immediate stability, which increases the fusion rate and hopefully makes the rehabilitation process easier for the patient.<sup>[27,28]</sup> Experimental studies have shown that the use of additional posterior instrumentation significantly increases motion stability in extension and axial rotation.<sup>[29,30]</sup> The incidence of complications varies from 0% to >30%, with a general figure of 2-5% for clinically significant misplacement.<sup>[31,32]</sup> Complications in these patients include deep venous thrombosis, postoperative pneumonia, superficial wound infection, urinary tract infections, donor site wound hematoma and persistent iliac crest donor site pain. However, we have the following complications: 3 superficial wound infections in each group (12-10%, respectively) and 1 case of misplacement (3,4% in the B Twin group) in our series. PLIF offers several advantages. It restores disc height, load-bearing ability of anterior ligaments and muscles, root canal dimensions, and spinal balance. It immobilizes the painful degenerate spinal segment and decompresses the nerve roots.<sup>[33,34]</sup> Other authors have reported >70% satisfactory clinical results when interbody fusion is combined with instrumented posterolateral fusion.<sup>[33-37]</sup> Cessation of abnormal motion of an annular torn disc and removal of biochemical substances in the degenerated disc should eliminate the nociceptive stimulation from the outer annulus.<sup>[38,39]</sup> Because the motion segment is a three-joint complex comprised of a disc and two facet joints, the highest rate of fusion is obtained from supplementary fixation of the facet joints behind the anterior graft used for PLIF.<sup>[2]</sup> Supplementing this fixation and interbody graft with a posterolateral bone graft will further improve the fusion rate. The current study showed that the patients who had doubtful interbody fusion had solid

posterolateral arthrodeses. Leufven and Nordwall reported a 93% fusion rate and 73% satisfactory outcome using a circumferential fusion technique, and 62% of patients returned to work.<sup>[22]</sup> Results of the fusion in one study with posterolateral fusion showed 81.5% fusion rate, and PLIF had 90.5% fusion rate, but successful fusion does not directly correlate with a successful clinical result.<sup>[38,39]</sup> Other surgeons are concerned about the risks with PLIF. When PLIF is performed with bone dowels, there is a risk of graft resorption and disc space collapse, which has led many surgeons to add posterior instrumentation to stabilize the construct. Others have used cylindrical cages to overcome this disadvantage, which has led to other problems. According to the literature, the clinical outcome regarding working ability is better after PLIF, possibly because of better restoration of disc height lumbar lordosis and load distribution through the spine.<sup>[40]</sup> Gertzbein *et al.*, reported significant reductions in pain and 97% radiographic fusion rate in 68 patients after circumferential fusions. Some surgeons prefer PLIF to 360 fusions citing comparable results with only single surgery. Lee *et al.*, performed PLIF without PINS for discogenic back pain in 62 patients and had 89% satisfactory result.<sup>[41]</sup> Early results of instrumented PLIF and use of a carbon fiber cage for interbody fusion have been encouraging.<sup>[35,37]</sup> Circumferential fusion became popular as both a primary fusion technique and a salvage procedure. It allows nearly complete discectomy for discogenic pain, full decompression of severe foraminal or central stenosis, inspection of the spinal canal, and removal of large disc extrusions or fragments. There is a high fusion rate and a high degree of patient satisfaction.<sup>[13,36,42]</sup> Kozak and O'Brien reported a very high fusion rate and 80% favorable results with 360 fusions in 69 patients with severe low back pain and positive discography.<sup>[21]</sup> Hinkley and Jaremko reported significant improvements in pain, function, and disability in 81 injured workers treated with 360 fusion for low back pain and positive discography. They noted a 95-100% fusion rate and 91% patient satisfaction.<sup>[42]</sup> Clinical studies of patients with chronic back pain provide strong evidence that psychological distress is an important risk factor for having poor outcomes after spine surgery.<sup>[43,44]</sup> Other studies have shown that both the inability to work for long periods and inability to find a job after rehabilitation are factors underlying failure to return to work.<sup>[45,46]</sup> In one study, 50% pain reduction was achieved in <50% of the patients and only 30% patients could returned to work.<sup>[2,47]</sup> In our study, only 7 (28%) patients in the first group returned to work, but none at the same place as before the surgery, and 10 (34%) patients of the second group returned to work, but none at the same place as before the surgery. None of the patients who were eligible worker compensation or injured workers returned to work after the surgery. Furthermore, individuals nearing retirement age might use their back surgery as a justification for seeking early retirement, thus being psychologically inclined to adopt the disabled role.<sup>[25]</sup> Retrospective studies on scoliosis as well as

longitudinal studies on lumbar fusion have suggested that lower lumbar fusions predispose patients to problems in the adjacent motion segments.<sup>[48-52]</sup> In our study, the B Twin allowed an excellent restoration of lordosis, but the distress in the adjacent level was much higher and the facetary syndrome and accelerated degeneration in the adjacent level was double (two-times higher) in comparison with those in the autologous bone group. The disadvantage of classical 360 fusion is that it requires two surgeries (one anterior and one posterior) and that it may require an additional surgery later to remove the instrumentation.<sup>[53]</sup> A total of 36% patients in the autologous bone group and 53% patients in the B Twin group developed lumbar pain that was needed some kind of treatment in the first 3-years follow-up. Although we achieve a good fixation at the affected segment with circumferential fusion, it may not translate in terms of good clinical outcomes, particularly, pain control. With this study, we felt that the question of whether or not circumferential fusion should be the preferred treatment for FBSS is an option and not the solution, and it therefore needs further investigation to resolve the specific pain that disables the patient and not to restore all the bone architecture and foramen diameters.<sup>[26]</sup>

## Conclusion

Circumferential lumbar fusion is a useful procedure for FBSS patients. Interbody fixation restores lumbar lordosis and removes the biochemical and mechanical sources of pain, and pedicle screws and B Twin together provide stability and rigid fixation until solid fusion is obtained. However, the patients with rigid fixation do well in terms of correction of lumbar lordosis but they do not do well in terms of recurrence of pain, as they need some kind of intervention to control pain from 1 to 3 years of follow-up. In patients in whom bone graft is used, although they do not maintain and sustain the lumbar lordosis in long term, they experience less recurrence of pain with less chances of intervention for pain control and have maximum incidence in the second year follow-up. All these facts supports that the radiologically and mechanically solid arthrodesis does not always result in a good clinical outcome.

## References

- Frymoyer JW. The role of spine fusion: Question 3. *Spine* 1981;6:284-90.
- Nachemson A, Zdeblick TA, O'Brien JP. Controversy: Lumbar disc disease with discogenic pain. What surgical treatment is most effective? *Spine* 1996;1:1835-8.
- Frymoyer JW, Cats-Baril WL. An overview of the incidence and costs of low back pain. *Orthop Clin North Am* 1991;22:263-71.
- Snook SH. Low back pain in industry. In: White 3<sup>rd</sup>, Gordon SL, editors. *American Academy of Orthopaedic Surgeons Symposium on Idiopathic Low Back Pain*. St. Louis: Mosby; 1982. p. 23-38.
- Spengler DM, Bigos SJ, Martin NA, Zeh J, Fishser L, Nachemson A. Back injuries in industry: A retrospective study. I. Overview and cost analysis. *Spine (Phila Pa 1976)* 1986;1:241-5.
- Katz JN. Lumbar spinal fusion. Surgical rates, costs, and complications. *Spine (Phila Pa 1976)* 1995;20 Suppl 24:78S-83.
- Deyo RA, Nachemson A, Mirza SK. Spinal-fusion surgery: The case for restraint. *N Engl J Med* 2004;350:722-6.
- Deyo RA, Battie M, Beurskens AJ, Bombardier C, Croft P, Koes B, *et al.* Outcome measures for low back pain research. A proposal for standardized use. *Spine (Phila Pa 1976)* 1998;23:2003-13.
- Fairbank JC, Couper J, Davies JB, O'Brien JP. The Oswestry low back pain disability questionnaire. *Physiotherapy* 1980;66:271-3.
- Rolander SD. Motion of the lumbar spine with special reference to the stabilizing effect of posterior fusion. An experimental study on autopsy specimens. *Acta Orthop Scand* 1966;Suppl 90:1-144.
- Barrick WT, Schofferman JA, Reynolds JB, Goldthwaite ND, McKeehen M, Keaney D, *et al.* Anterior lumbar fusion improves discogenic pain at levels of prior posterolateral fusion. *Spine (Phila Pa 1976)* 2000;25:853-7.
- O'Brien JP, Dawson MH, Heard CW, Momberger G, Speck G, Weatherly CR. Simultaneous combined anterior and posterior fusion. A surgical solution for failed spinal surgery with a brief review of the first 150 patients. *Clin Orthop Relat Res* 1986;203:191-5.
- Gertzbein SD, Hollopeter M, Hall SD. Analysis of circumferential lumbar fusion outcome in the treatment of degenerative disc disease of the lumbar spine. *J Spinal Disord* 1998;11:472-8.
- Kostuik JP, Maurais GR, Richardson WJ, Okajima Y. Combined single stage anterior and posterior osteotomy for correction of iatrogenic lumbar kyphosis. *Spine (Phila Pa 1976)* 1988;13:257-66.
- Lagrone MO, Bradford DS, Moe JH, Lonstein JE, Winter RB, Ogilvie JW. Treatment of symptomatic flatback after spinal fusion. *J Bone Joint Surg Am* 1988;70:569-80.
- McPhee IB, O'Brien JP. Reduction of severe spondylolisthesis. A preliminary report. *Spine (Phila Pa 1976)* 1979;4:430-4.
- Cloward RB. Lesions of the intervertebral disks and their treatment by interbody fusion methods. *Clin Orthop Relat Res* 1963;27:51-77.
- Friberg S, Hirsch C. Anatomical and clinical studies on lumbar disc degeneration. 1950. *Clin Orthop Relat Res* 1992;279:3-7.
- Steffee AD, Sitkowski DJ. Posterior lumbar interbody fusion and plates. *Clin Orthop Relat Res* 1988;227:99-102.
- Eisenstein SM. Circumferential spinal fusion. *The Adult Spine: Principles and Practice*. Philadelphia: Lippincott-Raven; 1997. p. 2253-61.
- Kozak JA, O'Brien JP. Simultaneous combined anterior and posterior fusion: An independent analysis of a treatment for the disabled low-back pain patient. *Spine (Phila Pa 1976)* 1990;15:322-8.
- Leufven C, Nordwall A. Management of chronic disabling low back pain with 360 degrees fusion: Results from pain provocation test and concurrent posterior lumbar interbody fusion, posterolateral fusion, and pedicle screw instrumentation in patients with chronic disabling low back pain. *Spine (Phila Pa 1976)* 1999;24:2042-5.
- Albert TJ, Pinto M, Denis F. Management of symptomatic lumbar pseudarthrosis with anteroposterior fusion. A functional and radiographic outcome study. *Spine (Phila Pa 1976)* 2000;25:123-9.
- Gertzbein SD, Hollopeter MR, Hall S. Pseudarthrosis of the lumbar spine. Outcome after circumferential fusion. *Spine (Phila Pa 1976)* 1998;23:2352-6.
- Christensen FB, Hansen ES, Eiskjær SP, Høy K, Helmig P, Neumann P, *et al.* Circumferential lumbar spinal fusion with Brantigan cage versus posterolateral fusion with titanium Cotrel-Dubouset instrumentation: A prospective, randomized clinical study of 146 patients. *Spine (Phila Pa 1976)* 2002;27:2674-83.
- Rathonyi GC, Oxland TR, Gerich U, Grassmann S, Nolte LP. The role of supplemental translamina screws in anterior lumbar interbody fixation: A biomechanical study. *Eur Spine J* 1998;7:400-7.
- Boos N, Webb JK. Pedicle screw fixation in spinal disorders: A European view. *Eur Spine J* 1997;6:12-8.
- Gibson JN, Grant IC, Waddell G. The Cochrane review of surgery for lumbar disc prolapse and degenerative lumbar spondylosis. *Spine (Phila Pa 1976)* 1999;24:1820-32.
- Lund T, Oxland TR, Jost B, Crompton P, Grassmann S, Etter C, *et al.* Interbody cage stabilisation in the lumbar spine: Biomechanical evaluation of cage design, posterior instrumentation, and bone density. *J Bone Joint Surg Br* 1998;80:351-9.
- Volkman T, Horton WC, Hutton WC. Transfacet screws with lumbar interbody reconstruction: Biomechanical study of motion segment stiffness. *J Spinal Disord* 1996;9:425-32.

31. Hsu J, Zucherman JF, White A. Internal fixation with pedicle screws. In: White AH, Rothman RH, Roy CD, editors. *Lumbar Spinal Surgery*. St. Louis: C.V. Mosby; 1987. p. 322-38.
32. Farber GL, Place HM, Mazur RA, Jones DE, Damiano TR. Accuracy of pedicle screw placement in lumbar fusions by plain radiographs and computed tomography. *Spine (Phila Pa 1976)* 1995;20:1494-9.
33. Brantigan JW, Steffee AD, Geiger JM. A carbon fiber implant to aid interbody lumbar fusion: Mechanical testing. *Spine (Phila Pa 1976)* 1991;16:S277-82.
34. Enker P, Steffee AD. Interbody fusion and instrumentation. *Clin Orthop Relat Res* 1994;300:90-101.
35. Brantigan JW, Steffee AD. A carbon fiber implant to aid interbody lumbar fusion. Two-year clinical results in the first 26 patients. *Spine (Phila Pa 1976)* 1993;18:2106-6.
36. Gertzbein SD, Betz R, Clements D, Errico T, Hammerberg K, Robbins S, *et al.* Semirigid instrumentation in the management of lumbar spinal conditions combined with circumferential fusion: A multicenter study. *Spine (Phila Pa 1976)* 1996;21:1918-26.
37. Tullberg T, Brandt B, Rydberg J, Fritzell P. Fusion rate after posterior lumbar interbody fusion with carbon fiber implant: 1-year follow-up of 51 patients. *Eur Spine J* 1996;5:178-82.
38. Mooney V. Presidential address. International Society for the Study of the Lumbar Spine. Dallas, 1986. Where is the pain coming from? *Spine (Phila Pa 1976)* 1987;12:754-9.
39. Weinstein J, Claverie W, Gibson S. The pain of discography. *Spine (Phila Pa 1976)* 1988;13:1344-8.
40. Smith SE, Darden BV, Rhyne AL, Wood KE. Outcome of unoperated discogram-positive low back pain. *Spine (Phila Pa 1976)* 1995;20:1997-2001.
41. Lee CK, Vessa P, Lee JK. Chronic disabling low back pain syndrome caused by internal disc derangements. The results of disc excision and posterior lumbar interbody fusion. *Spine (Phila Pa 1976)* 1995;20:356-61.
42. Hinkley BS, Jaremko ME. Effects of 360-degree lumbar fusion in a workers' compensation population. *Spine (Phila Pa 1976)* 1997;22:312-23.
43. Schade V, Semmer N, Main CJ, Hora J, Boos N. The impact of clinical, morphological, psychosocial and work-related factors on the outcome of lumbar discectomy. *Pain* 1999;80:239-49.
44. Trief PM, Grant W, Fredrickson B. A prospective study of psychological predictors of lumbar surgery outcome. *Spine (Phila Pa 1976)* 2000;25:2616-21.
45. Bendix AF, Bendix T, Hastrup C. Can it be predicted which patients with chronic low back pain should be offered tertiary rehabilitation in a functional restoration program? A search for demographic, socioeconomic, and physical predictors. *Spine (Phila Pa 1976)* 1998;23:1775-84.
46. Polatin PB, Gatchel RJ, Barnes D, Mayer H, Arens C, Mayer TG. A psychosociomedical prediction model of response to treatment by chronically disabled workers with low-back pain. *Spine (Phila Pa 1976)* 1989;14:956-61.
47. Franklin GM, Haug J, Heyer NJ, McKeefrey SP, Picciano JF. Outcome of lumbar fusion in Washington state workers' compensation. *Spine (Phila Pa 1976)* 1994;19:1897-904.
48. Cochran T, Irstam L, Nachemson A. Long-term anatomic and functional changes in patients with adolescent idiopathic scoliosis treated by Harrington rod fusion. *Spine (Phila Pa 1976)* 1983;8:576-84.
49. Brodsky AE. Post-laminectomy and post-fusion stenosis of the lumbar spine. *Clin Orthop Relat Res* 1976;115:130-9.
50. Hambly MF, Wiltse LL, Raghavan N, Schneiderman G, Koenig C. The transition zone above a lumbosacral fusion. *Spine (Phila Pa 1976)* 1998;23:1785-92.
51. Lee CK. Accelerated degeneration of the segment adjacent to a lumbar fusion. *Spine (Phila Pa 1976)* 1988;13:375-7.
52. Lehmann TR, Spratt KF, Tozzi JE, Weinstein JN, Reinartz SJ, el-Khoury GY, *et al.* Long-term follow-up of lower lumbar fusion patients. *Spine (Phila Pa 1976)* 1987;12:97-104.
53. Hume M, Capen DA, Nelson RW, Nagelberg S, Thomas JC Jr. Outcome after Wiltse pedicle screw removal. *J Spinal Disord* 1996;9:121-4.

**How to cite this article:** Cincu R, Lorente Fd, Gomez J, Eiras J, Agrawal A. A 10-year follow-up of transpedicular screw fixation and intervertebral autogenous posterior iliac crest bone graft or intervertebral B-Twin system in failed back surgery syndrome. *Asian J Neurosurg* 2015;10:75-82.

**Source of Support:** Nil, **Conflict of Interest:** None declared.

### "Quick Response Code" link for full text articles

The journal issue has a unique new feature for reaching to the journal's website without typing a single letter. Each article on its first page has a "Quick Response Code". Using any mobile or other hand-held device with camera and GPRS/other internet source, one can reach to the full text of that particular article on the journal's website. Start a QR-code reading software (see list of free applications from <http://tinyurl.com/yzlh2tc>) and point the camera to the QR-code printed in the journal. It will automatically take you to the HTML full text of that article. One can also use a desktop or laptop with web camera for similar functionality. See <http://tinyurl.com/2bw7fn3> or <http://tinyurl.com/3ysr3me> for the free applications.