

## CASE REPORT

# Spontaneous thrombosis of a vein of galen malformation

Chandan B. Mohanty, Dwarakanath Srinivas, Somanna Sampath

Department of Neurosurgery, National Institute of Mental Health and Neurosciences, Hosur Road, Bangalore, Karnataka, India

## ABSTRACT

Vein of Galen malformation (VOGM) is a rare congenital vascular anomaly, comprising about 1% of all intracranial vascular anomalies, predominantly affecting the children less than 1 year of age. A 6-month-old infant presented with complaints of increasing head size of 3 months duration and multiple episodes of vomiting associated with refusal to feed since 7 days. He was a known case of VOGM who had initially refused treatment. Investigations revealed a spontaneously thrombosed VOGM with obstructive hydrocephalous. Child improved uneventfully with ventriculoperitoneal shunt. Spontaneous thrombosis of a VOGM is a rare occurrence and carries a better prognosis. The relevant literature is discussed with emphasis on etiopathogenesis, mechanism, and management of spontaneous thrombosis of the malformation.

**Key words:** Hydrocephalus, management, spontaneous thrombosis, vein of galen malformation

## Introduction

Vein of Galen malformation (VOGM) is a rare congenital anomaly comprising about 1% of all intracranial vascular anomalies.<sup>[1]</sup> Neonatal VOGMs have dismal prognosis, especially in those who present with congestive cardiac failure (CCF). Only 35 cases of spontaneous thrombosis of these malformations have been reported and it has a better prognosis.<sup>[2]</sup> We report one such case and discuss the relevant literature.

## Case Report

A 6-month-old male child, detected to have VOGM on a routine antenatal ultrasound scan at 8 months of gestation, was born of an uneventful full-term normal delivery. Parents at that time refused treatment and the child was on regular follow-up. Since the age of 3 months, parents noticed increasing head size. Computed tomography (CT) revealed well-defined predominantly hyperdense posterior third ventricular mass

enhancing brilliantly and uniformly, causing obstruction at the aqueduct and hydrocephalus. Child was referred to us at 6 months of age with increasing head size and associated vomiting since 7 days. Child was irritable with head circumference of 49cm, bulging fontanelle, and sun-set sign. His systemic evaluations including cardiac work-up were normal. CT showed thrombosis of the malformation with gliotic changes in the right parieto-occipital lobes and increasing hydrocephalus. Angiogram revealed thrombosis of the malformation. Deep venous system was not visualized [Figure 1]. Magnetic resonance imaging (MRI) revealed a thrombosed VOGM [Figure 2]. Child underwent frontal ventriculoperitoneal shunt (VPS) and recovered uneventfully. Follow-up CT showed reduction in the size of VOGM and ventricle [Figure 3]. Three months after VPS, the child is active without any neurological deficits.

## Discussion

### Embryology

VOGM is an ectatic median prosencephalic vein of Markowisk, the embryonic precursor of vein of Galen. It develops due to persistent communication between primitive choroidal arteries and median vein of Markowisk, which are normally present during the 6<sup>th</sup>-11<sup>th</sup> week of embryonic life.<sup>[2]</sup> It is an extra-cerebral, intra-arachnoidal malformation located in the velum interpositum<sup>[3]</sup> connecting the straight sinus with subarachnoid venous system. It is not impeded by dura, hence assumes a large size due to increased blood flow.

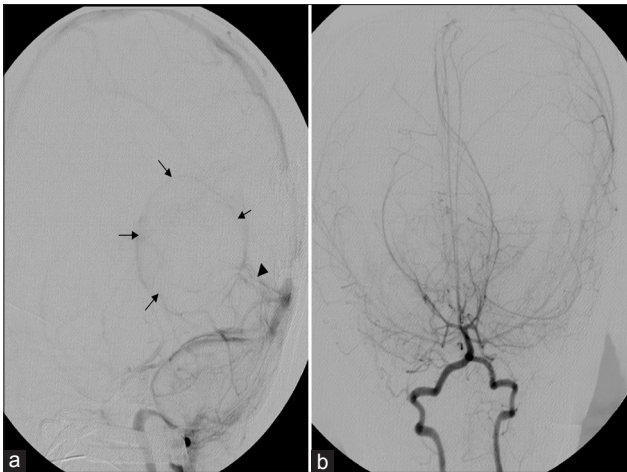
### Imaging

CT features suggestive of thrombosis include a mixed-density lesion with a “target-sign” pattern of contrast enhancement

Access this article online	
Quick Response Code:	Website: www.asianjns.org
	DOI: 10.4103/1793-5482.145166

### Address for correspondence:

Dr. Dwarakanath Srinivas, Department of Neurosurgery, NIMHANS, Hosur Road, Bangalore, Karnataka, India.  
E-mail: dwarakaneuro@yahoo.com



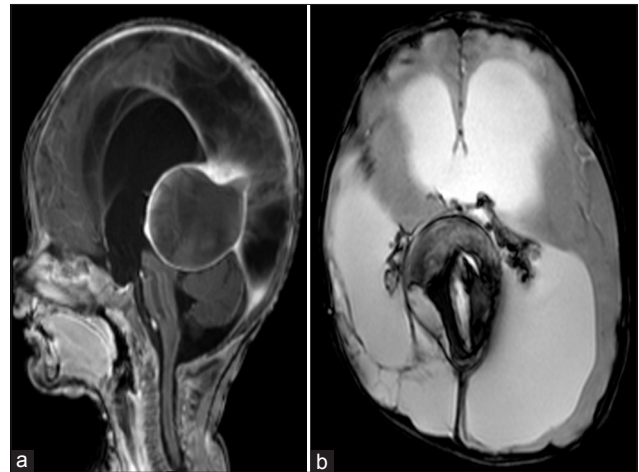
**Figure 1:** Digital subtraction angiogram (DSA). (a) Angiogram of the venous phase (lateral view) reveals non-visualization of the deep venous system. Rim of the VGAM (small arrows) and the straight sinus (arrowhead) are faintly visible. Falcine sinus is not seen. (b) Arterial phase posterior circulation (AP view): No prominent thalamoperforators or other arterial feeders are noted

with calcification. T1-weighted MRI reveals central hyperintense methemoglobin with peripheral hypointense hemosiderin. Older clots are situated peripherally, while the recent clots are near the center close to the origin of the malformation. MR angiography and Doppler reveal blood stagnation.<sup>[1]</sup> Angiography reveals non-opacification of the deep venous system and stagnation of contrast material until late venous phase.<sup>[1]</sup>

### Management of VOGM and hydrocephalus

Management has evolved from bilateral internal carotid artery ligation to the present endovascular strategies. CCF is suggestive of high-flow status, has a poorer outcome, and early, aggressive management is mandated. It is preferable to postpone treatment till the child is 5-6 months of age.<sup>[4]</sup> Transtorcular embolization of the dilated vein reduces the arteriovenous fistula and improves CCF. Transvenous/transarterial embolizations are difficult to perform because of small-sized vessels. Microsurgical obliteration employing occipital-transtentorial and infratentorial supracerebellar approaches have also been described.<sup>[1]</sup> Radiosurgery has not been used widely due to its latent period.<sup>[1]</sup>

Hydrocephalus is secondary to venous hypertension and direct obstruction of CSF pathway.<sup>[1]</sup> CSF diversion before the obliteration of the malformation can lead to subdural or intraventricular bleed and also causes reversal of blood flow in the medullary veins, leading to brain hypoperfusion. Hydrocephalus usually resolves if the malformation is obliterated, and thus can be managed conservatively if the disease process is slow. Therefore, shunts are usually performed after completion of embolization.<sup>[4]</sup> Frontal shunts have been advocated to avoid engorged veins in the parietal region.<sup>[5]</sup>



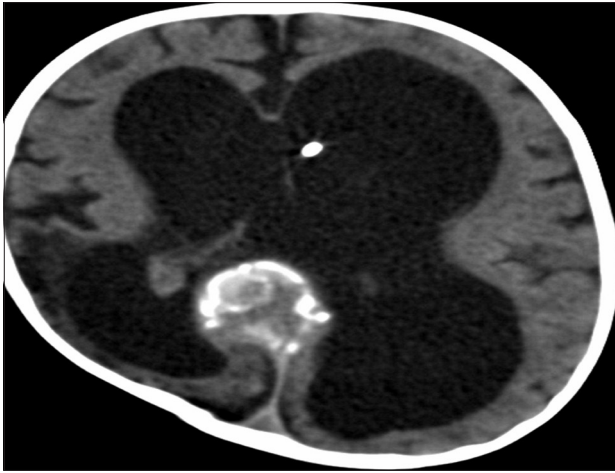
**Figure 2:** (a) T1-weighted MRI sagittal view (post-contrast) shows enhancement of the periphery of the VGAM with compression of the tectal plate and aqueduct causing obstructive hydrocephalus. (b) T2-weighted MRI axial view reveals heterointense signals suggestive of varying stages of bleed within the lesion

### Spontaneous thrombosis

Spontaneous thrombosis is a rare phenomenon comprising 2.5% of 317 patients reported.<sup>[4]</sup> Multiple mechanisms of thrombosis are proposed, but this event is not well understood. The pathogenesis of thrombosis is explained by Virchow's triad: 1) endothelial injury, 2) hemodynamic turbulence, stasis, and 3) hypercoagulability. The following factors are responsible for thrombosis as mentioned in literature: 1) vessel spasm, 2) perilesional hematoma or edema, and 3) regressive changes in vessel wall.<sup>[6]</sup> Low blood flow with insufficient venous drainage and venous turbulence leads to proliferation of intimal layer and vessel obliteration. Contrast media causing post-angiography thrombosis are reported secondary to platelet activation, RBC aggregation, and endothelial changes.<sup>[7]</sup> VOGMs can be associated with absence or thrombosis of straight sinus, persistence of fetal venous sinus like the falcine sinus producing turbulence, thus promoting thrombosis.<sup>[7]</sup>

Mural type of VOGM, due to its low-flow state, has a higher chance of spontaneous thrombosis than the high-flow choroidal type. Spontaneous thrombosis has also been reported after CSF shunting and aseptic meningitis. Spontaneous disappearance of VOGM without thrombosis has also been reported due to obliteration of the feeding arteries.<sup>[2,8]</sup> None of the cases with spontaneous thrombosis had accompanying CCF, thus suggesting that low-flow VOGMs are more likely to develop thrombosis.<sup>[2]</sup>

Timing of thrombosis is highly variable. Initially, it was proposed that thrombosis begins antenatally or during birth, but presence of fresh clots and organized thrombi noted at surgery has refuted this claim.<sup>[6]</sup> Factors like age and sex have no predictive value to determine thrombosis. Age at



**Figure 3:** CT head performed at follow-up shows decreased ventricle size and decreasing size of VGAM with areas of calcification around the rim. Shunt tip is seen in left frontal horn, and sulci and gyri are better seen

thrombosis in literature varies from fetal age of 21 weeks to adult age of 40 years.<sup>[2]</sup>

### Outcome

The mortality of VOGM ranges from 4 to 40%, and mortality amongst neonates is 52.1%.<sup>[4]</sup> Spontaneous thrombosis is associated with a good outcome in about 70% of the cases.<sup>[2]</sup> Outcome depends on the degree of arteriovenous shunting. Low-flow shunt has better outcome than high-flow shunt, since shunting of blood from brain parenchyma causes infarcts and accompanying CCF with high-flow shunt.<sup>[4]</sup> Patients with dystrophic calcifications, infarcts, and cerebral atrophy have a poor outcome irrespective of treatment modality. Jugular bulb

patency has been proposed as a determinant of the overall outcome in VOGM. Jugular bulb stenosis prevents CCF, but exposes the brain to the risk of venous infarcts.<sup>[4]</sup>

The causes of thrombosis in VOGM are multifactorial and it usually has better prognosis.

### References

1. Hamilton MG, Herman JM, Khayata MH, Spetzler FR. Aneurysms of the vein of Galen. In: Youmans JR, editor. Neurological Surgery. 4<sup>th</sup> ed. Philadelphia: Saunders; 1996. p. 1491-510.
2. Moftakhar P, Danielpour M, Maya M, Alexander M. Spontaneous thrombosis of neonatal vein of Galen malformation. Neurosurg Focus 2009;27:E12.
3. Brunelle F. Arteriovenous malformation of the vein of Galen in children. Pediatr Radiol 1997;27:501-13.
4. Lasjaunias PL, Chng SM, Sachet M, Alvarez H, Rodesch G, Garcia-Monaco R. The management of vein of Galen aneurysmal malformations. Neurosurgery 2006;59:S184-94.
5. Jones BV, Ball WS, Tomsick TA, Millard J, Crone KR. Vein of Galen aneurysmal malformation: Diagnosis and treatment of 13 children with extended clinical follow-up. AJNR Am J Neuroradiol 2002;23:1717-24.
6. Nikas DC, Proctor MR, Scott RM. Spontaneous thrombosis of vein of Galen aneurysmal malformation. Pediatr Neurosurg 1999;31:33-9.
7. Konus OL, Ilgit ET, Ozdemir A, Onal B. Spontaneous thrombosis of a vein of Galen aneurysmal malformation: Possible effects of contrast media. Eur Radiol 2000;10:1456-8.
8. Abrao GP, Barbosa LA, Sa AT Jr, Caldas JG. Spontaneous thrombosis of a malformation of the vein of Galen. Arq Neuropsiquiatr 2010;68:648-50.

**How to cite this article:** Mohanty CB, Srinivas D, Sampath S. Spontaneous thrombosis of a vein of galen malformation. Asian J Neurosurg 2016;11:74-6.

**Source of Support:** Nil, **Conflict of Interest:** None declared.