

## CASE REPORT

# Primary CNS vasculitis masquerading as glioblastoma: A case report and review

Pelluru Pavan Kumar, Alugolu Rajesh, Rukmini Mrudula Kandadai<sup>1</sup>, Aniruddh Kumar Purohit, Challa Sundaram<sup>2</sup>

Departments of Neurosurgery, <sup>1</sup>Neurology and <sup>2</sup>Pathology, Nizam's Institute of Medical Sciences, Punjagutta, Hyderabad, Telangana, India

## ABSTRACT

Isolated angitis of the central nervous system (IACNS)/primary angitis of central nervous system vasculitis (PACNS) is an uncommon vascular disease, sparingly presenting as an isolated inflammatory lesion on magnetic resonance imaging (MRI). The disease usually manifests as a long-drawn and progressive ischemic event. Delay in diagnosis due to focal nature of the lesion also contributes to the poor prognosis as the dismal natural history and immunosuppressive therapy. To date, only a few cases with tumor-like isolated angitis of CNS have been reported with clear and definitive diagnostic workup.

**Key words:** Mimicking glioma, primary angitis, tumor-like lesion, vasculitis

## Introduction

Isolated angitis of the central nervous system (IACNS)/primary angitis of central nervous system (PACNS) represents a rare and poorly understood form of vascular inflammatory disease restricted to the brain and spinal cord. An average annual incidence rate of 2.4 cases per 1,000,000 persons per year has been reported.<sup>[1]</sup> Histopathology usually reveals granulomatous inflammation affecting arterioles and small arteries of the parenchyma or leptomeninges.<sup>[2]</sup> Nonspecific clinical manifestations and various imaging findings often lead to an incorrect or delayed diagnosis and treatment, particularly for an extremely rare form of tumor-like lesion. We herein present a case of IACNS presenting as mass lesion and raised intracranial tension.

## Case Report

A 56-year-old male, known hypertensive and diabetic on regular treatment presented to us with sudden onset of

behavioral changes for the past 10 days, which gradually progressed to urinary incontinence and difficulty in walking for about 5 days. There was no history of headache or vomiting. On examination, the patient was conscious; Mini-Mental State Examination (MMSE) was 24/30, with lack of spontaneity of speech with perseveration and spastic gait. All his routine investigations were within normal limits. Magnetic Resonance (MR) Imaging showed a hypointense to iso-intense lesion in the left frontal lobe, involving both gray and white matter on T1W [Figure 1a], which was hyper-intense on T2W, with disproportionate edema. T1W Gadolinium contrast study showed ring and central enhancement of the lesion. Abnormal enhancement of adjacent vessels and the falx was also noted [Figure 1b and c]. Single voxel MR spectroscopy showed increased lipid peak. Multi-voxel spectroscopy showed reduced N-acetylaspartate (NAA) and increased choline peak, with increased choline/creatinine ratio adjacent to lesion, which is suggestive of infiltration [Figure 2]. A provisional diagnosis of glioblastoma was made and patient was taken up for left frontal craniotomy and gross total excision of the lesion was done. Peroperatively, the lesion was grayish, soft to firm with blood clots. No clear gliotic plane was noted. Gross total excision of the lesion was performed.

This is an open access article distributed under the terms of the Creative Commons Attribution-NonCommercial-ShareAlike 3.0 License, which allows others to remix, tweak, and build upon the work non-commercially, as long as the author is credited and the new creations are licensed under the identical terms.

**For reprints contact:** reprints@medknow.com

**How to cite this article:** Kumar PP, Rajesh A, Kandadai RM, Purohit AK, Sundaram C. Primary CNS vasculitis masquerading as glioblastoma: A case report and review. Asian J Neurosurg 2017;12:69-71.

### Access this article online

#### Quick Response Code:



#### Website:

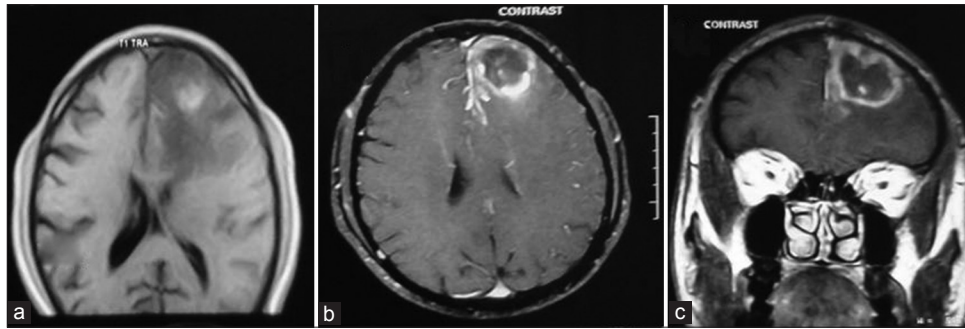
www.asianjns.org

#### DOI:

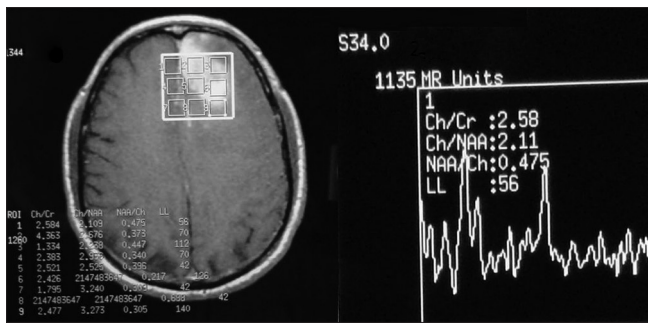
10.4103/1793-5482.145187

### Address for correspondence:

Dr. Alugolu Rajesh, Department of Neurosurgery, Nizam's Institute of Medical Sciences, Punjagutta, Hyderabad, Telangana, India.  
E-mail: drarajesh1306@gmail.com



**Figure 1:** (a) MRI, T1W image showing hypointense lesion in the left frontal lobe. (b and c) showing peripheral enhancement on contrast administration



**Figure 2:** MR spectroscopy showing increased choline creatinine ratio and increased choline NAA ratio which is suggestive of glioma

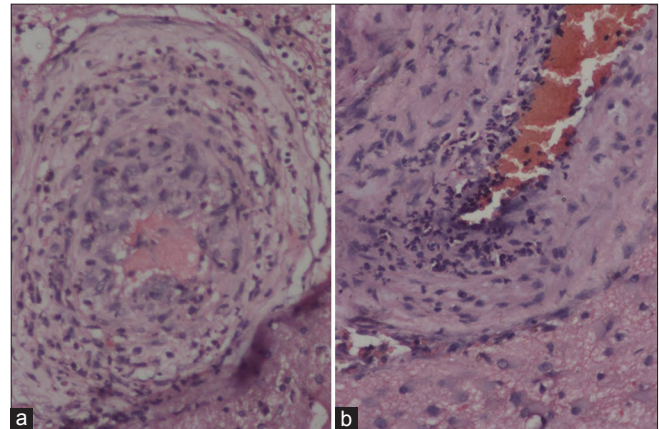
The biopsy showed brain with overlying meninges. There was perivascular and transmural infiltrate of lymphonuclear cells with focal perivascular granulomas involving small and medium-sized vessels. Infarction and focal haemorrhages in the adjacent brain parenchyma, along with gliosis were observed. The leptomeninges showed mild lymphomononuclear infiltrate. Stains for tuberculous bacilli and fungi were negative [Figure 3].

MR angiography done postoperatively showed focal narrowing of the vessels in the left frontal region, suggestive of vasculitis [Figure 4]. MR venogram was normal. Systemic evaluation for secondary vasculitis with erythrocyte sedimentation rate (ESR), cANCA, pANCA, retroviral assays, fungal and bacterial blood cultures were negative. Bilateral carotid Doppler showed no significant hemodynamic abnormality.

Monotherapy with steroids was initiated immediately after establishing the diagnosis with intravenous prednisolone 1000 mg/day for 3 days, 500 mg/day for 3 days, 250 mg/day for 3 days, 125 mg/day for 3 days, followed by oral prednisolone 60 mg/day. Six weeks after surgery, the patient's neurological symptoms gradually improved and there was no relapse of symptoms at 18 months follow-up.

## Discussion

IACNS/PACNS is a rare form of angitis limited to the central nervous system. PACNS currently is a diagnosis of exclusion,



**Figure 3:** The vessels showing perivascular infiltrate of lymphocytes and neutrophils causing wall destruction. H and E, ×100

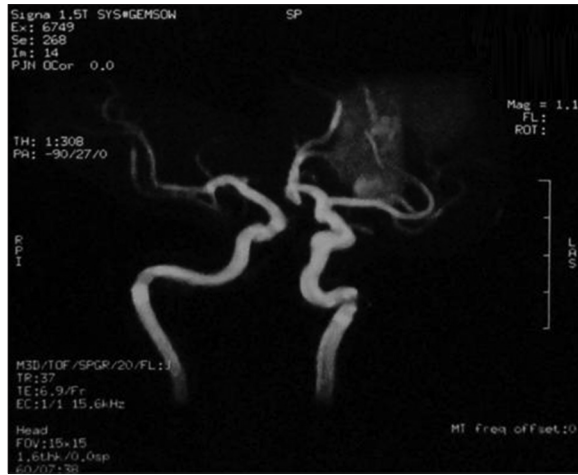due to nonspecific symptoms and signs. There are no readily available non-invasive diagnostic tests.

Calabrese and Mallek<sup>[3]</sup> proposed diagnostic criteria for IACNS, which include the following:

1. Unexplained neurologic deficit after thorough clinical and laboratory evaluation;
2. arteritic process demonstrated by cerebral angiogram and/or histopathologic examination in CNS; and
3. absent evidence of systemic vasculitis.

Clinical onset of IACNS is usually subacute, but it can have acute onset with rapid progression within a few days or weeks. The most frequent clinical manifestations at presentation are headache, altered cognition, hemiparesis, or persistent neurological deficit or stroke.<sup>[1]</sup> First presentation as a subarachnoid hemorrhage has been reported too.<sup>[4]</sup> Less common complaints are aphasia, transient ischemic attack, ataxia, dysphasia, nausea or vomiting, loss of memory, seizure, or a psychiatric disorder.<sup>[5]</sup> Duna *et al.* have described the occurrence of mass-like presentation of PACNS in about 15% of their cases (25 of 168) with predominantly focal symptoms (84%), followed by headaches (64%), altered sensorium, and cognitive decline (56%).<sup>[6]</sup>

MRI findings are highly variable and nonspecific, ranging from multiple irregular white matter changes to intracerebral



**Figure 4:** MR angiography in the postoperative period shows focal narrowing of vessels in the left frontal region, indicating vasculitis

haemorrhages, with sensitivity ranging from 50% to 100% and with a 100% specificity in biopsy-proven cases.<sup>[7]</sup> You *et al.* had described ill-defined lesion with disproportionate edema, striped hemorrhages, along with abnormal enhancement of adjacent vessel.<sup>[8]</sup> Panchal *et al.* described marked elevation of glutamine and glutamate peaks as a marker of inflammatory pathology in the CNS on MR spectroscopy (MRS), along with markedly elevated lipid and *N*-Acetyl-Aspartate (NAA) peaks and absent lactate peaks, differentiating them from aggressive neoplasms.<sup>[9]</sup> Their reported case had normal choline/creatinine ratio, indicating against a neoplastic etiology. Xiao *et al.* reported elevated choline/creatinine ratio and reduced NAA peaks in their case similar to the present case, indicating towards a neoplastic etiology.<sup>[10]</sup> There was a peak noted at around 2 ppm, which could be attributed to glutamine/glutamate, which is more commonly seen in inflammatory pathologies than aggressive neoplastic lesions. Role of diffusion-weighted MR imaging has been described for detection of lesions, which shows hyperintense lesions with heterogeneous average diffusion coefficient (ADC) values suggestive of coexistence of cytotoxic and vasogenic edema.<sup>[11,12]</sup>

Cerebral angiography, once considered as a gold standard, is not without pitfalls, with a sensitivity between 27% and 90% and a false-negativity rate of 30-40%.<sup>[1,3,13-15]</sup> Brain and meningeal biopsy, though gold standard for the diagnosis, is positive only in 66-75% cases due to focality of the disease.<sup>[16]</sup> The preferred site for the brain and meningeal biopsy is the temporal lobe of non-dominant side in areas with longitudinally arranged surface vessels.<sup>[17]</sup>

Treatment regimens for cerebral vasculitis include induction with high-dose steroids (methylprednisolone), coupled with or without cyclophosphamide. Maintenance therapy includes low-dose steroids/pulsed cyclophosphamide/methotrexate.

In the present case, we were able to achieve and maintain remission with steroids alone.

## Conclusion

Isolated central nervous system vasculitis still poses a challenge for diagnosis and treatment. MRS showing a glutamine peak seems to be a promising sign requiring further evaluation.

## Financial support and sponsorship

Nil.

## Conflicts of interest

There are no conflicts of interest.

## References

1. Salvarani C, Brown RD Jr, Calamia KT, Christianson TJ, Weigand SD, Miller DV, *et al.* Primary central nervous system vasculitis: Analysis of 101 patients. *Ann Neurol* 2007;62:442-51.
2. MacLaren K, Gillespie J, Shrestha S, Neary D, Ballardie FW. Primary angitis of the central nervous system: Emerging variants. *Q J Med* 2005;98:643-54.
3. Calabrese LH, Mallek JA. Primary angitis of the central nervous system. Report of 8 new cases, review of the literature, and proposal for diagnostic criteria. *Medicine* 1988;67:20-39.
4. Kumar R, Wijedicks EF, Brown RD Jr, Parisi JE, Hammond CA. Isolated angitis of the CNS presenting as subarachnoid haemorrhage. *J Neurol Neurosurg Psychiatry* 1997;62:649-51.
5. Hocaoglu C, Tan M. Isolated angitis of the central nervous system: A case presented with atypical psychiatric symptoms. *Prog Neuropsychopharmacol Biol Psychiatry* 2005;29:627-31.
6. Duna GF, George T, Rybicki L, Calabrese LH. Primary angitis of the central nervous system; an analysis of unusual presentation. *Arthritis Rheum* 1995;38:S340-S1122.
7. Siva A. Vasculitis of the nervous system. *J Neurol* 2001;248:451-68.
8. You G, Yan W, Zhang W, Shaowu L, Guilin L, Jiang T. Isolated angitis of central nervous system with tumor-like lesion, mimicking brain malignant glioma: A case report and review of the literature. *World J Surg Oncol* 2011;9:97.
9. Panchal NJ, Niku S, Imbesi SG. Lymphocytic vasculitis mimicking aggressive multifocal cerebral neoplasm: MR imaging and MR spectroscopic appearance. *AJNR Am J Neuroradiol* 2005;26:642-5.
10. Xiao-lin YU, Ai-fen LIU, Lin MA, Chun-zhu YAN, Yu-ying ZHAO, Pei-yan SHAN. Primary angitis of the central nervous system: A case report. *Chin Med J* 2011;124: 2782-5.
11. Moritani T, Hiwatashi A, Shrier DA, Wang HZ, Numaguchi Y, Westesson PL. CNS vasculitis and vasculopathy: Efficacy and usefulness of diffusion-weighted echo planar MR imaging. *Clin Imaging* 2004;28:261-70.
12. Lee SY, Chu K, Park KI, Jeong SW, Yoon BW. Diffusion-weighted MR findings in isolated angitis of the central nervous system (IACNS). *Acta Neurol Scand* 2003;108:346-51.
13. Duna G, Calabrese L. Limitations in the diagnostic modalities in the diagnosis of primary angitis of the central nervous system (PACNS). *J Rheumatol* 1995; 22:662-669.
14. Chu CT, Gray L, Goldstein LB, Hulette CM. Diagnosis of intracranial vasculitis: A multi-disciplinary approach. *J Neuropathol Exp Neurol* 1998; 57:30-38.
15. Alrawi A, Trobe JD, Blaivas M, Musch DC. Brain biopsy in primary angitis of the central nervous system. *Neurology* 1999; 53: 858-60.
16. Calabrese LH, Duna GF, Lie JT. Vasculitis in the central nervous system. *Arthritis Rheum* 1997;40:1189-1201.
17. Moore PM. Diagnosis and management of isolated angitis of the central nervous system. *Neurology* 1989; 39:167-73.