

# Trans aqueductal, third ventricle – Cervical subarachnoid stenting: An adjuvant cerebro spinal fluid diversion procedure in midline posterior fossa tumors with hydrocephalus: The technical note and case series

Ramesh Teegala

Department of Neurosurgery, Alluri Sita Ramaraju Academy of Medical Sciences Hospital, Eluru, West Godavari, Andhra Pradesh, India

## ABSTRACT

**Background:** Persistent or progressive hydrocephalus is one of the complex problems of posterior fossa tumors associated with hydrocephalus. The author evaluated the effectiveness of single-stage tumor decompression associated with a stent technique (trans aqueductal third ventricle – Cervical subarachnoid stenting) as an adjuvant cerebro spinal fluid (CSF) diversion procedure in controlling the midline posterior fossa tumors with hydrocephalus.

**Materials and Methods:** Prospective clinical case series of 15 patients was evaluated from July 2006 to April 2012. Fifteen clinico-radiological diagnosed cases of midline posterior fossa tumors with hydrocephalus were included in this study. All the tumors were approached through the cerebello medullary (telo velo tonsilar) fissure technique. Following the excision of the posterior fossa tumor, a sizable stent was placed across the aqueduct from the third ventricle to the cervical subarachnoid space.

**Results:** There were nine male and six female patients with an average age of 23 years. Complete tumor excision could be achieved in 12 patients and subtotal excision with clearance of aqueduct in remaining three patients. Hydrocephalus was controlled effectively in all the patients. There were no stent-related complications.

**Conclusions:** This study showed the reliability of single-stage tumor excision followed by placement of aqueductal stent. The success rate of this technique is comparable to those of conventional CSF diversion procedures. This is a simple, safe, and effective procedure for the management of persistent and or progressive hydrocephalus. This technique may be very useful in situations where the patient's follow-up is compromised and the patients who are from a poor economic background. Long-term results need further evaluation to assess the overall functioning of this stent technique.

**Key words:** Aqueductal stent, cerebello medullary fissure approach, hydrocephalus, posterior fossa tumor

## Introduction

The management of hydrocephalus associated with the posterior fossa tumors is always a difficult problem. There

are no uniform consensuses regarding the management strategies.<sup>[1-3]</sup> Approximately 70-94% of patients with posterior fossa tumors have hydrocephalus on presentation.<sup>[4-7]</sup> Persistent and/or progressive hydrocephalus occur in 10-62% of cases despite effective primary tumor decompression.<sup>[8-11]</sup> Two accepted modalities of treatment of this hydrocephalus are ventriculo-peritoneal shunt (VPS) or endoscopic third ventriculostomy (ETV).<sup>[7,12-14]</sup> The main debate is on the timing of the management of hydrocephalus. Treatment of this hydrocephalus is invariably associated with few pros and cons irrespective of the timing of the cerebro spinal fluid (CSF) diversion procedure.<sup>[8,15,16]</sup>

To manage these cases effectively in a single stage, the author placed a stent (ventricular catheter of VP shunt system) in a retrograde fashion into the 3<sup>rd</sup> ventricle across the aqueduct to the cervical subarachnoid space following primary tumor

Access this article online	
Quick Response Code:	Website: www.asianjns.org
	DOI: 10.4103/1793-5482.145369

### Address for correspondence:

Prof. Ramesh Teegala, Department of Neurosurgery, Alluri Sita Ramaraju Academy of Medical Sciences Hospital, Eluru, West Godavari - 534 004, Andhra Pradesh, India.  
E-mail: teegalar@gmail.com

surgery [Figure 1]. The author discussed the technical details and rationale of this procedure.

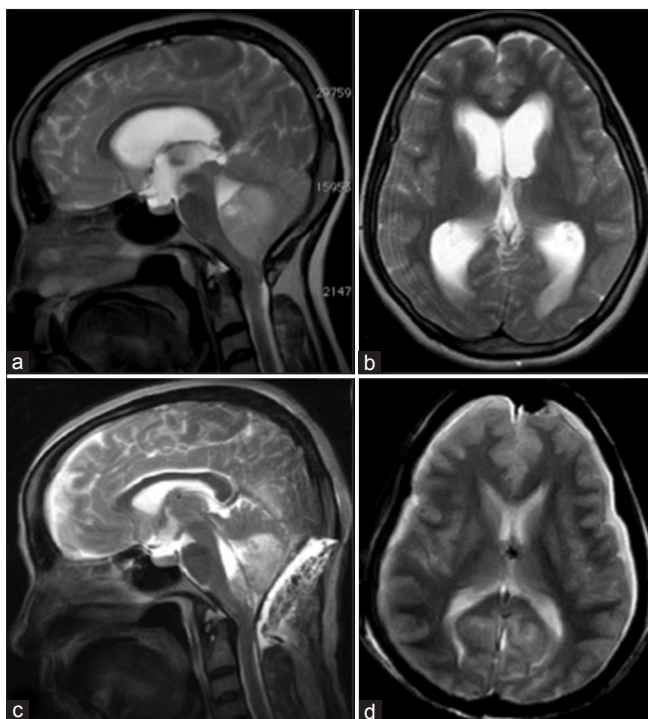
## Materials and Methods

Fifteen clinicoradiologically diagnosed cases of midline posterior fossa tumors with hydrocephalus from July 2006 to April 2012 were included in this study. Out of these 15 cases, The Author had operated initially on two patients at the Amrita Institute of Medical Sciences (AIMS), Kochi, Kerala, INDIA and remaining 13 patients at the Alluri Sita Ramaraju Academy of Medical Sciences (ASRAM) Hospital, Eluru, Andhra Pradesh, India. Magnetic resonance imaging (MRI) of the brain was performed in all patients before the planned surgery.

## Surgical Technique

### Stage 1

The author operated upon all patients in the prone position with Sugita head frame. Midline sub-occipital craniotomy was done in nine cases and craniectomy in the remaining six cases. Following the dural opening, cerebello medullary fissure was opened widely<sup>[6,17,18]</sup> to expose the tumor with the help of a self-retaining retractor. Safe and maximal tumor decompression along with the clearance of aqueductal block was the main aim of stage I surgery.



**Figure 1:** (a and b) Pre-operative T2W sagittal and axial MRI of brain showing large intra fourth ventricular tumor causing gross hydrocephalus; (c and d) Post-operative T2W sagittal and axial MRI showing the stent in place and well decompressed ventricles

### Stage 2

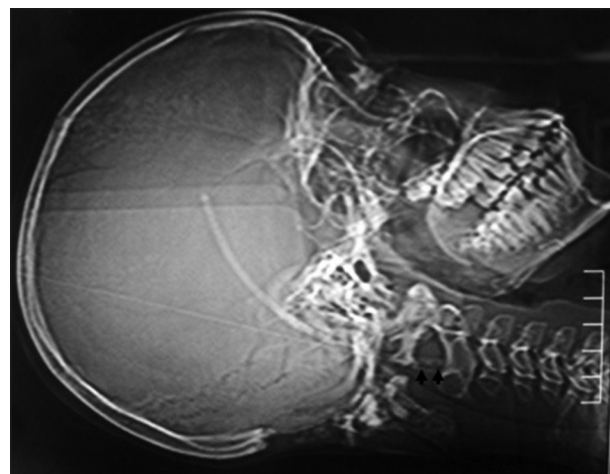
After complete hemostasis, the ventric end of the stent (7-10cm length of ventricular catheter, Chhabra VP Shunt, Surgiwear, India) was guided into the third ventricle. Third ventricular cavity was irrigated well to drain out the collected blood. The other end of the catheter tip with multiple new side holes was negotiated down to the level of C2 in the subarachnoid space. Finally, the lower end of the stent was fixed to the inner surface of theca at the level of C1-2 with 4-0 Mersilk [Figures 1-3]. The dura was closed primarily in all cases.

## Results and Observations

Among the 15 patients, there were nine male and six female patients with a mean age of 23 years (range 4-55 years). Complete tumor excision was achieved in twelve patients and near total excision with clearance of aqueductal opening in

**Table 1: Summary of the operated patients**

Patient no.	Age	Sex	Diagnosis	Excision
1	12	F	Fourth ventricular ependymoma	Complete
2	8	M	Medulloblastoma	Complete
3	5	M	Focal exophytic brain stem glioma	Near total
4	4	F	Brain stem epidermoid	Complete
5	52	F	Vermian astrocytoma	Complete
6	12	M	Medulloblastoma	Complete
7	10	M	Ependymoma	Near total
8	16	M	Ependymoma	Complete
9	55	M	Metastasis from bronchogenic carcinoma	Complete
10	4	M	Ependymoma	Near total
11	48	F	Medulloblastoma	Complete
12	55	F	Metastasis from carcinoma breast	Complete
13	44	F	Multiple metastasis	Complete
14	21	M	Fourth ventricular ependymoma	Complete
15	12	M	Medulloblastoma	Complete



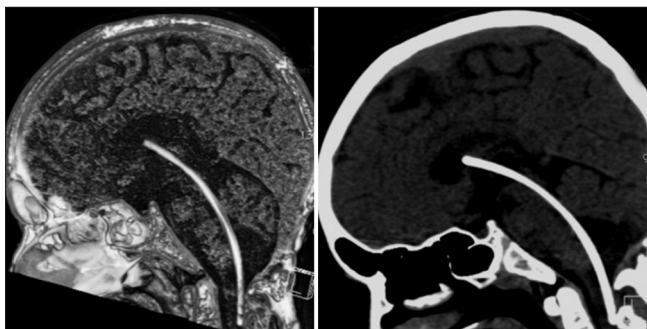
**Figure 2:** Topographic image of the computer tomogram showing the sub occipital craniectomy and the stent extending from third ventricular area to the level of second cervical spinal level (arrows showing lower end with multiple side holes)

remaining three patients. Stent was placed successfully in all 15 patients [Table 1]. All the patients showed effective control of hydrocephalus with stent well in place [Figure 1]. One child developed pseudomeningocele at the time of suture removal. One-time lumbar puncture and drainage of CSF was required to clear that. Other than that, there were no procedure-related complications in this study. All patients, except a case of brainstem epidermoid tumor were referred to the oncologist for adjuvant treatment. Postoperative follow-up period ranged 4-40 months (average 15 months).

## Discussion

One of the common presentations of posterior fossa tumor is hydrocephalus. Nearly 70-90% of all posterior fossa tumors are associated with hydrocephalus on initial presentation<sup>[1,4,5,7,12,15-17,19]</sup> and 4% develop progressive hydrocephalus following primary tumor surgery even after complete removal of tumor.<sup>[10,11,13,14]</sup> Until date, the main management of this hydrocephalus has been surgeon's choice whether to treat it before primary tumor surgery or to follow the case.<sup>[11]</sup> Treating the hydrocephalus before the primary tumor surgery may be associated with easier dural opening, smoother operative conditions, reduced post-op CSF leak or development of pseudomeningocele. Overall morbidity associated with the raised features of hydrocephalus was reduced with this protocol.<sup>[9]</sup> Whereas complications related to this primary CSF diversion includes chances of tumor bleed and reverse herniation.<sup>[14]</sup>

In cases where the CSF diversion follows the primary surgery, the overall success rates of ETV or VPS is about 70% only.<sup>[7,8,14]</sup> In both the conditions, the shunt diversion procedure is always a second one and each one of them has its own complications.<sup>[7,8,14]</sup> Sainte-Rose *et al.*<sup>[14]</sup> reported that, when ETV has preceded the tumor resection, the incidence of postoperative hydrocephalus reduces from 27% to 6%. The incidence of persistent or progressive hydrocephalus without pre-operative CSF diversion is about 10-62%.<sup>[8,14]</sup> To overcome few of these complications and the uncertainty prevailing over the timing of CSF diversion, the author applied



**Figure 3:** 3D computed tomography with coronal reconstructed images showing the stent extending from third ventricle to the cervical subarachnoid space and its relations following the tumor removal

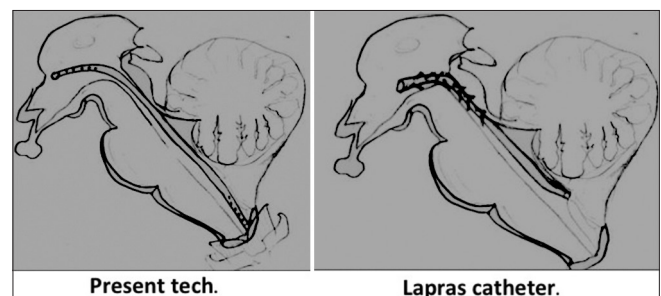
single-stage technique of tumor decompression followed by stent technique. Most of the patients treated were from poor economic background and many times their follow-up is also compromised. Hence this single-stage technique was adapted to reduce the extra burden of repeat surgeries in patients with persistent or progressive hydrocephalus.

The author opines that, combining both the procedures into a single stage has the advantage of reducing the incidence of progressive hydrocephalus, CSF leak, and pseudomeningocele formation. Like ETV, stent also drains the CSF in to the basal subarachnoid spaces. Thus, will not have complications like CSF over or under drainage. In cases where the complete tumor was excised, the aim of stent was to control the persistent or progressive hydrocephalus.<sup>[8,14]</sup> Other use of the stent is to control the obstructive hydrocephalus secondary to tumor recurrence.

Recently, Pitskhelauri *et al.*<sup>[20]</sup> described the direct stent techniques in the deep-seated midline brain stem tumors. They highlighted the importance of these techniques in controlling the hydrocephalus and merging two or three different surgical procedures into a single-stage surgery. In the author's view, these simple techniques, when selected properly, could help in controlling the hydrocephalus as well as reducing the multiple surgery-related burden to the patient.

In 1975, for the first time, Lapras<sup>[21]</sup> described a similar procedure for patients with Arnold Chiari malformations with syrinx [Figure 4]. He placed a stent across the aqueduct connecting the third and fourth ventricle. He also advised regular lumbar punctures for better functioning of the stent. In this series, only one child required single lumbar drainage to control the pseudomeningocele. Routine lumbar drainage was not done as the stent will function with the regular pulsatile forces of the brain and CSF flow dynamics.<sup>[20]</sup> Pseudomeningocele might have developed due to the temporary blockade of the stent by blood and blood products. To avoid this complication, it is important to achieve complete hemostasis before placing the shunt and irrigate the ventricular cavity through the stent before the dural closure.

In this series of 15 cases, there were no stent-related complications like malfunction, stent migration and neural



**Figure 4:** Illustrated diagram showing the catheter placement and its comparison with the Lapras catheter technique



complications like third nerve palsy and parinaud syndrome. Unlike the other techniques, the author fixed the lower end of the stent to the undersurface of dura in order to prevent the migration. Brain stem complications following placement of aqueductal stents were reported by many authors.<sup>[22,23]</sup> In this series, as the aqueduct was dilated due to obstructive hydrocephalus, stent placement was easy under direct vision. Hence, the author did not encounter complications related to tube pressure on the tectal plate across the aqueduct. The author observed that the overall incidence of post-operative CSF leak and pseudomeningocele formation is less with this stent technique. The follow-up period ranged between 4 months and 40 months.

Successful retrograde 3<sup>rd</sup> ventriculo peritoneal/3<sup>rd</sup> ventriculo atrial shunt through the aqueduct was previously described by Goel and Pandya<sup>[22]</sup> to control the complicated CSF leaks which were uncontrolled with conventional measures. They described an effective placement of shunt from third ventricle to atrium (ventriculo atrial shunt) in a postoperative case of bifrontal meningioma with persistent CSF leak from the cranial wound. In another two cases of postoperative spinal dysraphism with CSF leak, they placed the shunt from third ventricle to peritoneal (3<sup>rd</sup> VPS) cavity. They achieved effective control of CSF leak. In their study, third nerve palsy was noted in one patient. This might have been attributable to the passage of shunt tube through the non-dilated aqueduct.

Though our stent technique is simple, it has a potential risk of blockade and stent-related infections like other shunt devices. If patient tends to develop hydrocephalus due to stent block, one can consider other CSF diversion methods like VPS or ETV without disturbing the stent. Uncontrolled infection may warrant the stent removal. However, there is a risk of infection for any kind of surgical procedure and one has to be meticulous and take appropriate precautions to prevent infection. Fortunately, there were no such complications of stent malfunction or infection in this series, which require stent manipulation. Usually, the problem of persistent or progressive hydrocephalus is common in the initial 30 days following the surgery. Hence it is essential for the stent to remain patent for a period of nearly 30 days for CSF to attain its natural flow dynamics.<sup>[20]</sup> In those patients who develop tumor recurrence, the stent helps in controlling the secondary obstructive hydrocephalus. In this series, similar benefit was observed in a case of cerebellar astrocytoma which recurred after 22 months of primary surgery and radiotherapy. Despite the tumor recurrence, the stent was patent.

There has always been a speculation regarding the tumor cells disseminating through the shunt systems.<sup>[24]</sup> Most of these disseminations were reported with VPS to the peritoneal cavity. In this technique, there is no problem of migration to

the peritoneal cavity and the stent is only bypassing the tumor bed from third ventricle to the cervical subarachnoid space.

Hence, it is a safe and an effective adjuvant CSF diversion technique. The long-term results of this technique need further evaluation with a controlled group.

## Conclusion

Midline posterior fossa related hydrocephalus is a common problem without accepted consensus regarding the treatment modalities of hydrocephalus. This study showed the reliability of single stage-tumor excision followed by placement of trans-aqueductal, third ventricle-cervical subarachnoid stent. These simple techniques may reduce the burden of repeat surgeries for progressive hydrocephalus in poor patients. Success rates of these stents are comparable to those of conventional CSF diversion procedures. This is a simple, safe, and effective procedure for the management of persistent/progressive hydrocephalus. Long-term results need further evaluation to assess the overall functioning of this stent technique.

## Acknowledgments

I sincerely thank Dr. Madhavi Latha and Dr. Sai Kiran for their help in editing this manuscript.

## References

1. Culley DJ, Berger MS, Shaw D, Geyer R. An analysis of factors determining the need for ventriculoperitoneal shunts after posterior fossa tumor surgery in children. *Neurosurgery* 1994;34:402-8.
2. Cinalli G, Sainte-Rose C, Chumas P, Zerah M, Brunelle F, Lot G, *et al.* Failure of third ventriculostomy in the treatment of aqueductal stenosis in children. *J Neurosurg* 1999;90:448-54.
3. Cinalli G, Salazar C, Mallucci C, Yada JZ, Zerah M, Sainte-Rose C. The role of endoscopic third ventriculostomy in the management of shunt malfunction. *Neurosurgery* 1998;43:1323-9.
4. Dias MS, Albright AL. Management of hydrocephalus complicating childhood posterior fossa tumors. *Pediatr Neurosci* 1989;15:283-90.
5. Due-Tønnessen BJ, Helseth E. Management of hydrocephalus in children with posterior fossa tumors: Role of tumor surgery. *Pediatr Neurosurg* 2007;43:92-6.
6. Mussi AC, Rhoton AL Jr. Telovelar approach to the fourth ventricle: Microsurgical anatomy. *J Neurosurg* 2000;92:812-23.
7. Raimondi AJ, Tomita T. Hydrocephalus and infratentorial tumors. Incidence, clinical picture, and treatment. *J Neurosurg* 1981;55:174-82.
8. Morelli D, Pirotte B, Lubansu A, Detemmerman D, Aeby A, Fricx C, *et al.* Persistent hydrocephalus after early surgical management of posterior fossa tumors in children: Is routine preoperative endoscopic third ventriculostomy justified? *J Neurosurg* 2005;103:247-52.
9. Santamarta D, Blázquez JA, Maillou A, Muñoz A, Caballero M, Morales F. Analysis of cerebrospinal fluid related complications (hydrocephalus, fistula, pseudomeningocele and infection) following surgery for posterior fossa tumors. *Neurocirugia (Astur)* 2003; 14:117-26.
10. Santos de Oliveira R, Barros Jucá CE, Valera ET, Machado HR. Hydrocephalus in posterior fossa tumors in children. Are there factors that determine a need for permanent cerebrospinal fluid diversion? *Childs Nerv Syst* 2008;24:1397-403.
11. Schijman E, Peter JC, Rekaté HL, Sgouros S, Wong TT. Management of hydrocephalus in posterior fossa tumors: How, what, when? *Childs Nerv Syst* 2004;20:192-4.

12. Kumar V, Phipps K, Harkness W, Hayward RD. Ventriculo-peritoneal shunt requirement in children with posterior fossa tumours: An 11-year audit. *Br J Neurosurg* 1996;10:467-70.
13. Kombogiorgas D, Sgouros S, Walsh AR, Hockley AD, Stevens M, Grundy R, *et al.* Outcome of children with posterior fossa medulloblastoma: A single institution experience over the decade 1994-2003. *Childs Nerv Syst* 2007;23:399-405.
14. Sainte-Rose C, Cinalli G, Roux FE, Maixner R, Chumas PD, Mansour M, *et al.* Management of hydrocephalus in pediatric patients with posterior fossa tumors: The role of endoscopic third ventriculostomy. *J Neurosurg* 2001;95:791-7.
15. Epstein F, Murali R. Pediatric posterior fossa tumors: Hazards of the preoperative shunt. *Neurosurgery* 1978;3:348-50.
16. Kombogiorgas D, Natarajan K, Sgouros S. Predictive value of preoperative ventricular volume on the need for permanent hydrocephalus treatment immediately after resection of posterior fossa medulloblastomas in children. *J Neurosurg Pediatr* 2008;1:451-5.
17. Kellogg JX, Piatt JH Jr. Resection of fourth ventricle tumors without splitting the vermis: The cerebellomedullary fissure approach. *Pediatr Neurosurg* 1997;27:28-33.
18. Rajesh BJ, Rao BR, Menon G, Abraham M, Easwer HV, Nair S. Telovelar approach: Technical issues for large fourth ventricle tumors. *Childs Nerv Syst* 2007;23:555-8.
19. Matsumoto J, Kochi M, Morioka M, Nakamura H, Makino K, Hamada J, *et al.* A long-term ventricular drainage for patients with germ cell tumors or medulloblastoma. *Surg Neurol* 2006;65:74-80.
20. Pitskhelauri DI, Kononov AN, Kornienko VN, Serova NK, Arutiunov NV, Kopachev DN. Intraoperative direct third ventriculostomy and aqueductal stenting in deep-seated midline brain tumor surgery. *Neurosurgery* 2009;64:256-67.
21. Lapras C, Poirier N, Deruty R, Bret P, Jyeux O. Catheterization of the sylvian aqueduct. Its present role in the surgical treatment of sylvian aqueduct stenosis of PCF tumors, and of syringomyelia. *Neurochirurgie* 1975;21:101-9.
22. Goel A, Pandya SK. A shunting procedure for cerebrospinal fluid fistula, employing cannulation of the third and fourth ventricles. *Br J Neurosurg* 1993;7:299-302.
23. Sagan LM, Kojder I, Poncyjusz W. Endoscopic aqueductal stent placement for the treatment of a trapped fourth ventricle. *J Neurosurg* 2006;105:275-80.
24. Back MR, Hu B, Rutgers J, French S, Moore TC. Metastasis of an intracranial germinoma through a ventriculoperitoneal shunt: Recurrence as a yolk-sac tumor. *Pediatr Surg Int* 1997;12:24-7.

**How to cite this article:** Teegala R. Trans aqueductal, third ventricle – Cervical subarachnoid stenting: An adjuvant cerebrospinal fluid diversion procedure in midline posterior fossa tumors with hydrocephalus: The technical note and case series. *Asian J Neurosurg* 2016;11:268-72.

**Source of Support:** Nil, **Conflict of Interest:** None declared.