

CASE REPORT

Neurosarcoidosis presenting as an incidental solitary cranial ring-enhancing lesion

Michael Thambuswamy, Ashish H. Shah, Mai Tran, Joanne T. Thambuswamy², Amade Bregy, Michael D. Norenberg¹, Ricardo J. Komotar

Departments of Neurological Surgery and ¹Pathology, University of Miami, Miami, FL, ²Department of Neurological Surgery, Texas Tech University Health Science Center, TX, USA

ABSTRACT

Isolated neurosarcoidosis without prior systemic symptoms is extremely rare, occurring in approximately 2% of patients with neurosarcoidosis. Due to its rarity, mistakes in diagnosis and treatment occur commonly. We present a case of a 47-year-old female who was found to have an incidentally discovered solitary intracranial lesion that mimicked a high-grade neoplasm, but was later confirmed to be neurosarcoidosis. Incidental solitary neurosarcoid granulomas are difficult to diagnose due to its nonspecific clinical and imaging presentations. Early diagnosis by biopsy in these rare incidental cases remains paramount for adequate treatment.

Key words: Incidental, intracranial, neurosarcoidosis, solitary lesion

Introduction

Sarcoidosis is an inflammatory disease of unknown etiology that usually manifests with systemic symptoms in the lungs, skin, and eyes. Approximately, 5-16% of patients with sarcoidosis may have central nervous system (CNS) involvement, termed neurosarcoidosis. Neurosarcoidosis may present variably depending on the degree of CNS involvement, ranging from cranial nerve palsies, hydrocephalus, diabetes insipidus, and rarely myelopathy.^[1-4]

Previous studies suggest that the incidence of isolated neurosarcoidosis without prior systemic symptoms is extremely rare occurring in approximately 2% of patients.^[5] Due to the rarity of isolated neurosarcoidosis, clinicians may often misdiagnose and mistreat these patients. We report a patient with an isolated brain lesion as the only manifestation of sarcoidosis. Although the presentation of sarcoidosis as an isolated lesion is rare, it is important to include this entity in

the differential diagnosis of an enhancing brain lesion, as there are significant differences in treatment modalities.

Case Report

A previously healthy 47-year-old female presented to an outside physician because worsening memory and recall. Due to the atypical nature of the complaints, a magnetic resonance imaging (MRI) was ordered, which revealed an incidental ring-enhancing lesion adjacent to the atrium of the left lateral ventricle [Figure 1]. At an outside hospital, routine blood tests and an infectious disease evaluation were performed, which were negative. Therefore, the patient was referred to our clinic for evaluation for a suspected high-grade neoplasm. The patient's past medical and surgical history were noncontributory. Physical examination revealed no focal neurological deficits at presentation.

Due to the suspicion of a high-grade glioma, the patient underwent a left parietal stereotactic needle biopsy with an option for an open resection based on findings of frozen section histopathology. Intraoperatively, the frozen section histopathology revealed nongliomatous inflammatory process suggestive of lymphoma or infectious etiology. No further resection was performed. The final pathology results revealed a noncaseating granulomatous inflammatory process, most consistent with neurosarcoidosis [Figure 2]. From a neurosurgical standpoint, the patient was doing well and was discharged on prednisone. The patient was then referred to a pulmonologist for a systemic workup for sarcoidosis. Patient was doing well with no neurological deficits at 6-month follow-up.

Access this article online

Quick Response Code:



Website:

www.asianjns.org

DOI:

10.4103/1793-5482.146389

Address for correspondence:

Dr. Ricardo J. Komotar, Director of Surgical Neurooncology, Department of Neurological Surgery, University of Miami, School of Medicine Miami, Florida, USA.
 E-mail: rkomotar@med.miami.edu

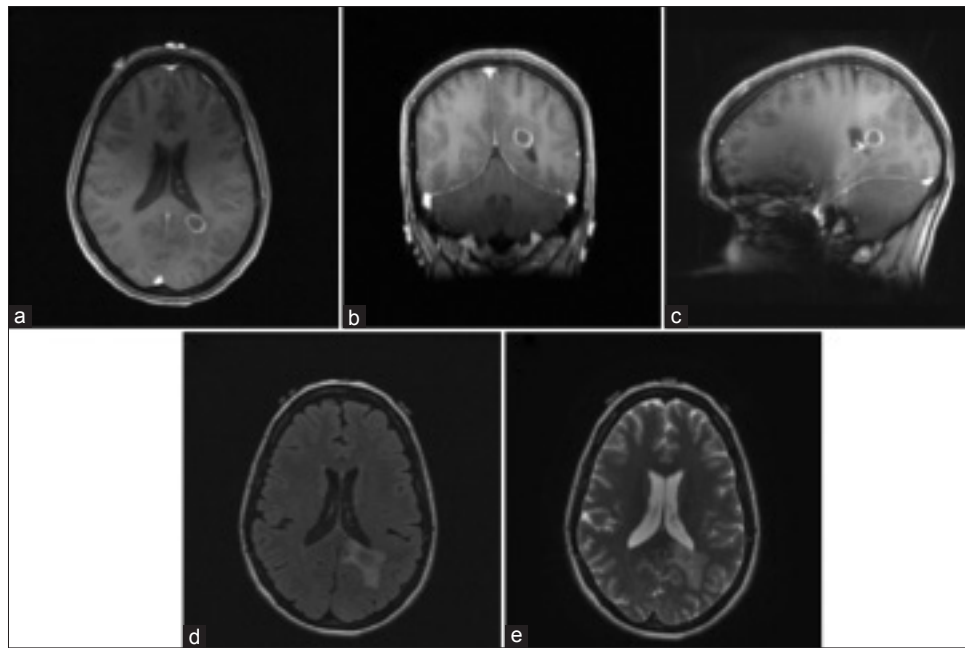


Figure 1: Magnetic resonance imaging of brain showing left parietal lesion. (a) Axial, (b) Coronal, (c) Sagittal T1-weighted images with gadolinium, (d) T2-weighted fluid attenuated inversion recovery axial without gadolinium, (e) T2-weighted axial without gadolinium

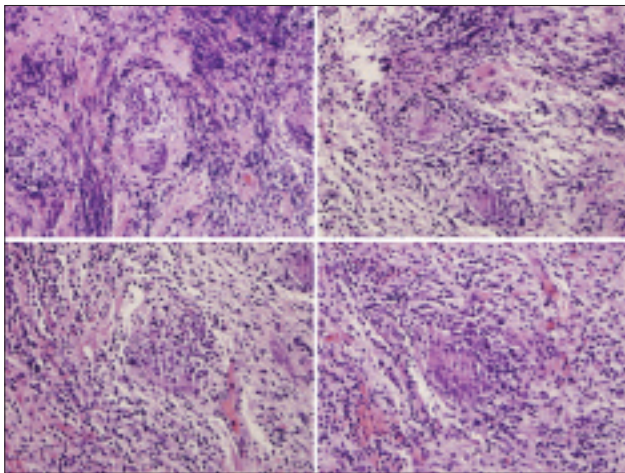


Figure 2: Permanent section of left parietal intraparenchymal lesion demonstrating an inflammatory process and noncaseating granulomas

Discussion

Sarcoidosis is a chronic inflammatory, granulomatous disease that typically presents with systemic symptoms, most commonly in the lungs. Other organs such as the skin, eyes, lymph nodes, secretory glands and muscles can also be affected with or without concomitant pulmonary involvement.^[1,6] Sarcoidosis is characterized by the presence of T lymphocytes, mononuclear phagocytes, and noncaseating epithelioid granulomas on histopathology.^[2]

The etiology of sarcoidosis is currently unknown; possible contributing factors in sarcoidosis include a hyperbolic cellular immune response and an increased sensitivity to environmental and genetic factors.^[1] Patients may present

with respiratory symptoms, general discomfort, skin disorders, nervous system abnormalities, and other systemic disorders or no symptoms at all. However, many affected patients are not seriously ill and the overall mortality rate from sarcoidosis is <5%.^[1] Neurosarcoidosis is rare and occurs in approximately 5% of patients. Clinical findings in neurosarcoidosis most frequently include cranial nerves in >50% of patients, especially the facial and optic nerves.^[6] Other neurologic manifestations also include peripheral neuropathy, hypothalamic or pituitary dysfunction, or cognitive problems.^[3,4,7]

Diagnosis of neurosarcoidosis is confirmed by histopathology at the time of surgery; however, laboratory tests and imaging modalities may supplement the diagnosis. In patients with systemic findings, serum angiotensin converting enzyme (ACE) can be elevated. In particular, cerebrospinal fluid (CSF) in patients with neurosarcoidosis may demonstrate elevated lymphocytes and increased ACE with a negative culture.^[8] Imaging in these patients may vary depending on the degree of CNS involvement.

There have been very few cases reported in the literature where a single brain lesion is the sole manifestation of sarcoidosis. In 5-10% of patients with neurosarcoidosis, there is the presence of either solitary or intraparenchymal mass lesions, but it is much more common for these lesions to be multiple.^[9] Isolated neurosarcoidosis has been known to mimic a variety of conditions including gliomas.^[9,10] However, most of these patients typically present with neurological or systemic symptoms such as seizures, cranial nerve palsy or signs of increased intracranial pressure.^[1] In the absence of any clinical findings, solitary neurosarcoid granulomas are

difficult to diagnose due to its nonspecific clinical and imaging presentations.^[10]

In our particular case, the patient was incidentally found to have an intraparenchymal lesion consistent with a high-grade glioma. Because of negative laboratory tests, noncontributory family history, and a nonspecific chief complaint, clinical suspicion for neurosarcoidosis was low. Because our patient had no physical exam findings, a more conservative approach was preferred for this lesion. Because the biopsy revealed a nongliomatous inflammatory process, an aggressive surgical resection was avoided and medical management was optimized. Neurosarcoidosis is treated by immunosuppression with oral prednisone; in refractory cases, treatment can be enhanced with other immunosuppressive drugs such as cyclosporine or methotrexate.^[11] Because treatment paradigms for gliomas and neurosarcoidosis significantly differ, early diagnosis by biopsy in these rare incidental cases remains paramount. If clinical suspicion for neurosarcoidosis is warranted, lumbar puncture for elevated ACE and lymphocytes in CSF may aid in making a diagnosis. Our case remains unique in the literature as an incidental isolated case of neurosarcoidosis that mimicked a high-grade neoplasm on MRI.

Conclusion

Sarcoidosis is a systemic disease that rarely involves the CNS. When presenting with lesions in the brain, most patients exhibit focal symptomatology including cranial nerve palsies, neuropathies, or other sequelae. Our case was a rare example of a 47-year-old woman with no significant risk factors that presented with an incidental solitary intraparenchymal ring-enhancing lesion. The differential diagnosis for such lesions includes high-grade neoplasm, metastasis, infection, lymphoma, or inflammatory process. It is important to

recognize sarcoidosis as part of the differential diagnosis due to the significant differences in surgical and medical management.

References

1. Greenberg MS, editor. Handbook of Neurosurgery. 7th ed. New York: Thieme; 2010.
2. Motta M, Alongi F, Bolognesi A, Cozzarini C, Di Muzio N, Fazio F. Remission of refractory neurosarcoidosis treated with brain radiotherapy: A case report and a literature review. *Neurologist* 2008;14:120-4.
3. Pawate S, Moses H, Sriram S. Presentations and outcomes of neurosarcoidosis: A study of 54 cases. *QJM* 2009;102:449-60.
4. Titlic M, Bradic-Hammoud M, Miric L, Punda A. Clinical manifestations of neurosarcoidosis. *Bratisl Lek Listy* 2009;110:576-9.
5. Stern BJ, Krumholz A, Johns C, Scott P, Nissim J. Sarcoidosis and its neurological manifestations. *Arch Neurol* 1985;42:909-17.
6. Oksanen V. Neurosarcoidosis: Clinical presentations and course in 50 patients. *Acta Neurol Scand* 1986;73:283-90.
7. Tamagno G, Murialdo G. Amenorrhea-galactorrhea syndrome as an uncommon manifestation of isolated neurosarcoidosis. *Ann Ital Med Int* 2001;16:260-6.
8. Oksanen V. New cerebrospinal fluid, neurophysiological and neuroradiological examinations in the diagnosis and follow-up of neurosarcoidosis. *Sarcoidosis* 1987;4:105-10.
9. Uruha A, Koide R, Taniguchi M. Unusual presentation of sarcoidosis: Solitary intracranial mass lesion mimicking a glioma. *J Neuroimaging* 2011;21:e180-2.
10. Brinar VV, Habek M. Isolated central nervous system sarcoidosis: A great mimicker. *Clin Neurol Neurosurg* 2008;110:939-42.
11. Stern BJ, Schonfeld SA, Sewell C, Krumholz A, Scott P, Belendiuk G. The treatment of neurosarcoidosis with cyclosporine. *Arch Neurol* 1992;49:1065-72.

How to cite this article: Thambuswamy M, Shah AH, Tran M, Thambuswamy JT, Bregy A, Norenberg MD, *et al.* Neurosarcoidosis presenting as an incidental solitary cranial ring-enhancing lesion. *Asian J Neurosurg* 2017;12:544-6.

Source of Support: Nil, **Conflict of Interest:** None declared.