

CASE REPORT

L'hermitte–Duclos disease in an elderly patient: A case report and review of the literature

Ersin Ozeren, Levent Gurses, Mehmet Sorar, Uygur Er¹, Evrim Önder, Ata Türker Arıkök

Department of Neurosurgery, Diskapi Training and Research Hospital, ¹Department of Neurosurgery, Medical School, Duzce University, Duzce, Turkey

ABSTRACT

L'hermitte–Duclos disease (LDD) is an extremely rare cerebellar lesion of uncertain etiology. Occasionally, the patients with LDD may even have sudden neurological deterioration due to acute herniation as seen in the present case report. It is also imperative to distinguish this disease from other malignant lesion of the cerebellum and cerebellar malformations with its varied natural course of history and hence better ability to prognosticate such patients. Herein, we reported a successfully treated case of LDD following a long history of vaguely defined neurological complaints in an elderly patient and reviewed the literature.

Key words: Dysplastic cerebellar gangliocytoma, elderly, L'hermitte–Duclos disease, magnetic resonance imaging

Introduction

L'hermitte–Duclos disease (LDD) is an extremely rare cerebellar lesion of uncertain etiology.^[1] Since the original description, this entity has been known under a wide variety of names including dysplastic gangliocytoma of the cerebellum, purkinjeoma, ganglioneuroma, granular or granulomolecular hypertrophy of the cerebellum, diffuse hypertrophy of the cerebellar cortex, gangliomatosis of the cerebellum, hamartoma of the cerebellum, myelinated neurocytoma and gangliocytoma myelinicum diffusum.^[1] The pathogenesis and exact genetic alterations of this entity are unclear; it has been regarded as a developmental anomaly, a hamartoma, a manifestation of a phakomatosis and a neoplastic lesion.^[2,3]

Since the first description by L'hermitte and Duclos in 1920, more than 230 cases with LDD have been reported in the literature.^[4] They described a 36-year-old man with hearing loss, headaches, vomiting, dizziness and memory loss who developed “mental distress” and died in a coma. An autopsy revealed a circumscribed region of widened cerebellar folia

related to abnormal ganglion cells. Other cases with similar histological features were reported over the next several decades.

It is not only important for the neurosurgeon to be aware of this entity so as to differentiate from malignant lesions but also to distinguish it from other cerebellar malformations, which may be hypoplastic or dysplastic, focal or diffuse in nature, with brain stem and cerebral involvement, and varied natural course. Herein, we report a successfully treated case of LDD following a long history of vaguely defined neurological complaints in an elderly patient. Although there are previously reported cases, only one patient has previously been reported in the literature with posterior fossa mass causing obstructive hydrocephalus with cerebellar herniation and operated successfully.^[5]

Case Report

A 73-year-old woman presented with a 15-year history of gradual onset, progressively worsening tremor and unsteadiness that had caused frequent falls. She was diagnosed with benign positional tremor 4-year ago, but no further radiologic workup was performed. In recent times, nausea and vomiting worsened the patient's condition and she was admitted to the hospital for detailed examination. She had a medical history of total abdominal hysterectomy and bilateral salpingo-oophorectomy procedure.

On examination, the patient had right facial paralysis, dysmetria and dysdiadochokinesia of right extremities. The patient had also right sided intentional tremor and slight truncal ataxia. The contrast magnetic resonance imaging (MRI) revealed right cerebellar mass with striated pattern, causing

Access this article online

Quick Response Code:



Website:

www.asianjns.org

DOI:

10.4103/1793-5482.146666

Address for correspondence:

Prof. Uygur Er, Department of Neurosurgery, Medical School, Duzce University, Duzce, Turkey. E-mail: uygurer@gmail.com

mass effect on the brainstem and fourth ventricle [Figure 1]. “Tiger-stripped” appearance in this patient suggested the diagnostic possibility of LDD. MR spectroscopy was planned but the day after, patient lost consciousness and pupillary light reflex disappeared. Emergency computed tomography (CT) revealed herniation associated with periventricular edema and the patient was admitted to surgery. The lesion was surgically removed subtotaly. Histological examination confirmed the diagnosis of LDD [Figure 2a and b]. Postoperatively, the patient recovered well, and her symptoms regressed. Control CT scan revealed opening of the fourth ventricle. There was no indication of Cowden’s disease (CD).^[6] The patient is regularly followed-up in our outpatient clinic every 6 month. Her falls are not seen anymore. Her right sided tremor is getting decrease gradually. Right-sided dysdiadochokinesia and dysmetria are continuing moderately. Her right facial paralysis recovered completely. Total removal of the lesion is seen on postoperative T1-weighted MRI [Figure 3].

Discussion

L'hermitte–Duclos disease, or dysplastic gangliocytoma of the cerebellum, is a rare abnormality that often becomes clinically apparent in the third and fourth decade, but the age of manifestation varies from birth to the sixth decade. There appears to be no sex predilection.^[7] The patient presented here was 73-year-old female and a good candidate for being the oldest patient in the literature diagnosed with LDD and successfully treated.

Patients usually present with a longstanding history of vaguely defined neurological complaints.^[7] The duration of symptoms ranges from a few months to more than 10-year.^[8] Clinical symptoms and signs are mainly related to raised intracranial pressure and cerebellar dysfunction, such as headache, nausea and vomiting, gait ataxia, papilledema and cranial nerve palsies. The disease is typically unilateral, with a predilection for the left rather than the right cerebellar hemisphere. The process rarely extends to the vermis, and there is only one report of bilateral involvement.^[9] Our case presented with a 15-year history of gradual onset, progressively worsening tremor and unsteadiness and detailed radiological workup revealed LDD on the right side. Occasionally, the patients with LDD may even have sudden neurological deterioration due to acute herniation as seen in the present case report.

L'hermitte–Duclos disease is characterized by thickened and distorted cerebellar folia. The principal microscopic abnormalities are expansion of the internal granule cell layer with many abnormal neurons, thickening of the molecular cell layer, and absence of the Purkinje cell layer.^[7,9] The diagnosis of LDD is usually based on its characteristic CT and MRI appearance. The typical neuroimaging features of dysplastic gangliocytoma are as a result of the indolent growth reflecting

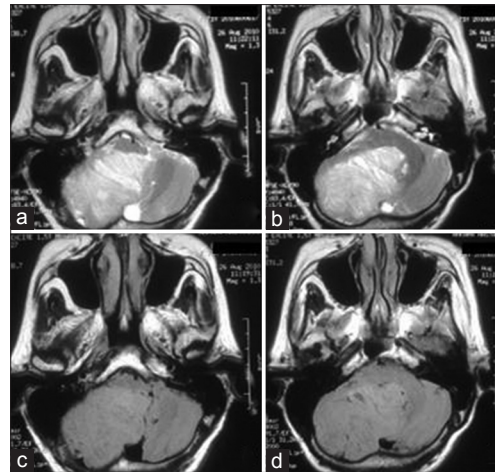


Figure 1: On T2 weighted axial sections, “tiger-stripped” appearance characterized by alternant hyper-, and isointense bands (a, b). On T1 weighted sections mildly hyperintense mass lesion completely occluding the fourth ventricle, and compressing the brain stem (c, d)

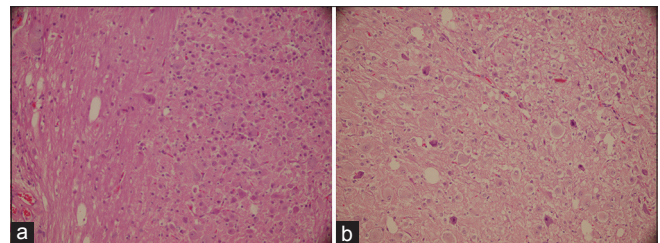


Figure 2: (a) The normal small neurons of cerebellar granular layer is almost entirely replaced by abnormal ganglion cells. (b) there is an enlargement of internal granular layer of cerebellum

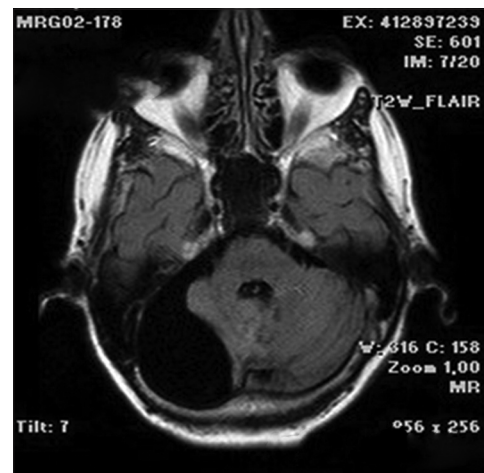

Figure 3: On postoperative T1-weighted magnetic resonance imaging shows total removal of the lesion

the generally benign biological behavior of these lesions. MRI usually reveals a characteristic striated pattern with enlargement of the cerebellar folia.^[7,10] The LDD lesions may be partially calcified and show a very mild or no enhancement following administration of gadolinium-diethylene triamine pentaacetic acid. The affected cerebellar hemisphere is usually

asymmetrically widened. Recently, functional MRI methods, such as diffusion-weighted imaging, perfusion imaging, and MR spectroscopy, have been reported in the assessment of LDD patients. These functional imaging methods might give additional information about the pathophysiology of LDD and be helpful in predicting the natural course of the disease.^[11,12] In the present report, MRI revealed “tiger-striped” appearance characterized by alternant hyper-, and isointense bands on T2-weighted axial sections. Planned MR spectroscopy could not be performed as the patient was admitted to surgery in an emergency condition.

L'hermitte–Duclos disease can be isolated; however, various additional abnormalities reported in association with LDD. In 40% of cases with LDD, a diagnosis of CD is also made.^[10] CD is an autosomal dominant condition, which predisposes to malignancy. CD is characterized by mucocutaneous manifestations of trichilemmomas, related follicular malformations, and distinctive type of hyalinizing, mucinous fibromas, in addition to acral keratoses and oral papillomas.^[10] Genetic analysis has showed that a single locus within chromosome 10q23 is likely to be responsible for both these syndromes.^[13]

Conservative nonoperative approach has been uniformly dismal, although the growth of the tumor tissue has been slow. The operative results also have been showing an improving trend. Recurrences are common because of the incomplete removal, as the tumor blends with the normal tissue despite carrying out macroscopic complete tumor resection.

Conclusion

LDD is a rare entity and which may cause indistinct neurological complaints. The exact pathogenesis remains unknown. MRI is useful and sufficient to demonstrate the typical striated pattern representing the abnormal thickening of the cerebellar folia. Occasionally, the patients with LDD may even have sudden neurological deterioration due to acute herniation as seen in the present case report. It is also imperative to distinguish this disease from other malignant

lesion of the cerebellum and cerebellar malformations with its varied natural course of history and hence better ability to prognosticate such patients.

References

1. Wei G, Zhang W, Li Q, Kang X, Zhao H, Liu X, *et al.* Magnetic resonance characteristics of adult-onset Lhermitte-Duclos disease: An indicator for active cancer surveillance? *Mol Clin Oncol* 2014;2:415-20.
2. Nowak DA, Trost HA. Lhermitte-Duclos disease (dysplastic cerebellar gangliocytoma): A malformation, hamartoma or neoplasm? *Acta Neurol Scand* 2002;105:137-45.
3. Demaerel P, Van Calenbergh F, Wilms G. Lhermitte-Duclos disease: A tumour or not a tumour. *Acta Neurol Scand* 2003;108:294-5.
4. L'hermitte J, Duclos P. On the diffuse ganglioneuroma of the cerebellar cortex. *Bull Assoc Fr Etud Cancer* 1920;9:99-107.
5. Shanley DJ, Vassallo CJ. Atypical presentation of Lhermitte-Duclos disease: Preoperative diagnosis with MRI. *Neuroradiology* 1992;34:103-4.
6. Stathopoulos P, Raymond A, Esson M. Cowden syndrome: Mucocutaneous lesions as precursors of internal malignancy. *Oral Maxillofac Surg* 2014;18:229-35.
7. Nowak DA, Trost HA, Porr A, Stölzle A, Lumenta CB. Lhermitte-Duclos disease (Dysplastic gangliocytoma of the cerebellum). *Clin Neurol Neurosurg* 2001;103:105-10.
8. Abi Lahoud G, Chalouhi N, Zanaty M, Rizk T, Jabbour P. Association of Lhermitte-Duclos disease and split cord malformation in a child. *J Clin Neurosci* 2014.
9. Spaargaren L, Cras P, Bomhof MA, Lie ST, de Barys AM, Croese PH, *et al.* Contrast enhancement in Lhermitte-Duclos disease of the cerebellum: Correlation of imaging with neuropathology in two cases. *Neuroradiology* 2003;45:381-5.
10. Murray C, Shipman P, Khangure M, Chakera T, Robbins P, McAuliffe W, *et al.* Lhermitte-Duclos disease associated with Cowden's syndrome: Case report and literature review. *Australas Radiol* 2001;45:343-6.
11. Moonis G, Ibrahim M, Melhem ER. Diffusion-weighted MRI in Lhermitte-Duclos disease: Report of two cases. *Neuroradiology* 2004;46:351-4.
12. Nagaraja S, Powell T, Griffiths PD, Wilkinson ID. MR imaging and spectroscopy in Lhermitte-Duclos disease. *Neuroradiology* 2004;46:355-8.
13. Nelen MR, Padberg GW, Peeters EA, Lin AY, van den Helm B, Frants RR, *et al.* Localization of the gene for Cowden disease to chromosome 10q22-23. *Nat Genet* 1996;13:114-6.

How to cite this article: Ozeren E, Gurses L, Sorar M, Er U, Önder E, Arikök AT. L'hermitte-Duclos disease in an elderly patient: A case report and review of the literature. *Asian J Neurosurg* 2014;9:246.

Source of Support: Nil, **Conflict of Interest:** None declared.