

## CASE REPORT

# Post-traumatic fibrous dysplasia of the parietal bone: A rare entity

Muhammad Sohail Umerani, Saqib Kamran Bakhshi<sup>1</sup>, Asad Abbas<sup>2</sup>, Salman Sharif, Sidra Arshad<sup>3</sup>

Department of Neurosurgery, Liaquat National Hospital, <sup>1</sup>Department of Surgery, Dow University of Health Sciences, <sup>2</sup>Department of Surgery, Ziauddin University Hospital, <sup>3</sup>Department of Histopathology, Aga Khan University Hospital, Karachi, Pakistan

## ABSTRACT

Fibrous dysplasia (FD) is a rare fibro-osseous lesion in which normal bone is replaced by abnormal fibrous tissue. Although a congenital disorder, a single case report of traumatic etiology had been described in the literature. We report a case of monostotic FD of the parietal calvarium in a 21-year-old female patient who presented to us with a single swelling in the parietal region been noticed after head injury sustained at the age of 7 years. After imaging investigations, the lesion was excised via craniotomy followed by cranioplasty in the same sitting. The histopathological evidence was suggestive of FD. To the best of our knowledge, this is the second case of a posttraumatic cranial FD and the first case describing the growing mass in the parietal bone secondary to head injury.

**Key words:** Cranioplasty, craniotomy, fibrous dysplasia, traumatic

## Introduction

Fibrous dysplasia (FD) is a rare, benign, but progressive fibro-osseous condition where there is a replacement of normal skeletal elements with fibrous connective tissue together with irregular woven bony trabeculae.<sup>[1-3]</sup> It mostly occurs in the long bones such as femur or tibia and craniofacial bones including ethmoid, sphenoid, frontal, maxillary, temporal, and occipital bones. FD of paranasal sinuses is rare. In 70-80%, the disease is monostotic whereas 20-30% of cases are polyostotic. We report a case of monostotic FD of the parietal calvaria secondary to head injury. After exhaustive literature review, we consider this to be the second case of a posttraumatic cranial FD to the best of our knowledge.<sup>[4]</sup>

## Case Report

A 21-year-old female presented to us with a swelling on the right parietal bone close to the midline. The swelling appeared when she was 7 years of age, few months after sustaining a

fall while playing at home. It gradually increased in size. There was no history of headache or any neurological changes. Her neurological examination was normal. On local examination, there was a scalp swelling of about 6.0 cm × 6.0 cm × 3.0 cm at the right parasagittal region behind the coronal suture. It was noncompressible and nonpulsatile, firm in consistency with no skin discoloration. Hair distribution and temperature over the swelling was normal. There was no bruit or thrill. Cough impulse and trans-illumination test were negative. The computerized tomographic (CT) scan brain with bony windows showed a hyperdense mass involving the right parasagittal region with ground-glass appearance and expansion of involved bone [Figures 1-3]. Magnetic resonance imaging (MRI) revealed a bony defect at corresponding site with swelling at the sub-cutaneous mass with no pressure or invasion of the dura or the underlying brain parenchyma or sinus [Figure 4]. Based on history and radiological assessment, the differential diagnoses of FD and sub-periosteal calcification was made. She underwent right parasagittal craniotomy followed by cranioplasty in single sitting [Figure 5].

Her histopathology showed multiple bony trabeculae with intervening trabecular spaces showing fibroblastic proliferation and loss of periosteal rimming suggestive of FD [Figures 6 and 7]. The patient was later discharged and on 30 months follow-up there was no recurrence of the lesion with good aesthetic outcome.

## Discussion

Fibrous dysplasia is a progressive, congenital, nonhereditary, benign skeletal lesion in which cellular fibrous connective tissue together with irregular woven bony trabeculae substitutes

### Access this article online

#### Quick Response Code:



#### Website:

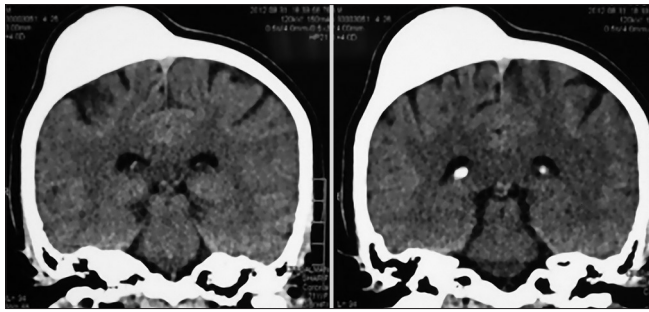
www.asianjns.org

#### DOI:

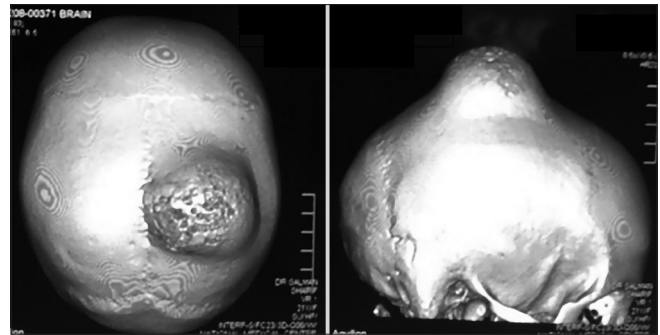
10.4103/1793-5482.148800

### Address for correspondence:

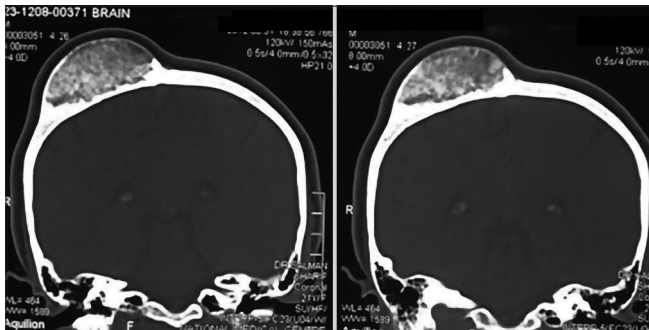
Dr. Asad Abbas, J-8, 3<sup>rd</sup> Floor, Yaqoob Terrace, Main Gurumandir Round About, Karachi - 74800, Pakistan.  
E-mail: asad.abbas@live.com



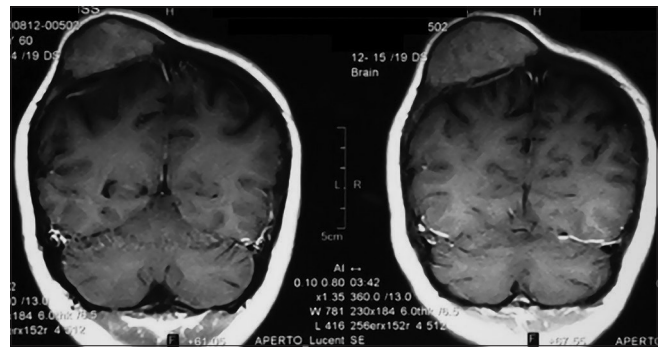
**Figure 1:** Computerized tomographic scan coronal images showing hyperdense bony mass over the right parietal bone which is approaching the midline without any parenchymal involvement



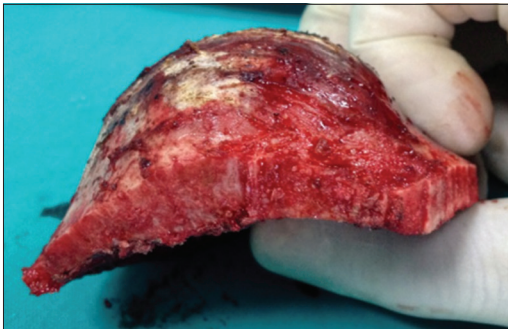
**Figure 2:** Computerized tomographic scan three-dimensional reconstruction showing protuberance of right parietal bone



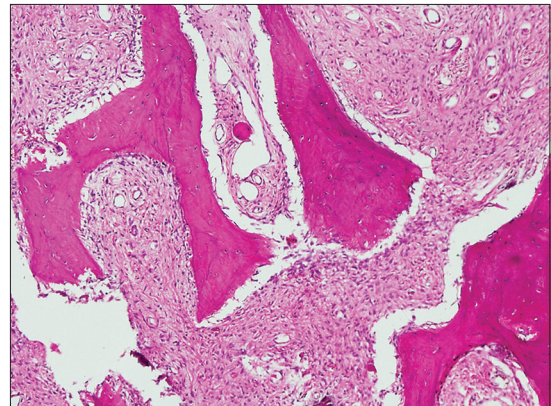
**Figure 3:** Computerized tomographic scan brain plain coronal view (bone window) showing expansion of the right parietal with thinning of the cortex and ground-glass opacity



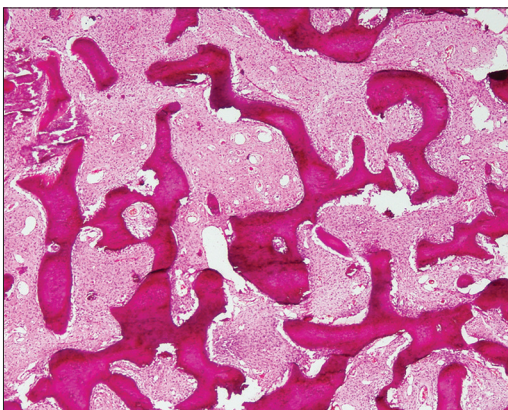
**Figure 4:** Magnetic resonance imaging brain contrast image showing the non-enhancing lesion of the right parietal bone approaching midline with no communication with the underlying brain parenchyma



**Figure 5:** Peroperative picture of resected piece of the bony mass



**Figure 6:** x4 microscopic view showing characteristic thin irregular curvilinear, "Chinese alphabet" spicules of woven bone separated by fibrous stroma



**Figure 7:** x20 microscopic view cellular fibrous tissue containing a proliferation of bland and uniform spindle cells with sparse mitotic activity with scattered thick lamellae bone without significant osteoblastic rimming

focal area of normal bone.<sup>[1-3]</sup> The first reported documentation of this pathology was made by von Recklinghausen in 1891.<sup>[5]</sup> Later it was named FD by Lichtenstein in 1938.<sup>[6]</sup> It accounts for 0.8% of primary and 7% of benign bone tumors.<sup>[2]</sup>

Although the cause is unknown, there is sufficient evidence for the genetic basis of FD where mutation of the Gs  $\alpha$  subunit of G protein-coupled receptor have resulted in proliferation of cyclic adenosine monophosphate.<sup>[7-10]</sup> In 70-80%, the disease is monostotic whereas 20-30% of cases are polyostotic.<sup>[2,7]</sup>

Monostotic condition most often involves the ribs or femur while the involvement of craniofacial bones is up to 25% of cases. This most commonly affects the maxilla and mandible followed by frontal, parietal and occipital bones.<sup>[11,12]</sup> On the other hand, polyostotic FD affects long bones, ribs, and skull, occurring unilaterally in most cases.<sup>[5]</sup> In this form there is nearly 100% involvement of the craniofacial bones with involvement of ethmoid, sphenoid, frontal, maxillary, temporal, and occipital bones in descending order of frequency.<sup>[13]</sup>

Another study of 36 patients with FD affecting skull reported that the most commonly involved area was the frontal bone (52.78%). The next was temporal bone (30.56%), followed by the sphenoid (25%), parietal bone (19.44%), and orbit (13.89%).<sup>[14]</sup>

Polyostotic FD is often seen as part of a rare condition termed McCune-Albright syndrome occurring exclusively in females, where it accompanies pigmented skin (café-au-lait spots) and endocrinopathies (sexual precocity).<sup>[7,11,15]</sup> Although many patients are asymptomatic, the clinical presentation varies with the primary site of skeletal area involved, duration and extent of the disease.<sup>[12]</sup> Usually it presents as a painless slow growing mass with cosmetic disfigurement and asymmetry, headache, paresthesia or numbness, ocular proptosis, visual and hearing impairment, malocclusion, nasal obstruction, epistaxis, anosmia, epiphora, and neurological changes.<sup>[8,11,12,16]</sup>

Facial disfigurement referred to as leontiasis osseous (“lion face”) is seen with extensive involvement of the maxillary bone.<sup>[17]</sup> Majority of the patients is in their third decade at the time of diagnosis although literature has shown age range between 10 and 70 years.<sup>[17-22]</sup> Although fusion of growth plates restrict the development of any new FD lesion, however some would continue to progress despite skeletal maturation.<sup>[17]</sup> Polyostotic form of the disease affects patients at a significantly younger age. Monostotic form affects both males and females equally, but the polyostotic form is more prevalent in females.<sup>[23]</sup>

Computerized tomographic scan and MRI are essential to delineate any neurovascular and ocular involvement.<sup>[24]</sup> CT scan is the imaging modality of choice for the evaluation of FD. Characteristic findings include a “ground-glass” opacity, ballooning and expansion of the affected bone with thinning of the cortex.<sup>[25]</sup> Fries in 1957 described three different radiographic patterns of FD. These include pagetoid type (56%) which is a combination of dense and radiolucent areas of fibrosis; sclerotic type (23%), consisting of a homogeneously dense mass; and cystic type (21%), with a spherical or ovoid lucency bounded by a dense rim.<sup>[26]</sup> FD is hypointense on T1-weighted image while the signal intensity on T2-weighted image varies from high to intermediate or low.

Medical management of the condition is often dealt with bisphosphonates. This reduces the risk of subsequent fracture

and relieves pain.<sup>[7,26,27]</sup> Previous studies have documented the role of steroids in the treatment of an acute episode of visual impairment in patients with optic neuropathy secondary to FD.<sup>[28]</sup> For nonprogressive, asymptomatic lesions observation is generally required. Surgery is the optimum treatment modality for definitive diagnosis, disease progression or malignant degeneration, removal of compressive lesion, for cosmetic purpose and failure of nonsurgical therapy.<sup>[2,11]</sup> This varies from simple shaving, curettage or contouring of the lesion to a more aggressive resection, often accompanied by a reconstructive surgery as well to fill up the bony defect.<sup>[8,16]</sup>

It grossly appears as a firm solid grey-white mass with varied consistency and vascularity.<sup>[2,11]</sup> Histologically it is comprised of osseous and fibrous components. The osseous component is composed of thinned, irregular bone with loss of osteoblastic rimming. The intervening marrow is replaced by fibroblastic proliferation of bland spindle shaped cells.

In our case, the abnormal growth of bone started immediately after injury, however, the detailed mechanism underlying head trauma and pathogenesis of FD is still unknown, and it is possible that the relationship between these two is merely a coincidence. However, one article has reported a relationship between FD pathogenesis and increased expression of the c-fos gene.<sup>[29]</sup> Up-regulation of c-fos gene in relation to trauma has also been previously described. Therefore, there is also a possibility of induction of FD by trauma via a c-fos gene-mediated mechanism.

On follow-up the patients are clinically and radiologically assessed at regular intervals.<sup>[8]</sup> CT scan is the main stay for following such lesions after surgical excision.<sup>[1]</sup> The response to treatment can be assessed with the help of bone markers. These include total serum bone alkaline phosphatase and urine hydroxyproline, the levels of which are raised in the active phase of the disease.<sup>[7]</sup>

Spontaneous sarcomatous transformation has been reported in less than 1% of the monostotic cases mostly after radiation therapy.<sup>[30]</sup> Malignant transformation is most common to osteosarcoma,<sup>[31]</sup> although fibrosarcoma, chondrosarcoma or malignant fibrous histiocytoma has also been reported.<sup>[7,9,22,28,32]</sup> Generally the outcome of FD is better except in young patients and those with polyostotic form of the disease.<sup>[7]</sup> Although rare in adults but the recurrence has been reported if the lesion is dealt surgically during their active disease phase.

## Conclusion

To the best of our knowledge, this is the second case report of a posttraumatic cranial FD and the first case describing the lesion in the parietal bone after head injury. Most of the monostotic asymptomatic craniofacial lesions are identified incidentally. These may be surgically excised if there is a doubt in diagnosis,

cosmetic disfigurement, neurological involvement, disease progression or malignant transformation.

## References

- Sandhu SV, Sandhu JS, Sabharwal A. Clinoradiologic perspective of a severe case of polyostotic fibrous dysplasia. *J Oral Maxillofac Pathol* 2012;16:301-5.
- Mahadevappa A, Patel S, Ravishankar S, Manjunath GV. Monostotic fibrous dysplasia of the rib: A case report. *Case Rep Orthop* 2012;2012:690914.
- Lee JW, Kim JH, Han SH, Kang HI. Fibrous Dysplasia with Aneurysmal Bone Cyst Presenting as Painful Solitary Skull lesion. *J Korean Neurosurg Soc* 2010;48:551-4.
- Tomiyaama A, Aoki K, Nakayama H, Izukura H, Kimura H, Harashina J, *et al.* Posttraumatic cranial cystic fibrous dysplasia. *Case Rep Med* 2011;2011:680401.
- Iseri PK, Efendi H, Demirci A, Komsuoglu S. Fibrous dysplasia of the cranial bones: A case report and review of the literature. *Yale J Biol Med* 2005;78:141-5.
- Albright F, Butler AM, Hampton AO, Smith PH. Syndrome Characterized by Ostitis fibrosa disseminata, areas of pigmentation and endocrine dysfunction, with precocious puberty in females: Report of five cases. *N Engl J Med* 1937;216:727-46.
- Parekh SG, Donthineni-Rao R, Ricchetti E, Lackman RD. Fibrous dysplasia. *J Am Acad Orthop Surg* 2004;12:305-13.
- Cheng J, Wang Y, Yu H, Wang D, Ye J, Jiang H, *et al.* An epidemiological and clinical analysis of craniomaxillofacial fibrous dysplasia in a Chinese population. *Orphanet J Rare Dis* 2012;7:80.
- Traibi A, El Oueriachi F, El Hammoumi M, Al Bouzidi A, Kabiri el H. Monostotic fibrous dysplasia of the ribs. *Interact Cardiovasc Thorac Surg* 2012;14:41-3.
- Feller L, Wood NH, Khammissa RA, Lemmer J, Raubenheimer EJ. The nature of fibrous dysplasia. *Head Face Med* 2009;5:22.
- Park HJ, Cho MS, Lee SS. Fibrous dysplasia of the inferior turbinate. *Int J Clin Exp Pathol* 2013;6:531-5.
- Kim E. Fibrous dysplasia of the clivus. *J Korean Neurosurg Soc* 2010;48:441-4.
- Dumitrescu CE, Collins MT. McCune-Albright syndrome. *Orphanet J Rare Dis* 2008;3:12.
- Cai M, Ma L, Xu G, Gruen P, Li J, Yang M, *et al.* Clinical and radiological observation in a surgical series of 36 cases of fibrous dysplasia of the skull. *Clin Neurol Neurosurg* 2012;114:254-9.
- Ozek C, Gundogan H, Bilkay U, Tokat C, Gurler T, Songur E. Craniomaxillofacial fibrous dysplasia. *J Craniofac Surg* 2002;13:382-9.
- Lee JS, FitzGibbon EJ, Chen YR, Kim HJ, Lustig LR, Akintoye SO, *et al.* Clinical guidelines for the management of craniomaxillofacial fibrous dysplasia. *Orphanet J Rare Dis* 2012;7 Suppl 1:S2.
- Ricalde P, Horswell BB. Craniomaxillofacial fibrous dysplasia of the fronto-orbital region: A case series and literature review. *J Oral Maxillofac Surg* 2001;59:157-67.
- Ayadi-Kaddour A, Ben Slama S, Marghli A, Mehouchi R, Djilani H, Kilani T, *et al.* [Fibrous dysplasia of the rib. Ten case reports]. *Rev Chir Orthop Reparatrice Appar Mot* 2008;94:301-7.
- Snieiders MN, van Kemenade FJ, van Royen BJ. Monostotic fibrous dysplasia of a lumbar vertebral body with secondary aneurysmal bone cyst formation: a case report. *J Med Case Rep* 2009;3:7227.
- Hughes EK, James SL, Butt S, Davies AM, Saifuddin A. Benign primary tumours of the ribs. *Clin Radiol* 2006;61:314-22.
- Remotti F, Feldman F. Non-neoplastic lesions that simulate primary tumors of bone. *Arch Pathol Lab Med* 2012;136:772-88.
- Terkawi AS, Al-Qahtani KH, Baksh E, Soualmi L, Mohamed Ael-B, Sabbagh AJ. Fibrous dysplasia and aneurysmal bone cyst of the skull base presenting with blindness: A report of a rare locally aggressive example. *Head Neck Oncol* 2011;3:15.
- Guruprasad Y, Prabhakar C. Craniomaxillofacial polyostotic fibrous dysplasia. *Contemp Clin Dent* 2010;1:177-9.
- Eversole R, Su L, ElMofty S. Benign fibro-osseous lesions of the craniofacial complex. A review. *Head Neck Pathol* 2008;2:177-202.
- MacDonald-Jankowski DS, Yeung R, Li TK, Lee KM. Computed tomography of fibrous dysplasia. *Dentomaxillofac Radiol* 2004;33:114-8.
- Contratti F, Menniti A, Fraioli MF, Fraioli B. Fibrous dysplasia of the clivus with a second T8 bone lesion: Case report. *Surg Neurol* 2006;65:202-5.
- Wei YT, Jiang S, Cen Y. Fibrous dysplasia of skull. *J Craniofac Surg* 2010;21:538-42.
- Shah ZK, Peh WC, Koh WL, Shek TW. Magnetic resonance imaging appearances of fibrous dysplasia. *Br J Radiol* 2005;78:1104-15.
- Marie PJ, de Pollak C, Chanson P, Lomri A. Increased proliferation of osteoblastic cells expressing the activating Gs alpha mutation in monostotic and polyostotic fibrous dysplasia. *Am J Pathol* 1997;150:1059-69.
- DiCaprio MR, Enneking WF. Fibrous dysplasia. Pathophysiology, evaluation, and treatment. *J Bone Joint Surg Am* 2005;87:1848-64.
- Sadeghi SM, Hosseini SN. Spontaneous conversion of fibrous dysplasia into osteosarcoma. *J Craniofac Surg* 2011;22:959-61.
- Fitzpatrick KA, Taljanovic MS, Speer DP, Graham AR, Jacobson JA, Barnes GR, *et al.* Imaging findings of fibrous dysplasia with histopathologic and intraoperative correlation. *AJR Am J Roentgenol* 2004;182:1389-98.33

**How to cite this article:** Umerani MS, Bakhshi SK, Abbas A, Sharif S, Arshad S. Post-traumatic fibrous dysplasia of the parietal bone: A rare entity. *Asian J Neurosurg* 2017;12:547-50.

**Source of Support:** Nil, **Conflict of Interest:** None declared.