

CASE REPORT

Recurrent intraventricular meningioma with malignant transformation

Jasmit Singh, Hrushikesh Kharosekar, Vernon Velho

Department of Neurosurgery, Grant Medical College, Mumbai, Maharashtra, India

ABSTRACT

Benign meningioma undergoing a malignant transformation (to a chondrosarcoma) in intraventricular location is very rare and this is first case report to best of our knowledge. Herein, we report a rare case of malignant transformation of a benign intraventricular meningioma with relevant literature.

Key words: Chondrosarcoma, intraventricular, meningioma, malignant transformation

Introduction

Meningioma is the second most common intracranial tumor next to gliomas, comprising 15-20% of all primary tumors. Intraventricular meningiomas are rare, comprising of <3% of intracranial meningiomas in most of the series.^[1,2] Majority of meningiomas are benign, however sometimes they show altered biologic behavior associated with local aggressiveness, recurrences and distal metastases. Benign meningioma undergoing a malignant transformation (to a chondrosarcoma) in intraventricular location is very rare, and this is first case report to best of our knowledge. Herein, we report a rare case of malignant transformation of a benign intraventricular meningioma with relevant literature.

Case Report

A 25-year-old right handed male was admitted in May 2010 with chief complaints of occipital headache for 2 months associated with complaints of giddiness, double vision and vomiting from 2 weeks. Patient also had h/o seizures once every 2-3 weeks from 2 months. On examination, patient was conscious, and had left VIth nerve paresis. Patient's vision was 6/9 bilaterally;

fundus examination revealed bilateral papilledema. Computed tomography (CT) and magnetic resonance imaging (MRI) brain with contrast showed homogeneously enhancing mass in atrium of right lateral ventricle which was moderately vascular on cerebral digital subtraction angiography and was supplied by branches of right middle cerebral artery and right posterior cerebral artery [Figure 1]. Patient was operated by a right temporoparietal craniotomy and Simpson Grade 1 excision was achieved via transcortical approach through inferior parietal lobule. Tumor was seen arising in trigone with no definite dural attachment. Patient was extubated at the end of surgery and remained neurologically intact. Biopsy was suggestive of angiomatous meningioma (WHO Grade 1). There was no evidence of malignancy [Figure 2a].

As per our protocol slides were reconfirmed. Postoperative scan revealed complete resection [Figures 3 and 4]. Follow-up MRI Brain with contrast at 6 months demonstrated small enhancing lesion in tumor bed suggestive of recurrence [Figures 5 and 6]. Since the lesion was small, patient was given options of either gamma knife or regular follow-up with MRI at 3 month interval. Patient presented in November 2012 with 2 episodes of seizures. MRI brain showed well enhancing dumbbell shaped lesion of size 4.6 × 4.2 involving trigone of right lateral ventricle with an extracranial part involving bone [Figure 7]. Patient underwent surgery for the same and complete excision was achieved; bone flap was discarded. Tumor was greyish, vascular and suckable and was firm at places. Biopsy revealed mesenchymal chondrosarcoma which was reconfirmed [Figures 2b, c]. Patient was given adjuvant radiotherapy; a total of 55.8 Gy in 301 fractions were given over 6 weeks. Follow-up MRI at time of discharge, and at 6 months did not show any sign of recurrence [Figures 8]. Patient is on regular follow-up in our OPD and is doing well till date.

Discussion

Meningioma's arising in the ventricle without any dural attachment are uncommon in adults. They can arise from the tela

Access this article online

Quick Response Code:



Website:

www.asianjns.org

DOI:

10.4103/1793-5482.149996

Address for correspondence:

Dr. Jasmit Singh, Department of Neurosurgery, Grant Medical College and JJ Group of Hospitals, Byculla, Mumbai - 400 008, Maharashtra, India.

E-mail: hkharosekar@gmail.com

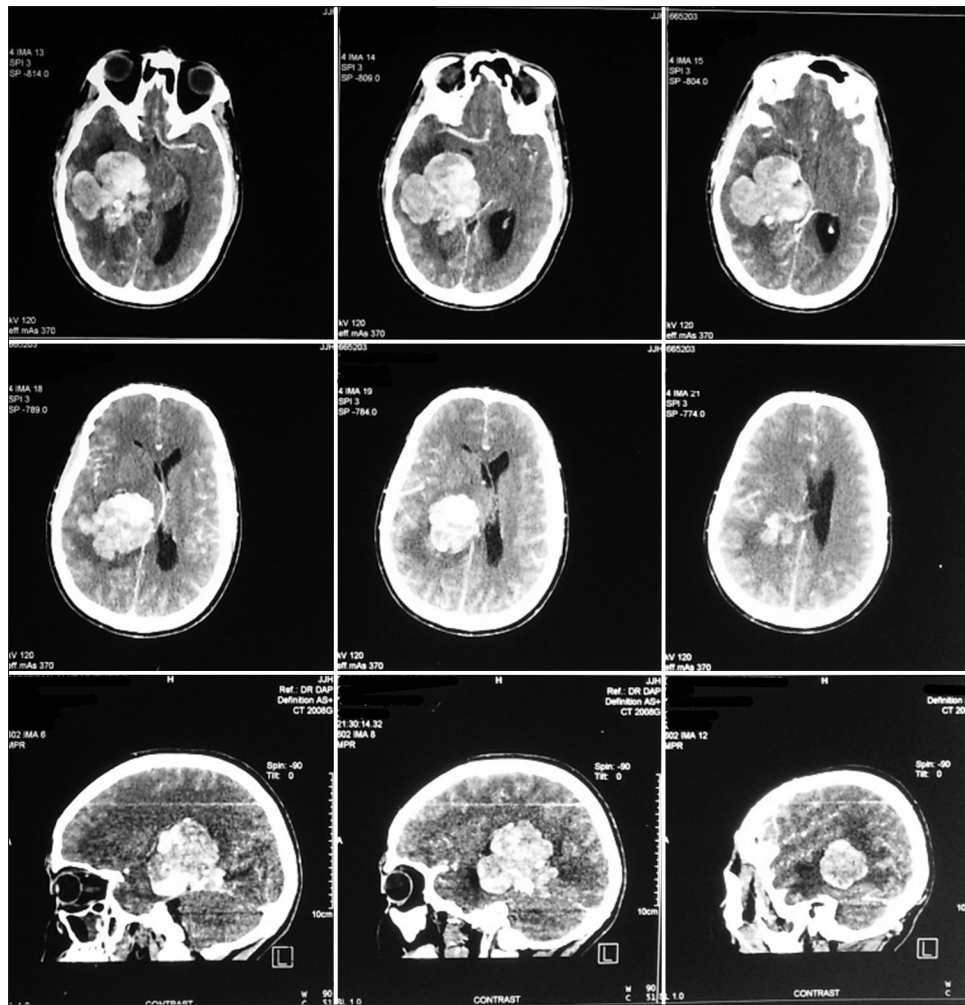


Figure 1: Computed tomography Brain with contrast before 1st surgery showing homogenously enhancing mass in atrium of right lateral ventricle

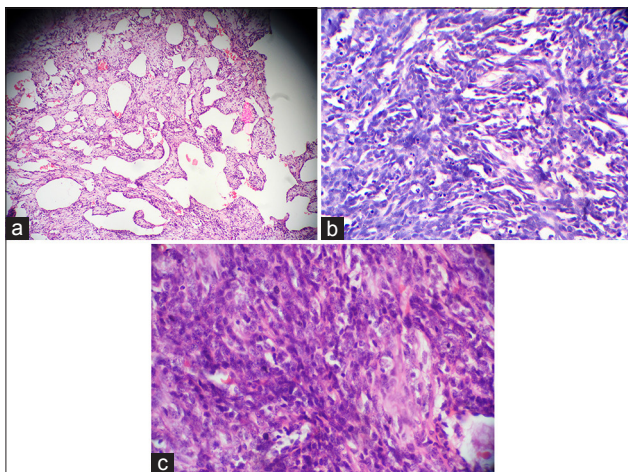


Figure 2: (a) Histopathology slide after 1st surgery s/o angiomatous meningioma. (b) Histopathology slide after 2nd surgery, showing small round nuclei with chondroid element s/o chondrosarcoma. (c) Histopathology slide after 2nd surgery, showing chondroid elements

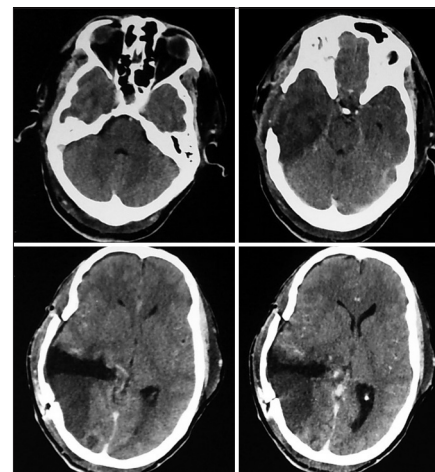


Figure 3: Postoperative computed tomography brain with contrast after 1st surgery showing complete excision of lesion

choroidea and the choroid plexus stroma. Most intraventricular meningioma's are benign, and the incidence of intraventricular non benign meningioma's is <1%.^[1] Intraventricular meningioma

is more common in trigone of lateral ventricle, usually the left. Because of its location, it remains asymptomatic until it reaches a certain size, and the symptoms start to appear after the tumor has grown up sufficiently.^[1,2] The symptoms are, therefore, determined by size and location. MRI with contrast

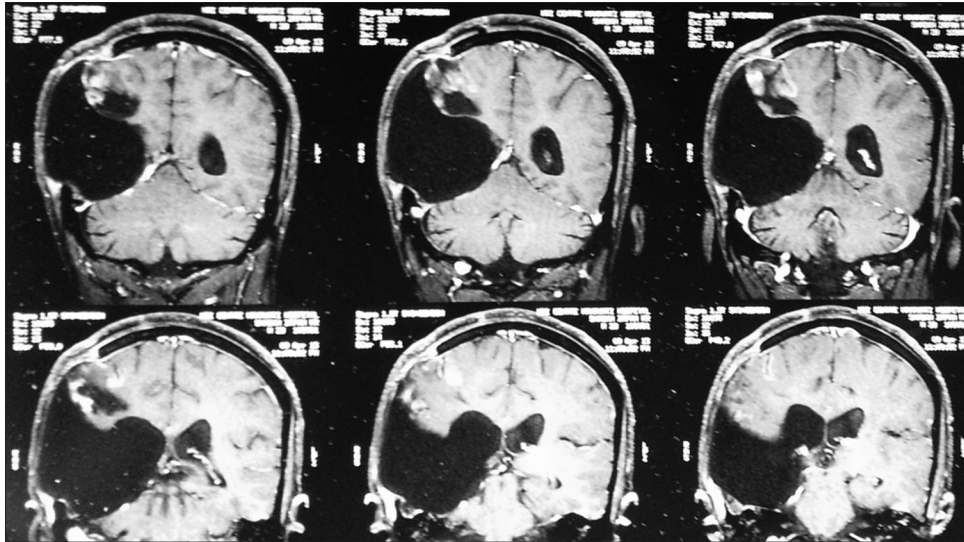


Figure 4: Postoperative magnetic resonance imaging brain with contrast after 1st surgery showing complete excision

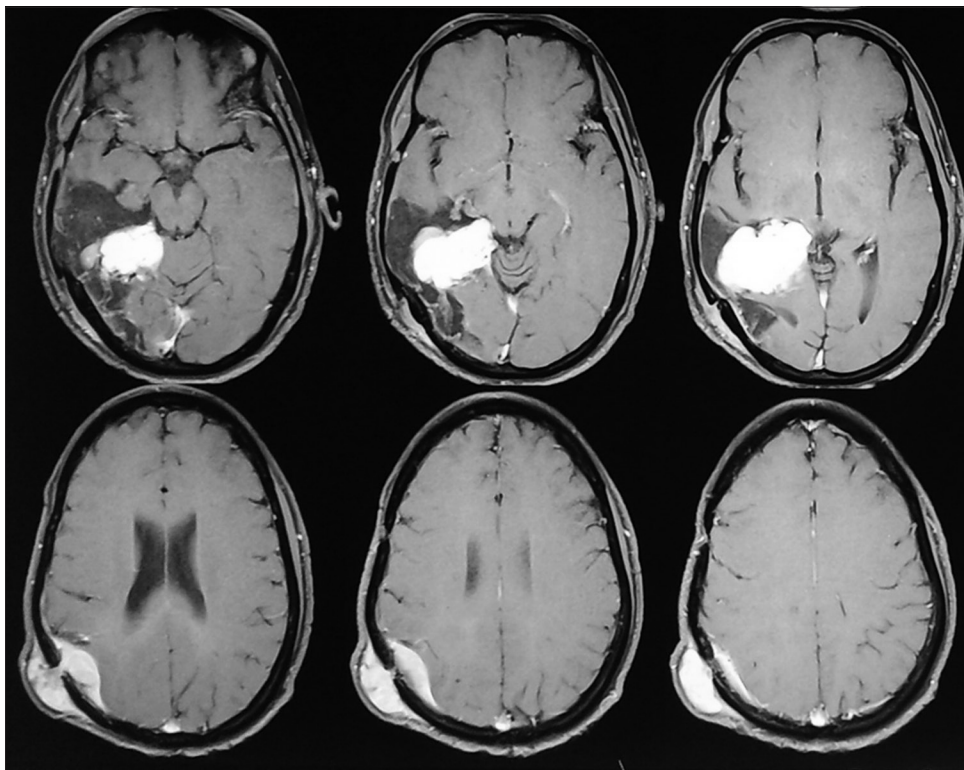


Figure 5: Follow-up magnetic resonance imaging brain after 6 months showing small enhancing lesion in tumor bed suggestive of recurrence

is the diagnostic modality of choice. Several authors have attempted to find neuroradiological characteristics that can predict recurrence. Mantle *et al.* reported that the chance of brain invasion and recurrence increases by 20% with each centimeter of brain edema surrounding the meningioma on CT scanning. Nakasu *et al.* showed that the “lobulated” or “mushrooming” appearances of meningioma’s noted on preoperative imaging studies correlates with higher recurrence rate for these tumors. Incidence of recurrence after Simpson Grade 1 excision is 13.8% and is higher after incomplete resection.^[3]

The overall rate of progression from a benign tumor to higher grade tumor ranges from 0.16% to 2.0%, and risk of progression from atypical to malignant form is 26% to 33%.^[1,4] Heterogeneous signal intensity on T1 and T2 and heterogeneous enhancing pattern should raise the suspicion of malignant transformation. In the transformation of meningioma the loss of heterozygosity at 22q is considered to be the earliest initiating event, followed by allelic loss involving number of chromosomes.^[1] Once detected recurrences are managed depending upon patient and tumor profile; and further treatment is offered based on

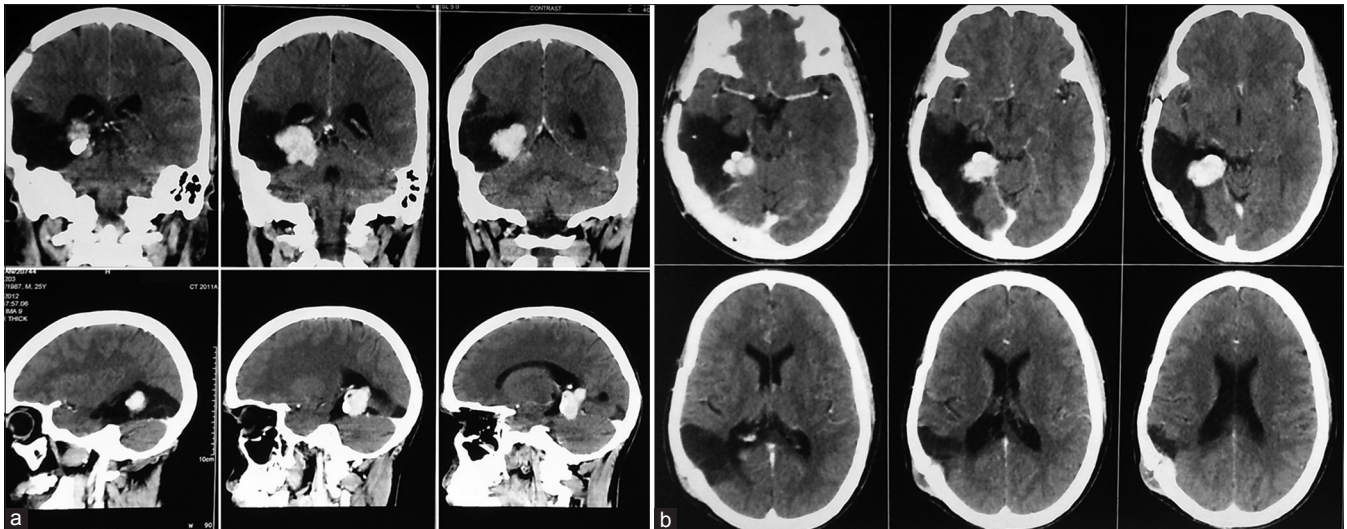


Figure 6: (a and b) Computed tomography brain with contrast after 6 months showing the recurrence of the tumor at operative site

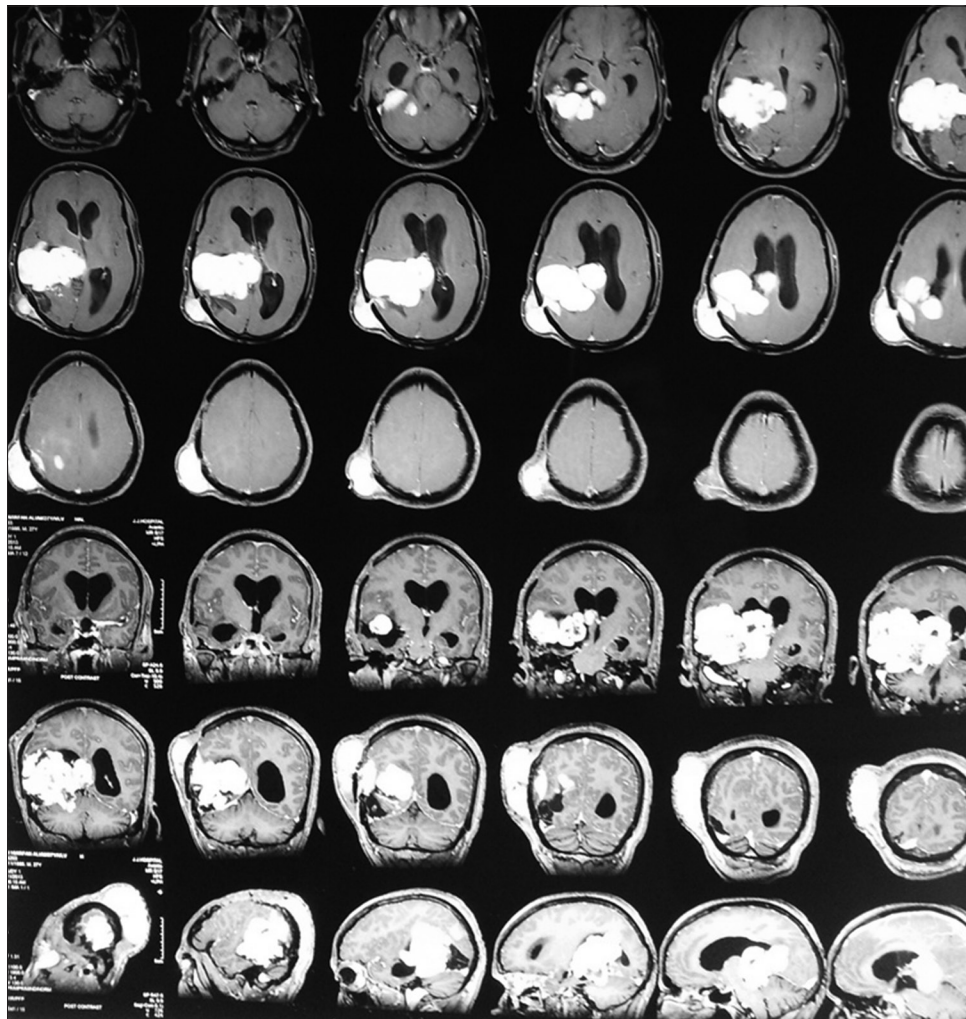


Figure 7: Magnetic resonance imaging brain with contrast before 2nd surgery showing enhancing dumbbell shaped lesion involving trigone of right lateral ventricle with an extracranial part involving bone

the histopathology. Any evidence of malignancy should be followed-up with radiotherapy and serial MRI.

The pleuripotent nature of arachnoid cap cells or their precursors is reflected in the remarkable histologic diversity

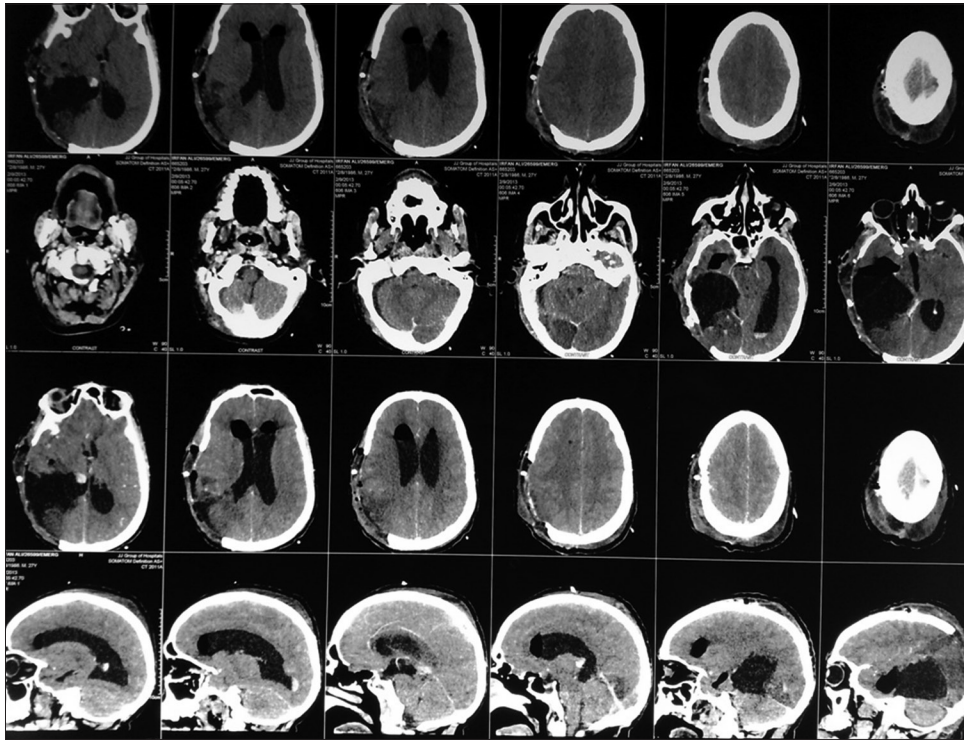


Figure 8: Postoperative computed tomography brain after 2nd surgery showing complete excision

of meningiomas. In our case a benign meningioma underwent malignant transformation to chondrosarcoma.^[5]

Chondrosarcomas are malignant cartilaginous neoplasms that originate from bone, cartilage, and mesenchymal soft tissue. Intracranial chondrosarcomas account for 0.16% of intracranial neoplasms.^[5,6] Although 75% of intracranial chondrosarcomas originate from the skull base, they can also arise from the meninges along the falx, tentorium and convexity. Because of relatively nonspecific radiological findings they are usually misdiagnosed as meningiomas initially.^[6,7] Surgical resection along with radiotherapy is the mainstay of treatment.^[6,7]

Only one previous case report describes transformation of a recurrent petroclival meningioma to a chondrosarcoma after 2 sittings of Gamma knife.^[8] In our case an intraventricular angiomatous meningioma underwent malignant transformation to a chondrosarcoma, this has not been reported so far in the literature.

Sarcomatous transformation of benign meningioma in intraventricular location is relatively rare, and aggressive treatment, and meticulous follow-up is required. Postoperative radiotherapy is recommended to reduce local recurrence.

References

1. Kim HD, Choi CY, Lee DJ, Lee CH. Intraventricular atypical meningiomas. *J Korean Neurosurg Soc* 2011;49:292-5.
2. Pires de Aguiar PH. Intraventricular meningiomas in adult-clinical series and review of literature. *Rev Chil Neurocir* 2011;37:23-8.
3. Mantle RE, Lach B, Delgado MR, Baeesa S, Bélanger G. Predicting the probability of meningioma recurrence based on the quantity of peritumoral brain edema on computerized tomography scanning. *J Neurosurg* 1999;91:375-83.
4. Garcia-Conde M, Roldan-Delgado H, Martel-Barth-Hansen D, Manzano-Sanz C. Anaplastic transformation of an atypical intraventricular meningioma with metastases to the liver: case report. *Neurocirugia (Astur)* 2009;20:541-9.
5. Robert H Wilkins, Setti S Rengacharry. *Neurosurgery*. McGRAW-HILL Health professional Division; Vol 1. 1986; p. 843-53.
6. Chu PY, Wei CP. Chondrosarcoma of the skull base – Report of two cases. *Tzu Chi Med J* 2006;18:229-31.
7. Kaya A, Türkmenoglu O. Intracranial mesenchymal chondrosarcoma: Introducing two cases. *Turk Neurosurg* 1999;9:144-50.
8. Lall RR. Delayed malignant transformation of recurrent petroclival meningioma to chondrosarcoma after stereotactic radiosurgery - A case report. *J Neurol Surg B* 2012;73:A247.

How to cite this article: Singh J, Kharosekar H, Velho V. Recurrent intraventricular meningioma with malignant transformation. *Asian J Neurosurg* 2017;12:551-5.

Source of Support: Nil, **Conflict of Interest:** None declared.