

## CASE REPORT

# Primary intracranial rhabdomyosarcoma of the cerebellopontine angle mimicking a vestibular schwannoma in a child

Prakash Nair, Kuntal Kanti Das, Arun K. Srivastava, R. N. Sahu, Raj Kumar, Kamlesh Yadava<sup>1</sup>, Rakesh Pandey<sup>1</sup>

Departments of Neurosurgery and <sup>1</sup>Pathology, Sanjay Gandhi Postgraduate Institute of Medical Sciences, Lucknow, Uttar Pradesh, India

## ABSTRACT

Primary intracranial rhabdomyosarcoma (PIRMS) is a rare neoplasm, which affects infants and young children. We report a rare case of a primary embryonal rhabdomyosarcoma of the cerebellopontine angle in a 7-year-old boy with clinical and radiological features mimicking a vestibular schwannoma. The patient underwent definitive surgery and radiotherapy and is recurrence free at 6 months. PIRMS commonly occur in parameningeal locations or metastasize to the brain from an extracranial primary. Gross total tumor resection followed by adjuvant radiotherapy remains the current standard of treatment; however, chemotherapy has also been tried with favorable results. The overall prognosis continues to remain poor.

**Key words:** Cerebellopontine angle, embryonal rhabdomyosarcoma, medulloblastoma, vestibular schwannoma

## Introduction

Primary intracranial rhabdomyosarcoma (PIRMS) is a rare tumor of mesenchymal origin. It affects the pediatric population more commonly, usually presenting with a short duration of symptoms and a rapid progression.<sup>[1]</sup> PIRMS has a predilection for the cerebellum; however, supratentorial involvement has also been reported.<sup>[2-4]</sup> We present a case of PIRMS in a 7-year-old boy, which clinically and radiologically mimicked a vestibular schwannoma, and discuss the histology and treatment options in this condition.

## Case Report

A 7-year-old male patient was seen in our outpatient clinic with complaints of gradually progressing hearing loss in the right ear with disequilibrium and headache associated with projectile vomiting for 1 month and episodes of transient loss

of consciousness, each episode lasting for about 30 minutes. Clinical examination revealed grade 4 papilledema, infranuclear facial palsy on the right side, and sensorineural hearing loss in the right ear with impaired gag reflex and cerebellar signs on the right side.

Magnetic resonance imaging (MRI) with gadolinium contrast [Figure 1b-1e] showed an extra-axial lesion in the right cerebellopontine angle measuring 4×4.5×5.5 cm, which was isointense on T1W and hyperintense on T2W with intense contrast enhancement. The lesion was extending into the internal auditory meatus along with the 7<sup>th</sup>/8<sup>th</sup> nerve complex. The brainstem and the fourth ventricle were both pushed to the left and distorted by the tumor and there was no hydrocephalus. The imaging was consistent with a vestibular schwannoma.

The tumor was approached through a right retromastoid craniectomy. The tumor was firm with a fleshy consistency and moderately vascular, except at the lower pole where it was mucinous with a well-defined plane of cleavage from the brainstem and the cerebellum (an appearance unlike a

This is an open access article distributed under the terms of the Creative Commons Attribution-NonCommercial-ShareAlike 3.0 License, which allows others to remix, tweak, and build upon the work non-commercially, as long as the author is credited and the new creations are licensed under the identical terms.

**For reprints contact:** reprints@medknow.com

**How to cite this article:** Nair P, Das KK, Srivastava AK, Sahu RN, Kumar R, Yadava K, *et al.* Primary intracranial rhabdomyosarcoma of the cerebellopontine angle mimicking a vestibular schwannoma in a child. *Asian J Neurology* 2017;12:109-11.

### Access this article online

#### Quick Response Code:



#### Website:

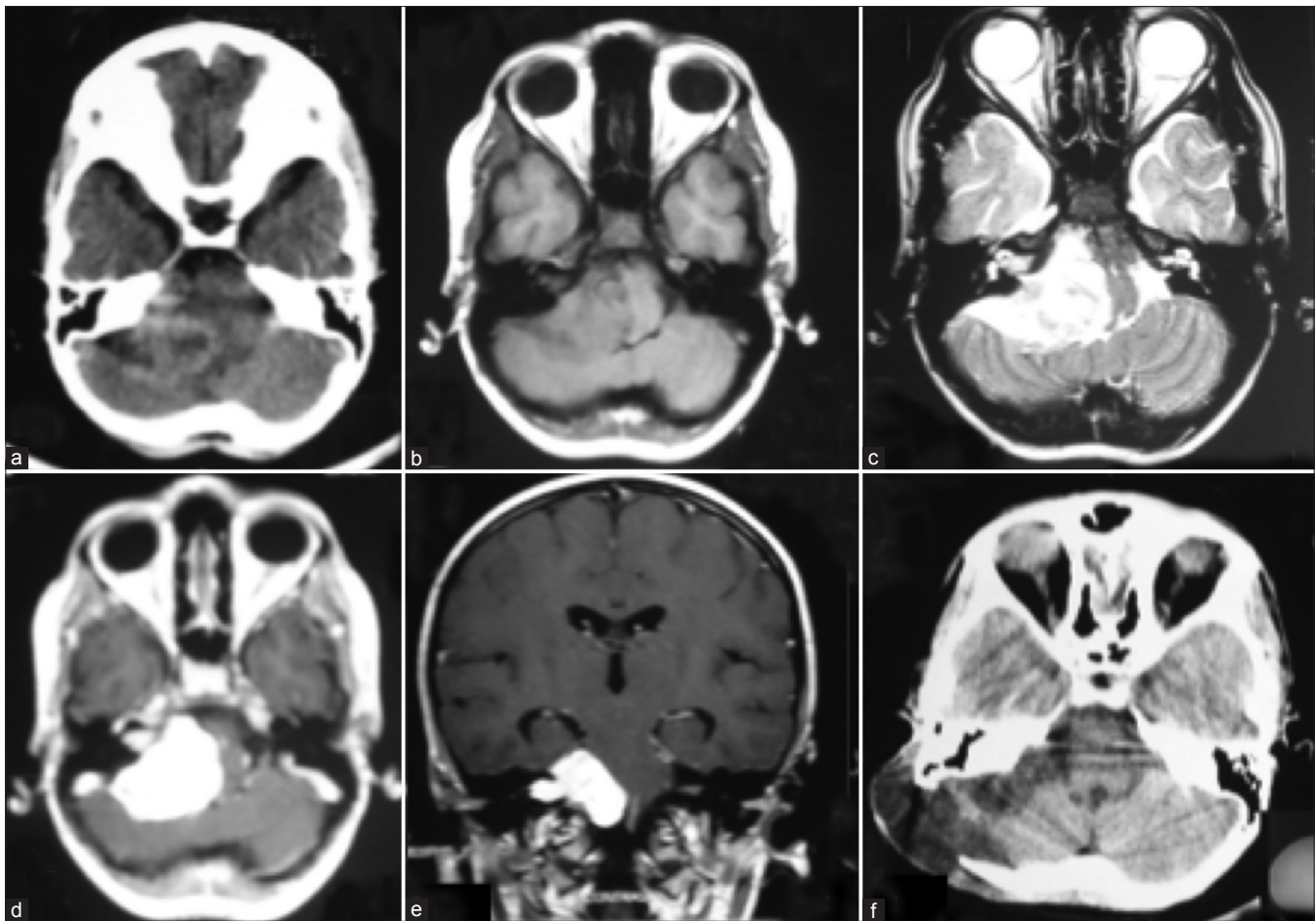
www.asianjns.org

#### DOI:

10.4103/1793-5482.150000

### Address for correspondence:

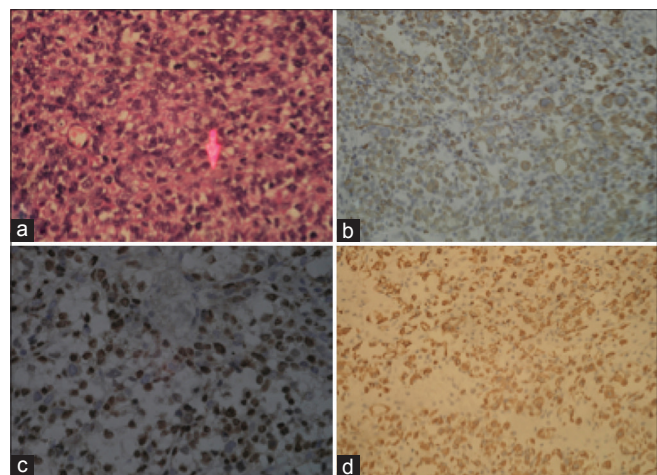
Dr. R. N. Sahu, Department of Neurosurgery, Sanjay Gandhi Postgraduate Institute of Medical Sciences, Lucknow - 226 014, Uttar Pradesh, India. E-mail: drnsahu@gmail.com



**Figure 1:** (a) CECT showing a heterogeneously enhancing extra-axial tumor in the right CPA cistern; (b) MRI T1W shows an isointense lesion in the right CPA, note the gross distortion of the pons. The tumor measured 4×4.5×5.5 cm; (c) On T2W, the lesion is hyperintense, with clefts of CSF seen adjacent to the cerebellum and the brainstem; (d) T1W post-gadolinium contrast shows bright contrast enhancement with an intrametral extension; (e) Coronal T1W post-gadolinium contrast shows the tumor causing gross brainstem distortion, with the rostral extent reaching the tentorium with no hydrocephalus; (f) postoperative CECT, 3 weeks after surgery shows no residual tumor. Postoperative craniectomy defect and a pseudomeningocele is seen

typical schwannoma). The 7<sup>th</sup> and the 8<sup>th</sup> nerves were not seen separately from the tumor and could not be preserved at surgery. Complete excision of the tumor was done. In the postoperative period, the patient required lateral tarsorrhaphy to prevent corneal exposure in the right eye. He was discharged on the 7<sup>th</sup> postoperative day. Three weeks later, the patient returned with a pseudomeningocele at the operative site. Contrast-enhanced CT scan [Figure 1f] showed complete tumor excision with hydrocephalus and subgaleal collection of CSF at the surgical site. A ventriculoperitoneal shunt was performed on the left side, which successfully controlled the pseudomeningocele. He underwent fractionated external beam radiotherapy (5400 cGY/30 fractions) but declined any further treatment. At 6-month follow-up he had mild ataxia, but was otherwise asymptomatic. MRI of the brain showed no recurrence after 6 months of surgery.

Histopathological examination of surgical specimen [Figure 2a] showed a cellular tumor with mild to moderately pleomorphic



**Figure 2:** (a) Hematoxylin and eosin-stained section showed a cellular tumor with round nuclei, coarse chromatin, small to conspicuous nucleoli and moderate amount of eosinophilic cytoplasm. Arrow points to a cell with tailing of the cytoplasm (b) Myogenin immunohistochemistry showed diffuse strong nuclear staining (c and d) Diffuse strong cytoplasmic staining for desmin and vimentin, respectively

round nuclei, coarse chromatin, and conspicuous nucleoli, with moderate to abundant eosinophilic cytoplasm with suggestion of cytoplasmic striations in places. A histological differential diagnosis of medulloblastoma and rhabdomyosarcoma was considered. To differentiate these two conditions, immunohistochemistry for desmin, vimentin, myogenin, GFAP, synaptophysin, and neurofilament was performed. The tumor cells were immunoreactive for desmin, vimentin, and myogenin [Figure 2b-2d]. GFAP, synaptophysin, and neurofilament were negative. With the aforementioned histological features and immunohistochemistry, the diagnosis of rhabdomyosarcoma was offered.

## Discussion

Primary intracranial sarcomas are exceedingly rare tumors constituting 0.1-0.2% of all intracranial tumors.<sup>[1,2]</sup> Primary intracranial rhabdomyosarcoma (PIRMS) is more commonly seen in infants and young children with only nine reported cases in adults.<sup>[3-7]</sup> The most common site of involvement in children is the cerebellum<sup>[4]</sup> unlike adults in whom a supratentorial predilection is seen.<sup>[8]</sup> Rhabdomyosarcoma is the most common soft tissue sarcoma occurring in children and most commonly affects the head and neck. In the head and neck region, it occurs in parameningeal locations like nasopharynx, nasal cavity, paranasal sinuses, temporal bone, pterygopalatine fossa, and infratemporal fossa. Intracranial RMS may also occur following local extension to the meninges and then the brain, or may occur as secondaries from an extracranial primary.<sup>[1,2]</sup>

Rhabdomyosarcoma is classified into four pathological subtypes (1) embryonal, (2) alveolar, (3) botryoid, and (4) pleomorphic.<sup>[7]</sup> Berard who called it "tumeur embryonnaire du muscle striae" described the embryonal rhabdomyosarcoma in 1894.<sup>[9]</sup>

These tumors may arise from the craniospinal meningeal layers, blood vessels, muscle, cartilage, or the bones lying in proximity. Within the central nervous system they are postulated to arise from heterotopias, multipotent mesenchymal cells, dedifferentiation of mesenchymal cells, or from teratomas of the CNS.

On MRI, they appear iso- to hypointense on T1W and hyperintense on T2W, are poorly defined and show heterogeneous enhancement on contrast. However, there are no features that distinguish them from other primary or secondary neoplasms of the brain.<sup>[3]</sup>

A characteristic feature on genetic analysis in embryonal rhabdomyosarcoma is the loss of heterozygosity (LOH) of 11p15.5.<sup>[10]</sup> A favorable feature is the presence of hyperploidy in embryonal RMS, which bestows a better survival compared to diploidy in patients with non-metastatic RMS.<sup>[11]</sup> The main aim at surgery is gross total tumor excision, following which the patient is subjected to radiation of the tumor bed and the craniospinal axis, and chemotherapy. Radiation therapy

remains the adjuvant of choice with a dose and fractionation similar to that used in malignant gliomas, though there are no treatment protocols defined for intracranial RMS. Relatively good results were reported after the administration of vincristine, actinomycin D and cyclophosphamide (VAC) or ifosfamide, carboplatin, and etoposide (ICE).<sup>[6]</sup> Despite these modalities, the prognosis remains bleak with an overall survival of less than 12 months.<sup>[3,5,12]</sup>

## Conclusions

PIRMS is an unusual tumor of the cerebellopontine angle. It affects children and has a rapidly progressing course, often presenting with early signs of raised intracranial pressure. Treatment consists of complete excision followed by adjuvant radiotherapy and chemotherapy. In children, lesions of the cerebellopontine angle with a rapid course and an unusual pathological appearance during surgery should evoke suspicion of rare tumors like a PIRMS.

## Financial support and sponsorship

Nil.

## Conflicts of interest

There are no conflicts of interest.

## References

- Oliveira AM, Scheithauer BW, Salomao DR, Parisi JE, Burger PC, Nascimento AG. Primary sarcomas of the brain and spinal cord: A study of 18 cases. *Am J Surg Pathol* 2002;26:1056-63.
- Paulus W, Slowik F, Jellinger K. Primary intracranial sarcomas: Histopathological features of 19 cases. *Histopathology* 1991;18:395-402.
- Celli P, Cervoni L, Maraglino C. Primary rhabdomyosarcoma of the brain: Observations on a case with clinical and radiological evidence of cure. *J Neurooncol* 1998;36:259-67.
- Drochko EJ, Allen JC. Primary intracranial rhabdomyosarcoma: Case report and review of the literature. *J Neurooncol* 1987;5:139-50.
- Taratuto AL, Molina HA, Diez B, Zuccaro G, Monges J. Primary rhabdomyosarcoma of brain and cerebellum. Report of four cases in infants: An immunohistochemical study. *Acta Neuropathol* 1985;66:98-104.
- Tomei G, Grimoldi N, Cappricci E, Sganzerla EP, Gaini SM, Villani R, et al. Primary intracranial rhabdomyosarcoma: Report of two cases. *Child Nerv Syst* 1989;5:246-9.
- Parham DM, Ellison DA. Rhabdomyosarcomas in adults and children: An update. *Arch Pathol Lab Med* 2006;130:1454-65.
- Pirillo V, Cipriano Cecchi P, Tripodi M, Maier K, Rizzo P, Schwarz A. Primary cerebral alveolar rhabdomyosarcoma in adult. *Rare Tumors* 2011;3:E26.
- Parham DM. Pathologic Classification of Rhabdomyosarcomas and Correlations with Molecular Studies. *Mod Pathol* 2001;14:506-14.
- McManus AP, Gusterson BA, Pinkerton CR, Shipley JM. The molecular pathology of small round-cell tumours-relevance to diagnosis, prognosis, and classification. *J Pathol* 1996;178:116-21.
- Pappo AS, Crist WM, Kuttesch J, Rowe S, Ashmun RA, Maurer HM, et al. Tumor-cell DNA content predicts outcome in children and adolescents with clinical group III embryonal rhabdomyosarcoma. The Intergroup Rhabdomyosarcoma Study Committee of the Children's Cancer Group and the Pediatric Oncology Group. *J Clin Oncol* 1993;11:1901-5.
- Guilcher GMT, Henderson G, Goddard K, Steinbok P, Bond M. Successful treatment of a child with a primary intracranial rhabdomyosarcoma with chemotherapy and radiation therapy. *J Neurooncol* 2008;86:79-82.