

CASE REPORT

Unusual site of Rathke's cleft cyst: A case report and review of literature

Vivek Agarwal, Deepak Palande, Vernon Velho, Rachana S. Binayke

Department of Neurosurgery, Grant Medical College and Sir Jamshedjee Jeejeebhoy Group of Hospitals, Byculla, Mumbai, Maharashtra, India

ABSTRACT

We report an eight years female child of symptomatic giant Rathke's cleft cyst extending from right parasellar, paraventricular region to right fronto-temporo-parietal cortical surface which is an unusual site for Rathke's cyst. MRI Brain scans of patient who presented with diminution of vision in right eye with headache and vomiting revealed a large cystic mass in right parasellar, paraventricular region with peripheral enhancement and midline shift. In this case, we performed the right fronto-temporo-parietal craniotomy with drainage and marsupialization of cyst wall. Histopathologically, it was inflamed Rathke's cleft cyst with focal epithelial metaplasia.

Key words: Rathke cleft cyst, site, unusual

Introduction

Rathke's cleft cyst is a nonneoplastic epithelial-lined cyst which develops around the sella turcica. It is derived from the remnant of the Rathke's cleft in the intermediate lobe of the pituitary gland.^[1,2] This is lined by single layer of cuboidal/columnar epithelium or rarely with pseudostratified squamous epithelium.

These are usually small and asymptomatic, rarely become large enough to cause symptoms. Till now, only 155 cases of symptomatic Rathke's cleft cyst have been reported, of which 11 cases are suprasellar Rathke's cleft cyst with normal sella, but cases of parasellar, paraventricular Rathke's cleft cyst are distinctly uncommon and we have not found it reported in literature yet. We present a rare case of parasellar, paraventricular giant Rathke's cleft cyst.

Case Report

An 8-year-old female child was referred to our department

due to diminution of vision in right eye since 5 years, with headache and vomiting since 6 months. On examination, patient has no perception of light in right eye with normal vision in left eye. Right eye fundus examination revealed optic atrophy with left eye papilledema. Investigations with magnetic resonance imaging (MRI) showed a cystic lesion at right temporo-frontal-parietal region measuring $8 \times 9 \times 6.5$ cm with small rounded nodule seen on medial aspect of the cystic lesion at paraventricular location lesion, which was hypointense on T1W, hyperintense on T2W and FLAIR images, postcontrast study revealed strong peripheral enhancement with enhancement of the nodule [Figure 1a-c]. The lesion was reported as cystic astrocytoma/ganglioglioma. Endocrine work up done subsequently was s/o secondary hypothyroidism. Patient underwent right fronto-temporo-parietal craniotomy with drainage and marsupialisation of the cystic lesion [Figure 2]. The cyst wall was thin and flimsy, extending from surface of the brain to paraventricular structures (thalamus, fornix) and was well-demarcated. Cystic fluid was yellowish, machine oil-like containing cholesterol crystal and flecks mostly over the medial side [Figure 3]. Histological examination revealed inflamed Rathke's cleft cyst with cystic wall lined by flatten

This is an open access article distributed under the terms of the Creative Commons Attribution-NonCommercial-ShareAlike 3.0 License, which allows others to remix, tweak, and build upon the work non-commercially, as long as the author is credited and the new creations are licensed under the identical terms.

For reprints contact: reprints@medknow.com

Access this article online	
Quick Response Code:	Website: www.asianjns.org
	DOI: 10.4103/1793-5482.150003

Address for correspondence:

Dr. Vivek Agarwal, Fellow, Department of Interventional Neuroradiology, Zurich University Hospital, Switzerland.
E-mail: neuro.vi@gmail.com

How to cite this article: Agarwal V, Palande D, Velho V, Binayke RS. Unusual site of Rathke's cleft cyst: A case report and review of literature. Asian J Neurosurg 2017;12:44-6.

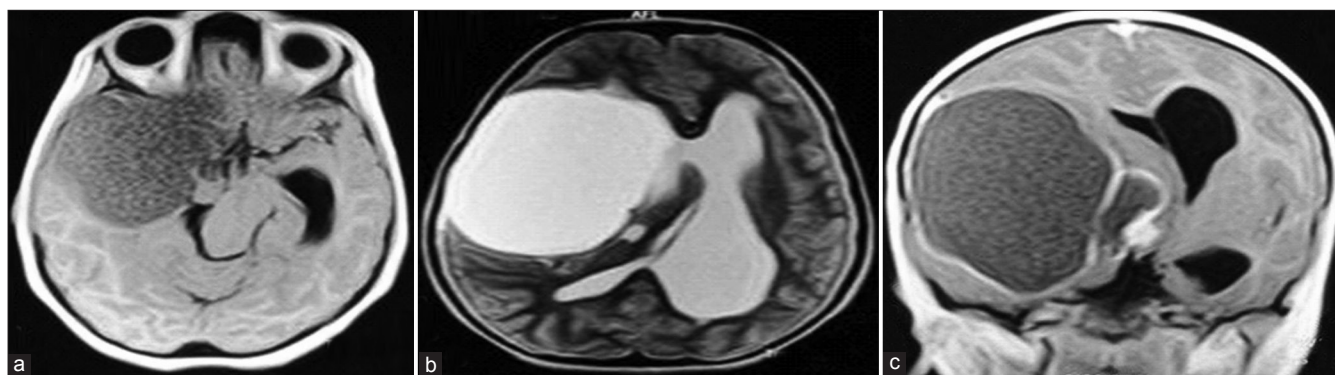


Figure 1: (a) MR T1W axial, (b) MR T2W axial, and (c) MR T1W axial contrast

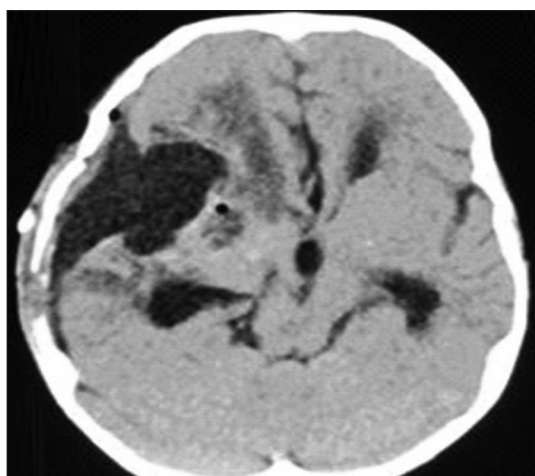


Figure 2: Postoperative CT scan

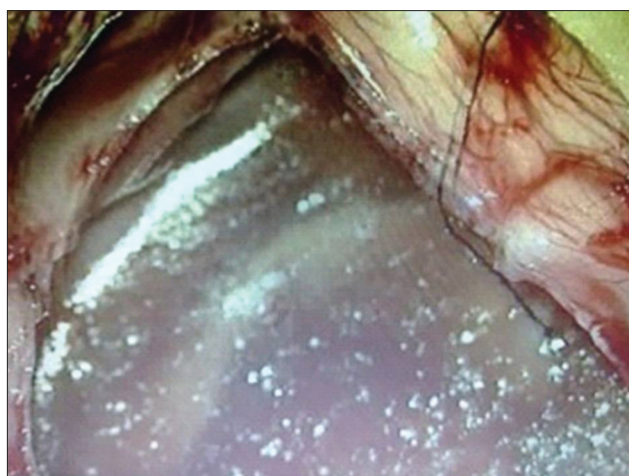

Figure 3: Intraoperative images: Cyst with cholesterol flecks

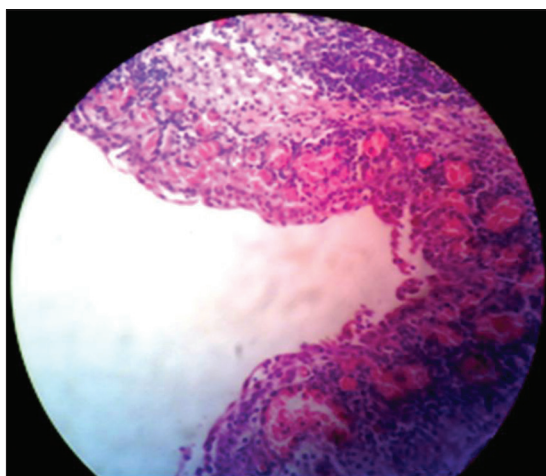


Figure 4: Low power field histopathological images

to pseudostratified squamous lining epithelium with congested blood vessel, chronic inflammatory infiltrate in form of lymphocyte, plasma cell, and lymphoid aggregates [Figure 4]. Postoperative patient recovery was uneventful and her headache, vomiting was recovered completely. Patient is in regular follow-up with postoperative MRI at 6 months without any recurrence.

Discussion

The incidence of the Rathke's cleft cyst has not been clear because most of Rathke's cleft cysts are asymptomatic.^[3] The incidence and the number of surgical cases have increased recently due to the advent of MRI. Embryologically, it develops from remnant of Rathke's pouch. Barrows *et al.*, suggested that Rathke's pouch remnant may coexist with anterior pituitary tissue located above the diaphragm. Under these conditions, remnants of Rathke's cleft found above diaphragm sella may give rise to suprasellar and parasellar Rathke's cleft cyst. Isono *et al.*,^[4] proposed that neuroepithelium may pinch off to form ependymal lined tubules within the gland and around stalk. The concept would account for mechanism of development of Rathke's cyst outside the sella as in our case. Third concept is of origin from endodermal cell by metaplasia. The histological picture of Rathke's cleft cyst and craniopharyngioma differs greatly, even though they might have common origin. Histologically, Rathke's cleft cysts consist of a single or pseudostratified epithelium with an underlying layer of connective tissue. The epithelium may contain ciliated, goblet, and squamous cells, whereas craniopharyngioma has either adamantinomatous or squamous stratified epithelium invading surrounding brain parenchyma,

nodule formation, keratin formation, calcium deposit, chronic inflammation, and hyaline granule layers. Rathke's cleft cysts are most often small and asymptomatic; occasionally, they may become large enough to cause symptoms by compression of intrasellar and suprasellar structures. The lesion may become symptomatic in children but most reported cases have been in adults. Rathke's cleft cyst are more common in female by 2:1 margin, the most common presenting symptom are pituitary dysfunction, visual field defect, and headache. Hypopituitarism is most common hormonal abnormality followed by hyperprolactinemia. Aseptic meningitis and pituitary apoplexy are rarely reported.^[5]

Radiologically, they are located in the midline in and above the anterior portion of the sella turcica with well-defined margin rounded or lobular. Pituitary stalk and gland are usually displaced posterior. Computed tomography (CT) and MRI vary according to morphology of the cyst wall and content of the cyst. These are noncalcified cystic lesion that is important feature that differentiate it from cystic craniopharyngioma. When the cyst lining is of single layer cuboidal or columnar epithelium, it is not clearly seen on imaging studies; however, when stratified squamous epithelium is present or if inflammation occurs in cyst wall enhancement occur on postcontrast studies as in our case. CT scan typically shows an enlarged sella turcica containing a cystic mass, which can be hypodense or isodense with brain.^[6,7]

Only symptomatic Rathke's cleft cyst cases require treatment and cyst drainage with marsupialization of cyst is appropriate as recurrence rate of these cyst is very low. Radical excision may result in hypopituitarism and damage to sellar/suprasellar structures. Since aim is to achieve drainage and

marsupialization, these cysts are commonly operated on by transphenoidal route because of low morbidity of this approach.^[8] In our case, we have done fronto-temporo-parietal craniotomy with drainage and marsupialization of cyst wall as the lesion was parasellar and paraventricular rather than sellar/suprasellar. Postoperative adjuvant radiation is also not required as recurrence is very low so just regular follow-up with MRI will suffice.

Financial support and sponsorship

Nil.

Conflicts of interest

There are no conflicts of interest.

References

1. Aho CJ, Liu C, Zelman V, Couldwell WT, Weiss MH. Surgical outcomes in 118 patients with Rathke cleft cysts. *J Neurosurg* 2005;102:189-93.
2. Harrison MJ, Morgello S, Post KD. Epithelial cystic lesions of the sellar and parasellar region: A continuum of ectodermal derivatives? *J Neurosurg* 1994;80:1018-25.
3. Hirano A, Hirano M. Benign cysts in the central nervous system: Neuropathological observations of the cyst walls. *Neuropathology* 2004;24:1-7.
4. Isono M, Kamida T, Kobayashi H, Shimomura T, Matsuyama J. Clinical features of symptomatic Rathke's cleft cyst. *Clin Neurol Neurosurg* 2001;103:96-100.
5. Wenger M, Simko M, Markwalder R, Taub E. An entirely suprasellar Rathke's cleft cyst: Case report and review of the literature. *J Clin Neurosci* 2001;8:564-7.
6. Mnif N, Hamrouni A, Iffenecker C, Oueslati S, Fruexer F, Doyon D, *et al.* MRI in the diagnosis of Rathke's cleft cyst. *J Radiol* 2003;84:699-704.
7. Ross DA, Norman D, Wilson CB. Radiologic characteristics and results of surgical management of Rathke's cysts in 43 patients. *Neurosurgery* 1992;30:173-8.
8. Lee CH, Seo EK, Cho YJ, Kim SJ. Large ossified Rathke's cleft cyst: A case report and review of the literature. *J Korean Neurosurg Soc* 2008;44:256-8.