

# Management of superior sagittal sinus injury encountered in traumatic head injury patients: Analysis of 15 cases

Sanjay K. Behera, Satya Bhusan Senapati, Sudhansu Sekhar Mishra, Srikant Das

Department of Neurosurgery, S.C.B. Medical College and Hospital, Cuttack, Odisha, India

## ABSTRACT

**Background:** Significant dural sinus injury occurs in 1.5- 5% of all head injuries and injury to superior sagittal sinus accounts for 70-80% of these. Its management is also a challenging issue to every neurosurgeon.

**Materials and Methods:** In a period of one year (Aug 2011 to July 2012) out of 549 cases of head injuries operated in our department analysis of 15 cases (2.73%) shown to have superior sagittal sinus injury. Three dimensional reconstruction of skull bone during CT scan helped us to diagnose possible dural sinus injury pre-operatively.

**Results:** SSS injury was due to direct impact of fracture segment (5 cases), extension of fracture line over sinus area (4 cases) or due to coronal suture diastases (6 cases). Injury to anterior third of sagittal sinus occurred in 12 cases (80%) and injury to middle third occurred in 3 cases (20%). Small tear over superior sagittal sinus was found in 7 cases (46.66%) and was managed with Gelfoam® compression only and in two cases (13.33%) were large tear, which was managed with sinoraphy. In four cases (36.34%) hitch stitches over Gelfoam® to adjacent bone given and in rest two cases (13.33%) a strip of bone was left over the sinus area and bilateral hitch stitches were applied.

**Conclusion:** Injury to SSS in traumatic head injury patient though rarely encountered during surgery, the management is challenging to every neurosurgeon. Preoperative suspicion and combination of surgical techniques rather than one single technique may be effective in decreasing the sinus related mortality rate.

**Key words:** Depressed fracture, dural sinus injury, superior sagittal sinus injury

## Introduction

Significant dural sinus injury occurs in 1.5–5% of all head injuries and injury to superior sagittal sinus (SSS) accounts for 70–80% of these. The clinical presentations of patients with significant venous sinus injury vary with both mechanism and location of injuries. Since Cushing's review of 219 military head injuries in World War I,<sup>[1]</sup> containing 14 cases of dural sinus injury with a mortality rate of 79%, repair of dural

sinus injury became a challenge to every neurosurgeon. General surgeons are usually afraid of dural sinus injuries; therefore, we consider knowledge of the incidence together with appropriate methods of treatment being essential in the overall management of such injuries.

## Materials and Methods

In a period of 1-year (August 2011 to July 2012) of 549 cases of head injuries operated in our department analysis of 15 cases (2.73%) shown to have SSS injury encountered intraoperatively. Road traffic accident was the cause in 11 cases (73.34%), assault in 3 cases (20%) and fall of a heavy object overhead in 1 case (6.67%). All the patients are initially investigated with computed tomography (CT) scan with three-dimensional reconstruction, routine hemogram and coagulation studies. A possible SSS injury was suspected in all cases with vertex epidural hemorrhage (EDH) with coronal suture diastases [Figure 1] and in patients with fracture line extending to sinus area and with depressed fracture over midline [Figures 2 and 3]. Those patients who were planned for surgery are prepared with an extra unit of blood and fresh frozen plasma.

Access this article online	
Quick Response Code:	Website: www.asianjns.org
	DOI: 10.4103/1793-5482.151503

### Address for correspondence:

Dr. Satya Bhusan Senapati, Department of Neurosurgery, S.C.B. Medical College and Hospital, Cuttack - 753 007, Odisha, India.  
E-mail: satya.bhusan.senapati@gmail.com

## Results

In total 15 cases injury to anterior third of sinus occurred in 12 cases (80%) and injury to middle third occurred in 3 cases (20%). Table 1 shows SSS injury was due to direct impact of fracture segment in 5 cases (33.33%), extension of fracture line over sinus area in 4 cases (26.67%) and due to coronal suture diastases in 6 cases (40%). The mean Glasgow coma scale at the time of admission was 13.34 and mean Hb% was 8.62 g%. Intraoperative blood loss was found to be between 500 ml and 800 ml and mean intraoperative blood transfusion was 1.8 units.

There occurred significant amount of bleeding in all cases. In four cases with vertex EDH managed with fronto-parietal craniotomy extending to either side of midline and hence that sinus injury was dealt under direct vision [Figure 4], but in 2 cases we performed bilateral fronto-parietal craniotomy leaving a strip of bone in midline over the SSS area so that bilateral hitch stitches over gel foam was given to control bleeding from sinus [Figure 5]. In two cases with depressed fractures over sinus area with large sinus tear, circumferential craniectomy was done extending to either side of sinus area and direct suture repair of sinus was done, which was further reinforced with muscle patch [Figure 6].

On summarizing small tear over SSS was found in 7 cases (46.66%) and was managed with head elevation and compression with Gelfoam® and in two cases (13.33%) were large tear, which was managed with sinoraphy. In four cases (36.34%) hitch stitches over Gelfoam® to adjacent bone given and in rest two cases (13.33%) a strip of bone was left over the sinus area and bilateral hitch stitches were applied [Table 2].

**Table 1: Mode of sinus injury**

Source of sinus injury	Number of patient (%)	CT finding	Mortality
Direct impact of fractured bone	05 (33.33)	Fracture hematoma With or without Contusion	Nil
Extension of fracture line to sinus area	04 (26.67)	Extradural hematoma Adjacent to sinus area	Nil
Coronal suture diastases	06 (40.00)	Vertex extradural Hematoma	Nil

CT – Computed tomography

**Table 2: Operative techniques used for management of sinus injury**

Technique	Blood loss (ml)	Number	Percentage
Gelfoam® compression only	500-600	07	46.67
Hitch stitches over Gelfoam®	500-600	04	36.67
Bilateral hitch stitches over Gelfoam®	400-500	02	13.33
Sinoraphy	600-700	02	13.33

In this study, we found that preoperative suspicion of injury to SSS helped us to deal with the sinus injury more precisely and to improve the outcome. Successful sinus repair done in all cases, and there was nil mortality.

## Discussion

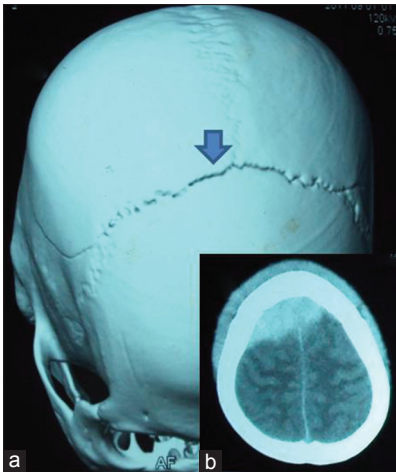
Lacerations of the dural sinuses are common in wartime. Significant dural sinus injury occurred in 1.5–5% of all severe head injured patients. Cushing’s review of 219 military head injuries from World War I contained 14 cases of injury to one or more dural sinus with a subsequent mortality of 79%.<sup>[1]</sup> The incidence found to be 43% in the series by Cairn’s *et al.* in World War II. Meierowsky reviewed 100 cases of dural sinus injury, emphasized the need for wide proximal and distal control of damaged sinus, described repair techniques using Gelfoam, muscle strips and silk sutures and reported mortality of 12% only.<sup>[2]</sup>

Techniques for the repair of the dural sinuses have been well described. A full complement of vascular instruments should be available when undertaking sinus repair. The first step in the repair involves hemostasis. Temporary hemostasis usually achieved by compressing cottonoid over Gelfoam® while elevating the head (reverse Trendelenburg position), because of the risk of air embolism during sinus repair. A central line in the right atrium and Doppler echocardiography is required, and use of positive end-expiratory pressure helps prevent air from entering the venous system.

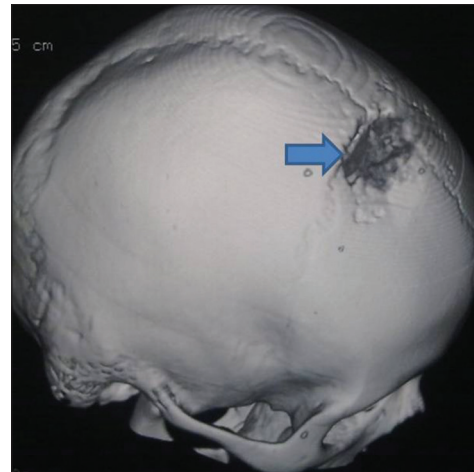
The clinical presentations of patients with significant venous injury vary with both mechanism and location. These patients suddenly deteriorate when the unwary surgeon moves tamponading bone fragments resulting in massive hemorrhage and air embolism. If a venous sinus injury is suspected initial goal is avoidance of exsanguinations. Large lacerations should be closed immediately. Packing with saline soaked gauze may decrease chances of air embolism.

Coagulation studies must be obtained during the perioperative period because coagulopathy usually occurs due to massive transfusion after significant blood loss. Thrombocytopenia occurs in 85% cases and defibrination in 69% cases. Hence, arrangements for fresh frozen plasma or platelet concentrate should be done before surgery. CT scan is valuable initial investigation, and a plain skull film may be valuable for diagnosis. Three-dimensional reconstruction of the skull bone in our study was used because it better delineates the possible involvement of sinus injury. Angiography is useful and should be performed if possible preoperatively or during surgery in case of sinus injury.

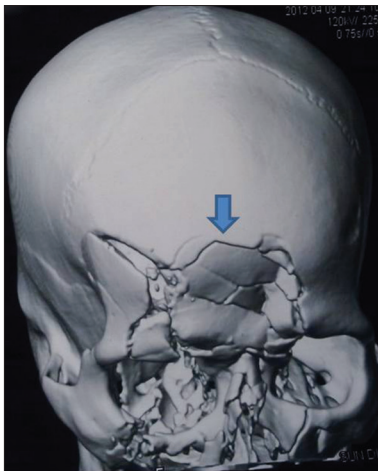
The incision should provide generous exposure of all bone fragments and surrounding calvarium. Furthermore, exposure of sinus both proximally and distally to the site



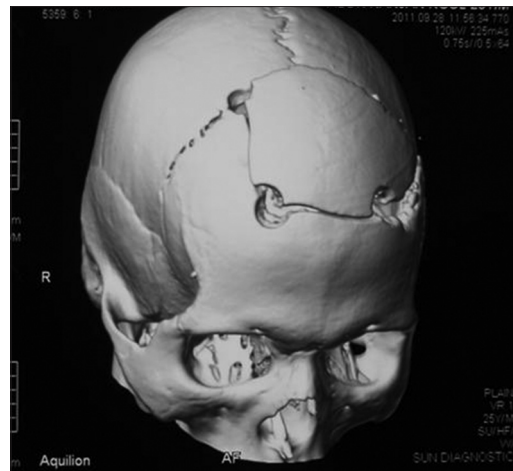
**Figure 1:** Computed tomography scan picture showing vertex epidural hemorrhage (b) with coronal suture diastases (a)



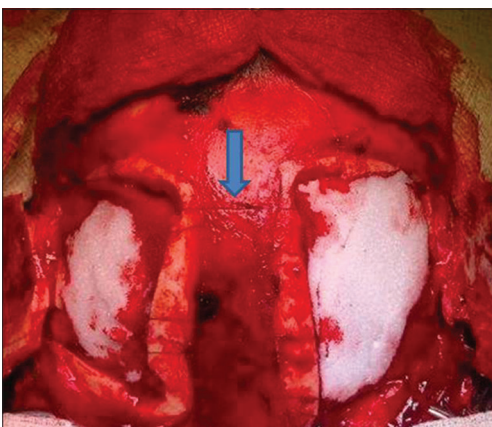**Figure 2:** Three-dimensional computed tomography scan showing depressed fracture over midline over superior sagittal sinus



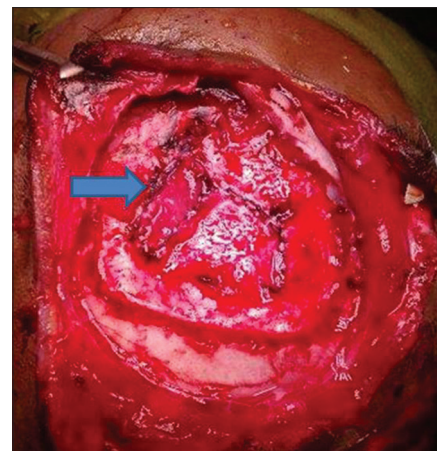
**Figure 3:** Three-dimensional computed tomography scan showing comminuted depressed fracture over anterior part of superior sagittal sinus area



**Figure 4:** Postoperative Three-dimensional scan showing burrhole sites for managing vertex extradural hematoma



**Figure 5:** Intra-operative photograph showing bilateral frontoparietal craniotomy leaving a strip of bone over midline and bilateral hitch stitches for control of sinus bleeding



**Figure 6:** Intraoperative photograph after repair of sinus tear by continuous suturing and reinforced with muscle patch

of injury is important. Bone flap should extend well beyond the edge of any fracture, which will require craniectomy on both sides of sinus and care must be taken to avoid further

injury.<sup>[3]</sup> Digital pressure on a sheet of Gelfoam® covered with cottonoid will temporarily control sinus bleeding. Fogarty catheter may be introduced to each end of the sinus

and inflated for temporary control of bleeding. The sagittal sinus can be safely ligated in its anterior end and should be repaired in middle and posterior end. Depressed fracture with sharp bony spicule overlying major sinus can result in major bleeding from sinuses,<sup>[4]</sup> which can be treated by head end elevation and compression by Gelfoam®. Stay sutures should be used to hold Gelfoam® compressed against venous sinuses.<sup>[5]</sup> Autologous venous graft can give good results in repair of dural venous sinuses.<sup>[6,7]</sup> If the wall of the laceration is smooth, without any loss of dural wall, a continuous suture is used to close the sinus. The sutured laceration is then reinforced by Gelfoam® or muscle.<sup>[8]</sup>

## Conclusion

Injury to SSS in traumatic head injury patient though rarely encountered during surgery, the management is challenging to every neurosurgeon. Preoperative suspicion and combination of surgical techniques rather than one single technique may be effective in decreasing the sinus related mortality rate.

## References

1. Cushing H. A study of series of wounds involving the brain and its enveloping structures. *Br J Surg* 1918;5:558-684.
2. Meirowsky AM. Wounds of dural sinuses. *J Neurosurg* 1953;10:496-514.
3. Ozer FD, Yurt A, Sucu HK, Tektas S. Depressed fractures over cranial venous sinus. *J Emerg Med* 2005;29:137-9.
4. Bonnal J, Buduba C. Surgery of the central third of the superior sagittal sinus. Experimental study. *Acta Neurochir (Wien)* 1974;30:207-15.
5. Datta SG, Ch M. Bilateral vertex extradural hematomas: A case report. *Indian J Neurotrauma* 2008;5:109-11.
6. Rish BL. The repair of dural venous sinus wounds by autogenous venorrhaphy. *J Neurosurg* 1971;35:392-5.
7. Tanaka H, Tanaka H, Kobata H. Superior sagittal sinus occlusion caused by a compound depressed skull fracture: A case treated by emergency surgery. *No Shinkei Geka* 2004;32:753-8.
8. Huang SQ. Surgical treatment of intracranial venous sinus injury. A report of 111 cases. *Zhonghua Wai Ke Za Zhi* 1989;27:166-8, 190.

**How to cite this article:** Behera SK, Senapati SB, Mishra SS, Das S. Management of superior sagittal sinus injury encountered in traumatic head injury patients: Analysis of 15 cases. *Asian J Neurosurg* 2015;10:17-20.

**Source of Support:** Nil, **Conflict of Interest:** None declared.

## Announcement

### iPhone App



Download  
**iPhone, iPad  
application**

FREE

A free application to browse and search the journal's content is now available for iPhone/iPad. The application provides "Table of Contents" of the latest issues, which are stored on the device for future offline browsing. Internet connection is required to access the back issues and search facility. The application is Compatible with iPhone, iPod touch, and iPad and Requires iOS 3.1 or later. The application can be downloaded from <http://itunes.apple.com/us/app/medknow-journals/id458064375?ls=1&mt=8>. For suggestions and comments do write back to us.