

CASE REPORT

Primary intracranial malignant melanoma: A rare case with review of literature

Vijayalaxmi V. Suranagi, Praful Maste, Prakash R. Malur

Department of Pathology, J N Medical College and KLEs Dr. Prabhakar Kore Hospital and MRC, Belgaum, Karnataka, India

ABSTRACT

We present a rare case of the primary intracranial melanoma in the right parafalcine frontal region in a 65-year-old male. Computed tomography and magnetic resonance imaging showed a Space occupying lesion in the right parafalcine frontal region with necrosis, vasogenic edema and mass effect. A rather well-defined, dark brown-black tumor was totally removed and histologically diagnosed as malignant melanoma. The patient improved after surgery. In our case, no systemic melanomas were found in close clinical examinations, there was a single nodular tumor attached to the leptomeninges and a favorable outcome was obtained by surgical treatment alone. Primary central nervous system melanomas have rarely been reported, and this case is reported for its rarity.

Key words: Frontal, magnetic resonance imaging, melanoma, primary brain tumor

Introduction

Malignant melanomas commonly develop in the skin, mucosa, and eye regions.^[1] Since melanocytes are considered to originate from neural crest and are found in normal leptomeningeal tissue it is not surprising that primary melanomas also grow within the central nervous system (CNS). However, primary CNS melanomas have rarely been reported, We report a case of the primary intracranial melanoma in the right parafalcine frontal region, which was diagnosed by histological examination of the excised mass.

Case Report

A 65-year-old male presented with history of headache, giddiness and loss of balance during walking for the past 4 months. Computed tomography (CT) scan showed a well-defined lesion measuring 1.8 cm × 1.5 cm with broad base toward anterior falx, perilesional edema. Clinically meningioma was suspected. However, patient refused surgery.

He presented 4 months later, with a history of seizures, altered sensorium and hemiparesis. He was put on anti-convulsants. A repeat CT was done, which now showed an ill-defined intraaxial mass lesion measuring 6 cm × 5 cm × 4.2 cm in the right parasagittal frontal region extending beyond midline into left side with significant perilesional edema. Contrast revealed peripheral nonuniform ring enhancement with areas of heterogeneity and significant mass effect on corpus callosum [Figure 1]. Magnetic resonance imaging was done, which showed a SOL in the right parafalcine frontal region with necrosis, vasogenic edema and mass effect. Clinically and radiologically a high-grade glioma was suspected. Right frontal parasagittal craniotomy was performed.

Intraoperatively a large irregular brownish-black colored mass was present in the right frontal region extending onto the opposite side. The mass was well-demarcated without infiltration into the surrounding tissue enabling complete excision of the lesion. However, the peritumoral tissue was edematous. The tissue was sent to the surgical pathology laboratory.

Macroscopic findings-received multiple brownish irregular soft tissue pieces.

Microscopic examination revealed a neoplasm exhibiting a solid, nesting, and papillary pattern with areas of hemorrhage and necrosis and invasion into the brain parenchyma. The cells exhibited prominent nucleoli and brown pigment in the cytoplasm [Figures 2 and 3]. Dopa oxidase reaction was positive. The tumor cells exhibited positivity for HMB-45, S-100 and Vimentin. A diagnosis of malignant melanoma was offered.

Access this article online

Quick Response Code:



Website:

www.asianjns.org

DOI:

10.4103/1793-5482.151508

Address for correspondence:

Dr. Vijayalaxmi Suranagi, H No. 75, Near Vitthalai temple, Vaibhavnagar I Cross, Belgaum.-590010, Karnataka, India
E-mail: madhudhori@rediffmail.com

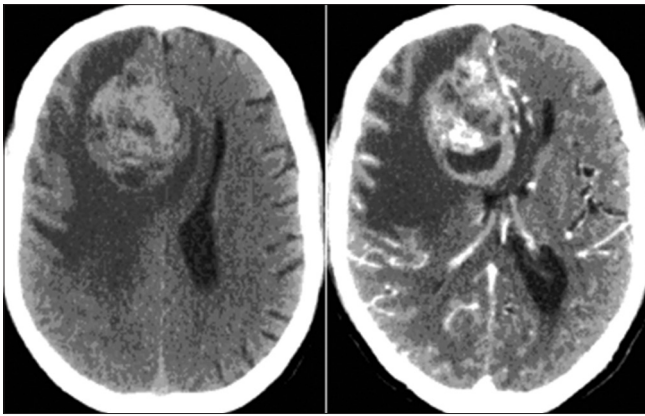


Figure 1: Computed tomography scan of brain (plain and contrast)

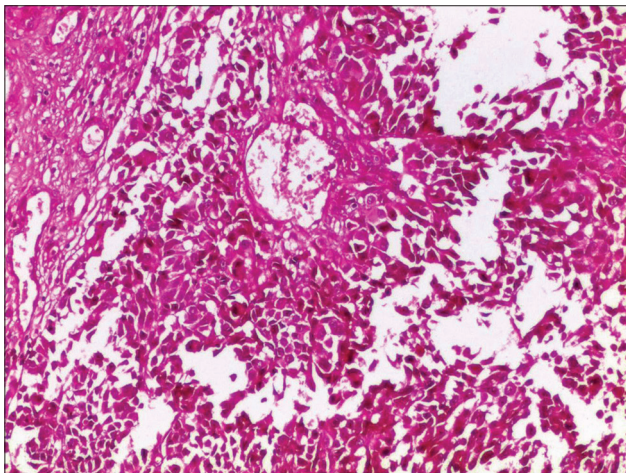


Figure 2: Round to polygonal tumor cells in diffuse sheets papillae (H and E, ×200)

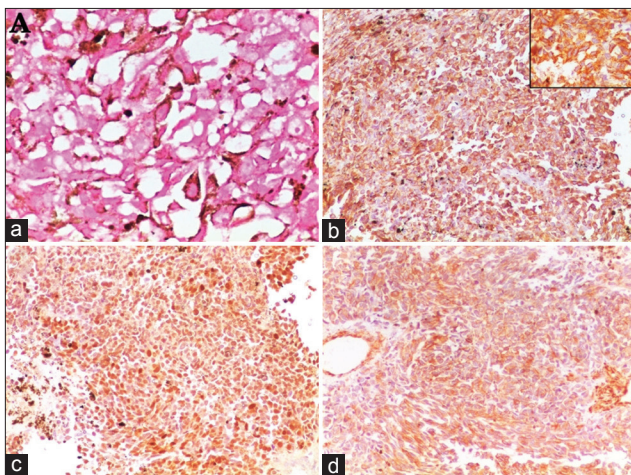


Figure 3: Cells showing positivity for (a) DOPA; (b) HMB-45; (c) S-100; (d) Vimentin

A thorough search was made for a primary lesion in the other probable sites such as skin, mucus membrane, eyes and lower gastrointestinal tract, which yielded negative results which confirmed that this was a primary melanoma occurring in the right parafalcine frontal region of the brain.

Discussion

Since systemic melanomas frequently metastasize to the CNS, a definitive diagnosis of primary CNS melanoma can be made if no systemic focus considered to be primary is found. Terao *et al.*,^[2] reported clinical differences between metastatic and primary melanomas in the CNS. Metastatic melanomas are characterized by (1) multiple intracerebral tumors, (2) a rapid, poor clinical course due to systemic metastases, and (3) development in older Patients, while primary CNS melanomas unusually metastasize to systemic organs and develop in relatively younger patients (usually under 50 years old). Our patient had no systemic melanomas found by clinical examination, and there was a solitary mass.

The preoperative diagnosis of primary CNS melanoma is difficult, except in cases associated with neurocutaneous melanosis or when melanin or melanin-containing cells are detected in the cerebrospinal fluid. The CT findings of intracranial melanomas are not specific. On the other hand, recent magnetic resonance studies have demonstrated characteristic features of melanomas. Primary intracranial melanoma need to be distinguished from other pigmented CNS tumors, particularly meningeal melanocytoma (posterior cranial fossa, tight cellular nests or whorls).

On the review of the literature, we found 19 previously reported cases of primary intracranial malignant melanoma. Table 1 includes the details of those cases.

We reviewed 19 cases reported over a period of 25 years. [Table 1] Male predominance was noted. The tumor was frequently observed in the middle age to elderly age group. Most of the cases involved different areas of the cerebrum except for the three cases occurring in the cerebello-pontine angle. The presenting symptoms were headache, ocular symptoms, hemiparesis, and seizures. Six patients showed recurrence mostly within 18 months, except in one case where the tumor recurred after 23 years. Excision of the tumor was possible in A total of 14 cases while others were given adjuvant chemotherapy and radiotherapy. Five patients died within 1-year, while one patient survived for 17 years. Extension with metastasis was present in three cases. In our case, the age, sex and the symptoms were similar to the majority of the cases reported. However, our case did not receive chemotherapy or radiotherapy and did not show recurrence or metastasis.

Since melanomas are not radiosensitive, chemotherapy is important in the treatment of systemic melanomas. In contrast to these systemic melanoma cases, several patients with a primary CNS melanoma have achieved better outcomes by surgical intervention with or without additional treatment. The biological behavior of tumor cells of primary CNS melanomas may differ from those of systemic melanomas.

Table 1: Review of 19 cases reported previously between 1989 and 2014

Case number	Authors	Age Sex	Site	Clinical features	Recur	Treatment	Survival follow-up	Other findings
1	Nakagawa et al., 1989. [3]	57 Male	Intracrania	Persistent headache	Thrice	Excision, chemo-immuno-radiotherapy, chemoradiotherapy..	Died after 9.6 years	Nil
2	Braga et al., 1989. [4]	72 Female	CP angle	Vertigo, progressive - deafness	-	Total excision	Died 5 th postoperative day	Nil
3	Iizuka et al., 1990. [5]	76 Male	Occipital	Progressive headache, visual disturbance	+ after 8 months	Total excision	1-year follow-up alive	Nil
4	Takano et al., 1992. [6]	34 Male	Intracrania	Headache, decreased vision	-	chemo therapy, interferon-beta	NA	Nil
5	Lee et al., 2004. [7]	66 Male	Left fronto-parietal region	Headache, right hemiparesis	-	Total excision	Died after 6 months	Nil
6	Önal et al., 2006. [8]	38 Male	Posterior fossa mass	Headache, vomiting, ataxia	+ after 17 years	Excision, adjuvant external beam irradiation, chemotherapy. and-interferon chemotherapy	17 years	Diffuse intracerebral mets at recurrence
7	Bhandari et al., 2010. [9]	29 Male	CP angle	Vertigo, headache, lower cranial nerve involvement	+ after 10 months	Subtotal excision with adjuvant radiotherapy	Died after 1-year	Nil
8	Azar et al., 2010. [10]	21 Male	Parietal	Headache, mild left hemiparesia	-	Total excision, radiotherapy and chemotherapy	1-year follow-up alive	Periorbital blue nevus
9	Shah et al., 2012. [11]	28 Female	Left temporal lobe	Headache, numbness of the left side of face and diplopia	+ after 23 years	Excision of mass	4 years alive	Nil
10	Mahajan et al., 2013. [12]	55 Female	Clivus	Headache, decreased vision, vomiting	-	Palliative chemotherapy and brain irradiation	NA	Skeletal mets
11	Ponni et al., 2014. [13]	38 Male	Left CP angle	Deviation of left eye, headache	-	Total resection, adjuvant radiation and chemotherapy	1-year follow-up alive	Cerebellar infiltration
12	Wang et al., 2014. [14]	8 patients	Intracrania	Headache, decreased vision, vomiting	1 pt- + after 16 th month	Total excision-6 Subtotal excision-2, radiotherapy-6	13.8 months follow-up: 3died, 5 alive	Nil
13	Suranagi et al. (Present case), 2014	65 Male	Right parafalcine frontal region	Headache, seizures, hemiparesis	-	Total excision	1-year follow-up, alive	Nil

CP – Cerebellopontine

References

- Smith AB, Rushing EJ, Smirniotopoulos JG. Pigmented lesions of the central nervous system: Radiologic-pathologic correlation. *Radiographics* 2009;29:1503-24.
- Terao H, Yoshimatsu N, Sano K. Intracranial melanoma. *No To Shinkei* 1968;20:991-9.
- Nakagawa H, Hayakawa T, Niiyama K, Nii Y, Yoshimine T, Mori SH. Long-term survival after removal of primary intracranial malignant melanoma. *Acta Neurochir* 1989;101:84-8.
- Braga FM, Tella Júnior OI, Ferreira A, Jordy CF. Malignant melanoma of the cerebello-pontine angle region. *Arq Neuropsiquiatr* 1989;47:496-500.
- Iizuka H, Nakamura T, Kurauchi M. Primary intracranial melanoma – Case report. *Neurol Med Chir (Tokyo)* 1990;30:698-702.
- Takano S, Saito M, Murata K, Ohbu M, Miyasaka Y, Yada K, et al. Primary intracranial melanoma: A case report. *No Shinkei Geka* 1992;20:1211-5.
- Lee CJ, Rhee DY, Heo W, Park HS. Primary leptomeningeal malignant melanoma. *J Korean Neurosurg Soc* 2004;36:425-7.
- Önal C, Ozy G, Akyürek S, Selek U, Ozyar E, Atahan L. Primary intracranial solitary melanoma: A rare case with long survival. *Turk J Cancer* 2006;36:185-7.
- Bhandari L, Alapatt J, Govindan A, Sreekumar T. Primary cerebellopontine angle melanoma: A case report and review. *Turk Neurosurg* 2012;22:469-74.
- Azar M, Kazemi F, Bahrami E, Hejazian E, Fereshtehnejad SM, Ahmadi A, et al. Meningeal melanomas associated with transforming Ota nevus to malignant melanoma: A case report. *Med J Islamic Repub Iran* 2010;24:163-8.
- Shah I, Imran M, Akram R, Rafat S, Zia K, Emaduddin M. Primary intracranial malignant melanoma. *J Coll Physicians Surg Pak* 2013;23:157-9.
- Dinesh SM, Suneetha B, Sen A. A rare case of primary malignant melanoma of clivus with extensive skeletal metastasis demonstrated on 18F-FDG PET/CT. *Indian J Nucl Med* 2013;28:234-6.
- Ponni A, Jagannatha A, Gururajachar J, Harjani R, Koushik K, Subramanian N, et al. Primary cerebello-pontine angle melanoma: A case report. *Int J Cancer Ther Oncol* 2014;2:020315.
- Wang J, Guo ZZ, Wang YJ, Zhang SG, Xing DG. Microsurgery for the treatment of primary malignant intracranial melanoma: A surgical series and literature review. *Eur J Surg Oncol* 2014;40:1062-71.

How to cite this article: Suranagi VV, Maste P, Malur PR. Primary intracranial malignant melanoma: A rare case with review of literature. *Asian J Neurosurg* 2015;10:39-41.

Source of Support: Nil, **Conflict of Interest:** None declared.