

CASE REPORT

Cervical intramedullary schwannoma mimicking a glioma

Ankush Gupta, Bijesh Ravindran Nair, Geeta Chacko¹, Sunithi Mani², Vivek Joseph

Department of Neurological Sciences, ¹Pathology and ²Radiodiagnosis, Christian Medical College, Vellore, Tamil Nadu, India

ABSTRACT

We present a case of a cervical intramedullary schwannoma (IS), which resembled a glioma on radiology. Somatic and root pain, the most common presenting complaints of IS, were lacking in our patient, and the characteristic magnetic resonance finding of an enhancing thickened nerve root in IS, was absent in our case. Preoperative diagnosis of a cervical IS is not always possible. Complete tumor resection is the ideal treatment for IS. Intraoperative frozen section can be a useful for decision making though the tumor-cord plane will ultimately decide if the tumor can be radically excised.

Key words: Cervical, intramedullary, schwannoma

Introduction

Intramedullary schwannomas (ISs) are uncommon tumors, with a good prognosis if diagnosed correctly and treated appropriately. Spinal schwannomas originate from Schwann cells and are usually intradural extramedullary in location. They form up to 30% of all spinal tumors.^[1] IS represent 0.3% of all intramedullary tumors and 1.1% of all spinal schwannomas.^[2] We report a case of cervical IS that, on radiology, was suspected to be a glioma.

Case Report

Clinical features

A 48-year-old male presented with paraesthesiae of all four limbs, progressive spastic quadriparesis and urinary urgency for 5 months. He also had numbness of the right upper limb for 3 months. His functional status was Nurick grade III. Neurological findings included wasting of bilateral arm, forearm and small muscles of the hands, spastic quadriparesis and C5 dermatome sensory level. Deep tendon reflexes were exaggerated in all four limbs with positive Babinski and Hoffmann's reflexes.

Imaging

Magnetic resonance imaging (MRI) of the cervical spine revealed a 2 cm sized, centrally located, well-defined enhancing mass at the C3–C4 level, with an inferior polar nonenhancing cyst, expanding the cord with changes in the cord signal within the entire cervical cord. On T2-weighted images, the enhancing part of the lesion was isointense. There was no separate syrinx. The differential diagnoses considered were ependymoma or astrocytoma [Figures 1 and 2].

Operative finding

C3-4 laminectomy was done, and there was a grayish intramedullary tumor in the subpial plane on the right side of the cord at the C3–C4 level, with involvement of the dorsal roots on the right side. It was very firm and vascular, with pial blood supply, and had a good plane with the surrounding cord. Hence, the tumor was radically excised. The nontumorous inferior polar cyst was opened into.

Histopathology

Histopathological examination revealed a cellular tumor composed of compact interlacing fascicles of spindle-shaped cells with oval to elongated, mildly pleomorphic nuclei with inconspicuous nucleoli and moderate amounts of eosinophilic cytoplasm with indistinct cell borders. Mitotic activity was inconspicuous. Several Verocay bodies were present. The tumor cells stained positive for S100 and were immunonegative for glial fibrillary acidic protein and epithelial membrane antigen (1:10). The histopathological features were consistent with that of a schwannoma [Figure 3].

Postoperative course and follow-up

Postoperatively, there was a reduction in the spasticity of his limbs and improvement in the hand grip strength bilaterally. There was no neurological worsening. At 1-year follow-up, there was a significant reduction in paraesthesiae and

Access this article online

Quick Response Code:



Website:

www.asianjns.org

DOI:

10.4103/1793-5482.151509

Address for correspondence:

Dr. Vivek Joseph, Department of Neurosurgery, Christian Medical College, Vellore - 632 004, Tamil Nadu, India.
E-mail: vivek.joseph@cmcvellore.ac.in

spasticity. His functional grade had improved to Nurick II and he had resumed work. The MRI spine showed no residual enhancing lesion or cyst. There was mild thinning of the cord at the operated site [Figure 4].

Discussion

Although Kernohan was recognized as the first neurosurgeon to report an IS in 1952, Penfield had reported this in 1932.^[3,4] IS are rare, accounting for 0.3% of all primary spinal cord intramedullary neoplasms.^[2] The most common location for IS is the cervical spine (63%) as in our case, followed by thoracic and lumbar levels.^[5] Earlier studies have indicated a male predominance (our patient was a male) for IS,^[5] though a recent study showed no sex predilection.^[6,7] The mean age at presentation for these tumors is 49.2 years, similar to our patient aged 48 years.^[7]

Wu *et al.*^[7] compared the clinical features of seven cases of ISs with those of patients with other intramedullary tumors

(173 ependymomas and 70 astrocytomas) admitted during the same period. They found that somatic pain and root pain were the statistically significant initial symptoms of IS compared with ependymomas ($P = 0.005$) and astrocytomas ($P = 0.019$). Symptoms of myelopathy due to sensory and motor long tract dysfunction were present in the later stages. Our patient did not have somatic or root pain, and presented with features of myelopathy.

Definitive diagnosis of IS on the basis of preoperative MR imaging is difficult.^[7,8] An intramedullary tumor with a predominant extramedullary component can be confidently diagnosed to be a schwannoma. For a pure intramedullary tumor, the only MR finding conclusively diagnostic of an IS is a thickened enhancing spinal nerve root in continuity with the tumor.^[9] This is however rarely seen and was not present in our case. Clear tumor margins, uniform enhancement, central location and presence of rostral and caudal cysts are in favor of an ependymoma.^[10,11] In our case, there was an inferior polar cyst. On the other hand, astrocytomas are usually eccentric, have ill-defined

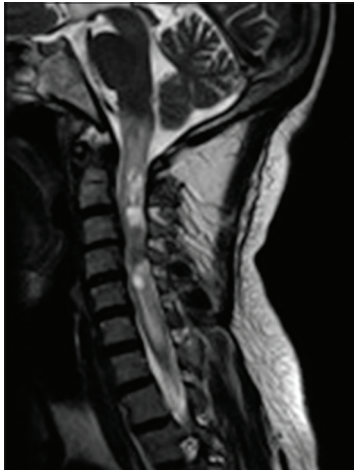

Figure 1: T2-weighted sagittal image showing hyperintense changes from cervico-medullary junction to C7-T1 level, surrounding the relatively isointense tumor at the C3/C4 level

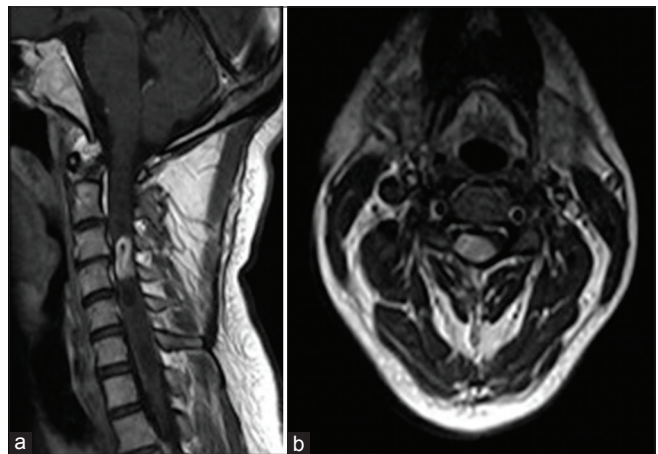


Figure 2: (a and b) Postgadolinium sagittal (a) and axial (b) images showing an intensely enhancing intramedullary mass at C3–C4 level

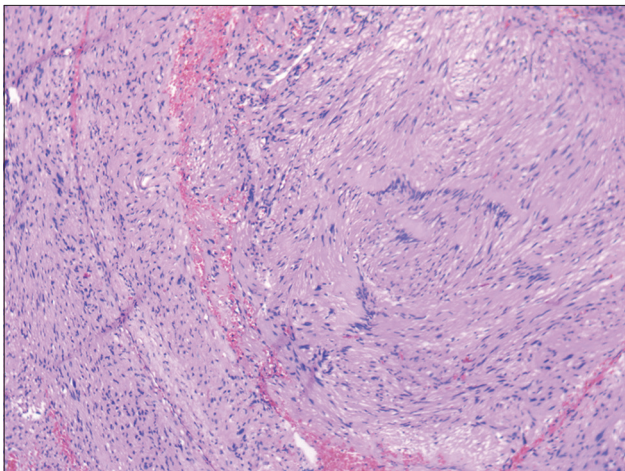


Figure 3: Histopathological examination showing a spindle cell tumor with Verocay bodies, consistent with schwannoma

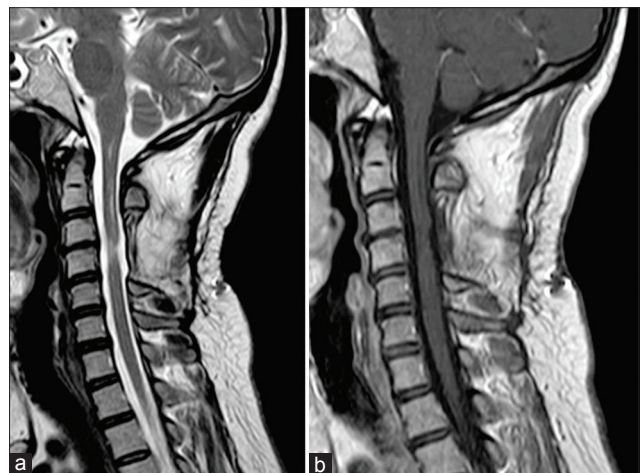


Figure 4: (a and b) One-year follow-up imaging. T2-weighted sagittal image (a) and postgadolinium sagittal image (b) showing thinning of the cord at the operated level and no residual lesion

margins due to their infiltrative nature and rarely show uniform enhancement.^[12] According to Kodama *et al.*,^[6] the characteristic imaging findings of ISs are the intense enhancement and well delineated margins on contrast-enhanced T1-weighted images – this however is not enough to differentiate from an ependymoma or hemangioblastoma. In their review, most of the IS tumors were in the cervical region, expanding the cord, accompanied by peritumoral edema, cystic cavitations, and with an exophytic component in some cases.^[6] Our case did not have an exophytic component, though extensive peritumoral edema was present [Figure 1]. MR spectroscopy of the spinal cord to differentiate between these lesions is still in experimental stages. Colosimo *et al.*^[9] have pointed out that a small to medium sized, enhancing intramedullary tumor with sharp margins and peritumoral edema should raise the suspicion of a schwannoma.

The origin of these schwannomas is controversial as there are no Schwann cells within the cord. In 1971, Russell and Rubenstein postulated that these tumors emerge from the transformation of neuroectodermal pial cells into Schwann cells.^[3] More recently,^[7] other theories put forth for the origin of these tumors are as follows: (a) From the Schwann cells in the entry zone of the dorsal root, (b) from subpial extension of the Schwann cells along the perivascular nerve plexus of spinal cord vessels or (c) from ectopic neural crest cells during embryogenesis.

Complete resection, wherever possible, is the treatment of choice for IS, as they are benign tumors with a good prognosis when excised totally.^[13] Radiation therapy as an adjuvant to surgery has no general consensus. Ogungbo *et al.* have reported the use of potassium titanyl phosphate laser in the complete resection of a sub totally excised IS, and found it superior to the ultrasonic aspirator.^[14] We used the standard cavitron ultrasonic surgical aspirator for excision of the tumor. An intraoperative frozen section could differentiate IS from other intramedullary tumors. The interpretation of intraoperative frozen section is extremely important as there have been instances where the frozen section was reported as an astrocytoma, which led the surgeons to do a subtotal excision, only to realize later in the final biopsy that the tumor was a schwannoma.^[13,14] The plane of the tumor with the spinal cord parenchyma is vital in deciding to remove intramedullary tumors radically. We did not use intraoperative frozen section

as the plane with the spinal cord parenchyma was good; therefore it was possible to resect the tumor radically with minimal cord manipulation. In cases where the plane is poor, subtotal excision can avoid neurological worsening.

References

1. Daroza AC. Primary intraspinal tumours: Their clinical presentation and diagnosis. An analysis of ninety-five cases. *J Bone Joint Surg Br* 1964;46:8-15.
2. Ross DA, Edwards MS, Wilson CB. Intramedullary neurilemmomas of the spinal cord: Report of two cases and review of the literature. *Neurosurgery* 1986;19:458-64.
3. Nicácio JM, Rodrigues JC, Galles MH, Faquini IV, de Brito Pereira CA, Ganau M. Cervical intramedullary schwannoma: A case report and review of the literature. *Rare Tumors* 2009;1:e44.
4. Penfield W. Notes on operative technic in neurosurgery. *Ann Surg* 1946;124:383-5.
5. Herregodts P, Vloeberghs M, Schmedding E, Goossens A, Stadnik T, D'Haens J. Solitary dorsal intramedullary schwannoma. Case report. *J Neurosurg* 1991;74:816-20.
6. Kodama Y, Terae S, Hida K, Chu BC, Kaneko K, Miyasaka K. Intramedullary schwannoma of the spinal cord: Report of two cases. *Neuroradiology* 2001;43:567-71.
7. Wu L, Yao N, Chen D, Deng X, Xu Y. Preoperative diagnosis of intramedullary spinal schwannomas. *Neurol Med Chir (Tokyo)* 2011;51:630-4.
8. Shenoy SN, Raja A. Cystic cervical intramedullary schwannoma with syringomyelia. *Neurol India* 2005;53:224-5.
9. Colosimo C, Cerase A, Denaro L, Maira G, Greco R. Magnetic resonance imaging of intramedullary spinal cord schwannomas. Report of two cases and review of the literature. *J Neurosurg* 2003;99:114-7.
10. Smith AB, Soderlund KA, Rushing EJ, Smirniotopolous JG. Radiologic-pathologic correlation of pediatric and adolescent spinal neoplasms: Part 1, Intramedullary spinal neoplasms. *AJR Am J Roentgenol* 2012;198:34-43.
11. Sun B, Wang C, Wang J, Liu A. MRI features of intramedullary spinal cord ependymomas. *J Neuroimaging* 2003;13:346-51.
12. Seo HS, Kim JH, Lee DH, Lee YH, Suh SI, Kim SY, *et al.* Nonenhancing intramedullary astrocytomas and other MR imaging features: A retrospective study and systematic review. *AJNR Am J Neuroradiol* 2010;31:498-503.
13. Ohtonari T, Nishihara N, Ota T, Ota S, Koyama T. Intramedullary schwannoma of the conus medullaris complicated by dense adhesion to neural tissue. *Neurol Med Chir (Tokyo)* 2009;49:536-8.
14. Ogungbo BI, Strachan RD, Bradey N. Cervical intramedullary schwannoma: Complete excision using the KTP laser. *Br J Neurosurg* 2000;14:345-8.

How to cite this article: Gupta A, Nair BR, Chacko G, Mani S, Joseph V. Cervical intramedullary schwannoma mimicking a glioma. *Asian J Neurosurg* 2015;10:42-4.

Source of Support: Nil, Conflict of Interest: None declared.