

ORIGINAL ARTICLE

Posterior fossa arachnoid cysts in adults: Surgical strategy: Case series

Uddanapalli Sreeramulu Srinivasan, Radhi Lawrence¹Departments of Neurosurgery, ¹Pathology MIOT Hospitals, Manapakkam, Chennai, Tamil Nadu, India

ABSTRACT

Introduction and Aim: The management of posterior fossa arachnoid cyst (PFAC) in adults is controversial. To review our cases and literature, propose a practically useful surgical strategy, which gives excellent long-term outcome in management of PFAC.

Materials and Methods: We analyzed our case records of 26 large intracranial arachnoid cysts in adults treated over 12 years. Of them, we had 7 patients with symptomatic PFAC. Reviewed the literature of 174 PFAC cases (1973–2012) and added 7 of our new cases with a follow-up ranging from 3 to 12 years.

Results: In 6 cases the PFAC was located in the midline. In the 7th case, it was located laterally in the cerebello-pontine (CP) angle. All patients were treated surgically. Excision of the cyst was performed in 5 of these cases. Among the two intra-fourth ventricular cysts, in both the cases cysto-peritoneal shunt was performed. Postoperative computed tomography/magnetic resonance imaging showed variable decrease in size of the cyst even though clinically all patients improved. We propose a surgical strategy for the management of these cases which would aid the surgeon in decision making.

Discussion: We observed that these PFACs can occur either in the midline within the fourth ventricle or retroclival region or extra-fourth ventricular region. It can also develop laterally in the CP angle or behind the cerebellum or as intracerebellar cyst. Importance of this is except for Midline Intra-fourth ventricular cyst/retroclival cyst, the rest all can be safely excised with excellent long term outcome. The treatment strategy for Midline Intra-fourth ventricular cyst/retroclival cyst can be either cysto-peritoneal shunt or endoscopic fenestration of the cyst.

Key words: Cysto-peritoneal shunt, endoscopic excision of cyst, excision of arachnoid cyst, intracranial arachnoid cysts, posterior fossa arachnoid cysts

Introduction

Discrete posterior fossa cerebrospinal fluid (CSF) collections that are clearly separate from the fourth ventricle and vallecule are classified as posterior fossa arachnoid cysts (PFAC).^[1,2] Arai and Sato had clearly outlined the indications for surgery in PFAC.^[3] Management strategy depends upon the size and location of these arachnoid cysts within the posterior fossa. Holst *et al.*, in

their recent article has stated that the best surgical treatment of cerebral arachnoid cysts is yet to be established.^[4] Treatment options are shunting, endoscopic fenestration or microsurgical fenestration through craniotomy.^[4]

Review of literature shows various authors have classified the arachnoid cysts.^[1,2,5] With regards to the PFAC, Little *et al.* grouped infratentorial arachnoid cysts based upon their location in the pre-magnetic resonance imaging (MRI) era^[5] while Barkovich *et al.* classification of posterior fossa cysts based upon the embryologic development^[2] helped differentiate PFAC from mega cisterna magna and Dandy-Walker malformation, but is not specific for PFAC. The optimal surgical management of PFAC still remains controversial.^[3-16] Reviewing the literature and taking into consideration the advancements made in the field of radiology like computed tomography (CT) and MRI scan, surgical techniques like endoscopy and results of long-term follow-up of our cases, we propose a surgical strategy for management of these PFAC. This would aid the surgeon in decision making regarding the best type of surgical approach to the PFAC, which is suited to include the surgeon's expertise, the availability of the neurosurgical armamentarium and would also give excellent long-term results.

Access this article online	
Quick Response Code: 	Website: www.asianjns.org
	DOI: 10.4103/1793-5482.151512

Address for correspondence:

Dr. Uddanapalli Sreeramulu Srinivasan, 3A Malavika Apartments, New No 70, 3rd Main Road, Gandhinagar, Adyar, Chennai - 600 020, Tamil Nadu, India.
 E-mail: ussrini@vsnl.net

Materials and Methods

In our center during the period 2001-2012, 26 cases of large intracranial arachnoid cysts were treated in adults. Diagnosis was based upon the CT and or MRI scan findings in those patients who were symptomatic. Among which 7 cases of PFACs were treated. The age group ranged between 21 and 54 years and there were preponderance of females (male: Female = 1:6). The following inclusion criteria were followed: (1) Age > 18 years with normal higher functions. (2) PFAC which are above 25 mm in size in any one axis. (3) Erosion of the suboccipital bone or compression of the 4th ventricle or cerebellum. Children and Dandy-Walker cysts and its variants were excluded from the study. Based on the location of the PFAC either excision of the cyst wall or cysto-peritoneal shunt was performed. The entire cyst wall in cases, which were excised was sent for histopathological examination. These patients were periodically followed-up. The follow-up period ranged from minimum 3 years to 12 years.

Literature search was carried out on Internet using PubMed, Medscape and Google Advanced Search. The key words that were used to search were "Arachnoid cysts intracranial arachnoid cysts PFAC intra-fourth ventricular cyst, posterior fossa cyst, retrocerebellar cyst." In the period 1973-2012,

we found 174 PFAC, which have been reported in literature that includes PFAC in pediatric and adults as either exclusive case reports or case series or PFAC cases published under intracranial arachnoid cysts. Different modalities of surgical intervention were followed in these cases with variable success rate and there were no uniform guidelines for the management of these cases.

Results

Among the 7 cases, in 6 cases the PFAC was located in the midline [Figures 1 and 2] and in the 7th case it was in the cerebello-pontine (CP) angle cistern [Figure 3]. All these patients were treated surgically since they were symptomatic. Excision of the cyst was performed in five of these cases. In 2 cases where the PFAC was located within the fourth ventricle, cysto-peritoneal shunt was performed [Figure 1]. Postoperative CT brain scan showed variable reduction in the size of the cyst from complete to partial collapse of the cyst [Figures 1-3] even though clinically all patients improved. The clinical features, location of the cyst within the posterior cranial fossa, surgical procedure performed the complications that occurred following surgical intervention and the long term outcome of all the 7 cases of PFAC has been summarized and presented in Table 1.

Table 1: Clinical summary and outcome of 7 patients with PFAC

Age/sex	Clinical features	Location of arachnoid cyst within the posterior fossa	Supratentorial hydrocephalus	Surgical procedure	Complications	Outcome
32/female	Headache – 1-year, vertigo, nystagmus, ataxic gait	Cerebello-pontine angle	Nil	Retromastoid craniectomy and excision of the cyst wall except over the brainstem – medial aspect	Nil	10 years follow-up – improved no recurrence [Figure 3]
30/female	Headache – 2 years, blurred vision, tandem gait impaired. Had ITP	Midline-retro cerebellar	Yes – VP shunt done – 1-year before definitive surgery for the arachnoid cyst	1 st stage splenectomy followed 2 weeks later by midline suboccipital craniectomy and excision of the cyst wall on all sides except the anterior wall which was fenestrated	Nil	More than 7 years follow up – improved - no recurrence [Figure 2]
21/female	Headache, vomiting – 3 years. No focal neurological deficit	Midline retro cerebellar	No	Midline suboccipital craniectomy and excision of the cyst wall on all sides	Nil	4½ years follow-up – improved no recurrence
54/female	Headache occipital – 2 years, vomiting. No focal neurological deficit	Midline retro cerebellar	No	Midline suboccipital craniectomy and excision of the cyst wall on all sides	Nil	More than 4 years follow-up – improved no recurrence
32/male	Headache – 3 years. Intermittent loss of consciousness – 1-year. Vomiting. Tandem gait impaired	Intrafourth ventricular	No	Cysto-peritoneal shunt	Nil	4 years follow-up – improved no recurrence
34/female	Occipital headache – 3 months. Giddiness of 7 days with intermittent loss of consciousness and abnormal posturing	Midline-retro cerebellar	Nil	Midline suboccipital craniectomy and excision of the cyst walls on all sides	Nil	4 years follow-up – improved no recurrence
31/female	Headache, vomiting – 7 days. 1-month ago had delivered a child. Drowsy, bilateral papilloedema, bilateral 6 th nerve paresis, incoordination and ataxic gait	Intra 4 th ventricular	Yes	VP shunt with cysto peritoneal shunt simultaneously done	Yes – 3 months later chronic subdural hematoma reoperated	6 years follow-up – improved no recurrence [Figure 1]

VP – Ventriculo-peritoneal; ITP – Idiopathic thrombocytopenic purpura; PFAC – Posterior fossa arachnoid cyst

Discussion

We reviewed the literature and found 174 PFAC cases (1973–2012) has been reported that include cases in pediatric group also and added 7 of our new cases in adults with a follow-up ranging from 3 to 12 years. Arai and Sato^[3] had clearly outlined the indications for surgery in cases of PFAC. In their series, they had 7 cases of PFAC among the 26 cases of posterior fossa cyst, which they had reported and that included mega cisterna magna (11 cases), Dandy-Walker malformation (5 cases) and others (3 cases). In these 7 cases, multiple surgical procedures like resection of the posterior wall of the cyst with cysto-peritoneal shunt in the same patient were performed in 5 cases, which clearly show that there is no clear strategy in treatment of PFAC cases. Various treatment options have been suggested in the management of PFAC.^[3-17] Recent advances in neurosurgical techniques and neuroendoscopy, continue to favor endoscopic fenestration over shunt insertion as the method of choice for initial cyst decompression.^[9,11,14,18,19] Holst *et al.*, in their recent article has

stated that the best surgical treatment of cerebral arachnoid cysts is still controversial.^[4] The management strategy followed in various case series and anecdotal case reports were reviewed and analyzing our own cases, we propose a surgical strategy for these lesions.

We observed that these PFACs can occur either in the Midline as 1a: Midline Intra-fourth ventricular/retroclival cyst [Figure 1] 1b: Midline extra-fourth ventricular cyst [Figure 2] or in the lateral region in the 2a: Lateral CP angle cyst [Figure 3] 2b: Lateral retro-cerebellar/intra-cerebellar cyst [Figure 4]. We suggest that in the midline PFAC 1b [Figure 2] and retro-cerebellar PFAC 2b [Figure 4], it is possible to remove the cyst wall completely including that adherent to the cerebellar surface by gently peeling of the cyst wall. During micro-surgical excision of the cyst it is imperative that minimum 5 walls of the cyst are removed to prevent recurrence, considering the cyst as 6 walls. In the CP angle PFAC 2a [Figure 3], in one of our case the medial part of the cyst wall which was adherent to the cerebellar anterior surface and the cranial nerves were left *in situ*. This prevented complete expansion of the cerebellum even after 10 years but patient improved and was asymptomatic. Few authors have reported incidence of cranial nerve injury during excision of the medial wall of cyst wall over the cranial nerves and brainstem in CP angle PFAC.^[10,13] Hence taking this facts into consideration we propose that the inner wall can be left *in situ* in CP angle PFAC and if possible fenestration to be done. Other walls to be excised and still we can achieve excellent functional long-term outcome [Figure 3].

Regarding PFAC 1a [Figure 1] located deep intra-fourth ventricle cyst or retroclival cyst, we suggest a cysto-peritoneal shunt to be performed which is a safe option than opting for open microsurgical excision. To microsurgically approach these cysts located within the fourth ventricle or retroclival

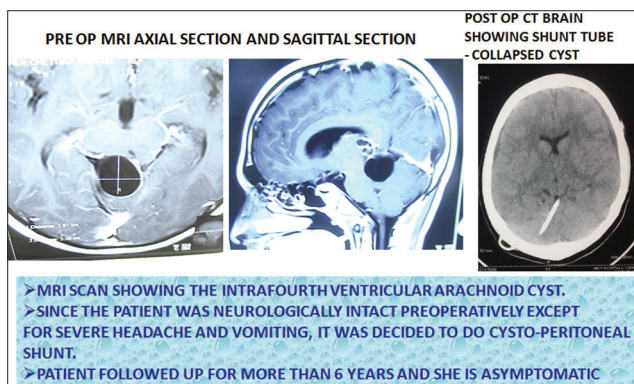


Figure 1: The midline intra-fourth ventricle posterior fossa arachnoid cyst (PFAC 1a) – pre and postoperative scan

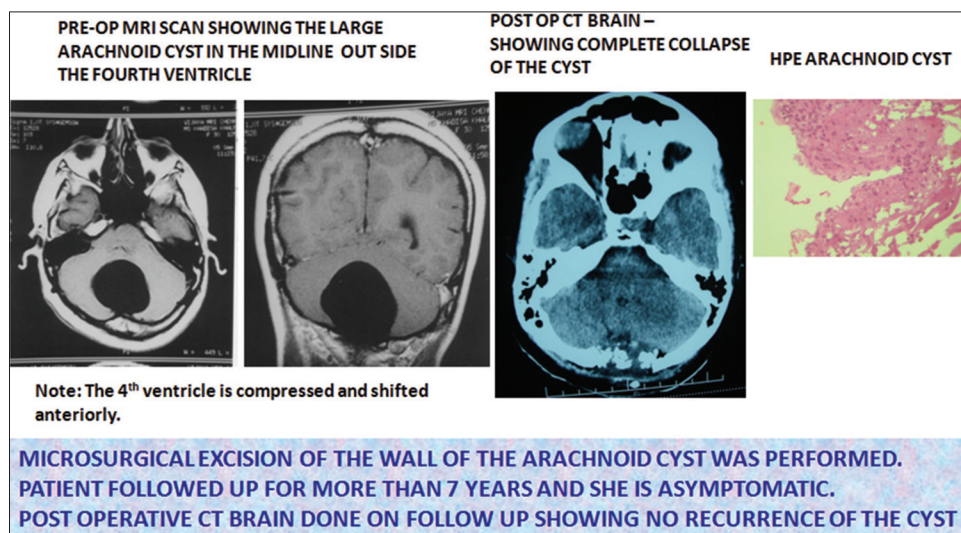


Figure 2: The midline extra fourth ventricular posterior fossa arachnoid cyst (PFAC 1b) – pre and postoperative scan and histopathological picture

region either a midline vermian splitting incision or elevating the vermian have to be performed with its attendant postoperative risks of vermian dysfunction which could be permanent. The other approach for retroclival cyst involves far lateral transcondylar approach, which has its own risk of complications. Regarding endoscopic excision of the cyst

variable results have been obtained with reports of recurrence requiring resurgery.^[4,9,11,20,21] Hence, we prefer cysto-peritoneal shunt for these PFAC 1a type cysts. Treatment of retroclival or intra-fourth ventricular PFAC by cystoperitoneal shunting may be complicated by a malpositioned proximal catheter located within the brainstem or cerebellum causing acute shunt malfunction or neurological deficits.^[22] Sandberg and Souweidane^[23] suggested that proximal catheter placement from a posterior fossa approach can be aided by a malleable endoscope that may prevent malposition and its complications as observed in 3 out of their 4 cases they treated by using this technique. Hence, we suggest this to be performed only by experts in the neuro-endoscopic field.

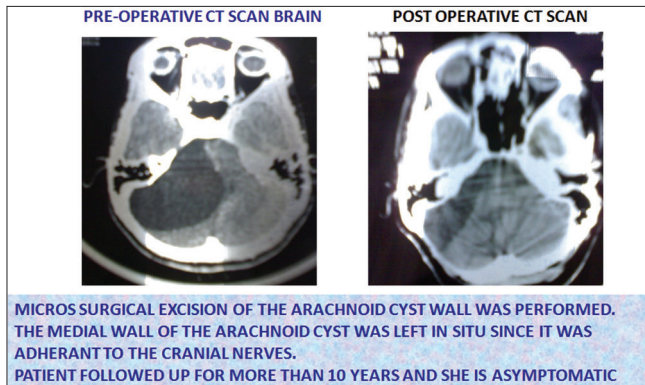


Figure 3: The lateral cerebello-pontine angle posterior fossa arachnoid cyst (PFAC 2a) – Pre and post op scan

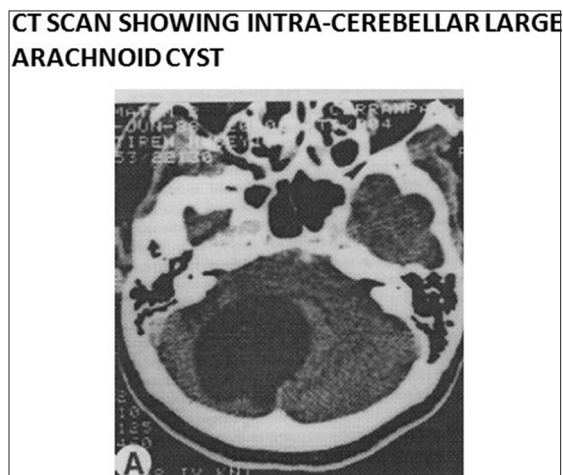


Figure 4: Computed tomography scan showing the lateral intracerebellar posterior fossa arachnoid cyst (PFAC 2b)

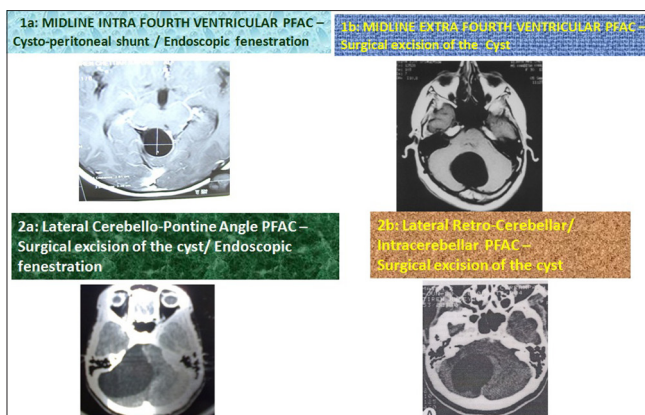


Figure 5: Summary of the surgical strategy for the posterior fossa arachnoid cyst

Obstructive hydrocephalus was present in 2 of our 7 cases especially with midline PFAC. In two patients ventriculo-peritoneal shunt was performed. In 1 case with midline extra-fourth ventricular cyst causing hydrocephalus the shunt was performed 1-year prior to definitive surgery over the cyst without any complications. However in the 2nd case of midline intra-fourth ventricle cyst, the ventriculo-peritoneal shunt was performed simultaneously along with cysto-peritoneal shunt since patient had bilateral papilloedema, bilateral 6th nerve paresis with grossly dilated ventricles indicative of severe raised intracranial pressure. However, this patient developed after few months, symptomatic chronic subdural hematoma and had to be re-operated. Burr hole evacuation of the chronic subdural hematoma and partial closure of the ventriculo-peritoneal shunt was performed. On critical analysis of this case including postoperative CT scan pictures, we opine that it is due to over drainage of the CSF. This has occurred due to restoration of the normal CSF pathway from the 3rd ventricle into the intra-fourth ventricle cyst and also through the ventriculo-peritoneal shunt tube since after partial closure of the shunt tube there was no recurrence of hydrocephalus on follow-up [Figure 1] and patient is asymptomatic for >6 years. Hence, we opine that in cases where associated ventriculo-peritoneal shunt has been performed, they should be under periodic follow-up for a minimum period of 6 months to detect the complications of over drainage of the CSF. Even though our study caters only to adults, after reviewing the published literature in children,^[2-5,9-11,14,18,20,22,23] the above mentioned surgical options for PFAC located in different positions within the posterior fossa can be carried out in children.

Hence in summary, we propose the surgical strategy with which we can achieve excellent long term results for these PFACs. The surgical strategy for Midline extra-fourth ventricular cyst [Figure 2], Lateral CP angle cyst [Figure 3] and lateral retro-cerebellar cyst/intra-cerebellar cyst [Figure 4] is microsurgical excision of the cyst wall, which can be safely performed with excellent long term outcome. The treatment strategy for midline intra-fourth ventricular/retroclival cyst

can be either cysto-peritoneal shunt or endoscopic fenestration of the cyst [Figure 5]. All our cases were followed-up for a minimum period of 3 years and maximum 12 years which to our knowledge it is one of the longest follow-up series of such type of PFAC cases in adults reported in literature.

Acknowledgment

We thank Prof. Dr. P.V.A. Mohandas, Managing Director, MIOT Hospitals, Chennai, India. for permitting us to do the above work.

References

- Galassi E, Piazza G, Gaist G, Frank F. Arachnoid cysts of the middle cranial fossa: A clinical and radiological study of 25 cases treated surgically. *Surg Neurol* 1980;14:211-9.
- Barkovich AJ, Kjos BO, Norman D, Edwards MS. Revised classification of posterior fossa cysts and cyst like malformations based on the results of multiplanar, MR imaging. *AJNR Am J Neuroradiol* 1989;10:977-88.
- Arai H, Sato K. Posterior fossa cysts: Clinical, neuroradiological and surgical features. *Childs Nerv Syst* 1991;7:156-64.
- Holst AV, Danielsen PL, Juhler M. Treatment options for intracranial arachnoid cysts: A retrospective study of 69 patients. *Acta Neurochir Suppl* 2012;114:267-70.
- Little JR, Gomez MR, MacCarty CS. Infratentorial arachnoid cysts. *J Neurosurg* 1973;39:380-6.
- Mori K, Hayashi T, Handa H. Infratentorial retrocerebellar cysts. *Surg Neurol* 1977;7:135-42.
- Vaquero J, Carrillo R, Cabezudo JM, Nombela L, Bravo G. Arachnoid cysts of the posterior fossa. *Surg Neurol* 1981;16:117-21.
- Rock JP, Zimmerman R, Bell WO, Fraser RA. Arachnoid cysts of the posterior fossa. *Neurosurgery* 1986;18:176-9.
- Schroeder HW, Gaab MR, Niendorf WR. Neuroendoscopic approach to arachnoid cysts. *J Neurosurg* 1996;85:293-8.
- Jallo GI, Woo HH, Meshki C, Epstein FJ, Wisoff JH. Arachnoid cysts of the cerebellopontine angle: Diagnosis and surgery. *Neurosurgery* 1997;40:31-7.
- Hopf NJ, Perneczky A. Endoscopic neurosurgery and endoscope-assisted microneurosurgery for the treatment of intracranial cysts. *Neurosurgery* 1998;43:1330-6.
- Erdinçler P, Kaynar MY, Bozkus H, Ciplak N. Posterior fossa arachnoid cysts. *Br J Neurosurg* 1999;13:10-7.
- Samii M, Carvalho GA, Schuhmann MU, Matthies C. Arachnoid cysts of the posterior fossa. *Surg Neurol* 1999;51:376-82.
- Pradilla G, Jallo G. Arachnoid cysts: Case series and review of the literature. *Neurosurg Focus* 2007;22:E7.
- Martínez-Lage JF, Ruiz-Espejo A, Guillén-Navarro E, Almagro MJ. Posterior fossa arachnoid cyst, tonsillar herniation, and syringomyelia in trichorhinophalangeal syndrome Type I. *J Neurosurg* 2008;109:746-50.
- Huang H, Li Y, Xu K, Li Y, Qu L, Yu J. Foramen magnum arachnoid cyst induces compression of the spinal cord and syringomyelia: Case report and literature review. *Int J Med Sci* 2011;8:345-50.
- Galarza M, López-Guerrero AL, Martínez-Lage JF. Posterior fossa arachnoid cysts and cerebellar tonsillar descent: Short review. *Neurosurg Rev* 2010;33:305-14.
- Marin-Sanabria EA, Yamamoto H, Nagashima T, Kohmura E. Evaluation of the management of arachnoid cyst of the posterior fossa in pediatric population: Experience over 27 years. *Childs Nerv Syst* 2007;23:535-42.
- Karabatsou K, Hayhurst C, Buxton N, O'Brien DF, Mallucci CL. Endoscopic management of arachnoid cysts: An advancing technique. *J Neurosurg* 2007;106:455-62.
- Gangemi M, Seneca V, Colella G, Cioffi V, Imperato A, Maiuri F. Endoscopy versus microsurgical cyst excision and shunting for treating intracranial arachnoid cysts. *J Neurosurg Pediatr* 2011;8:158-64.
- Gazioglu N, Kafadar AM, Tanriover N, Abuzayed B, Biceroglu H, Ciplak N. Endoscopic management of posterior fossa arachnoid cyst in an adult: Case report and technical note. *Turk Neurosurg* 2010;20:512-8.
- Turner MS, Nguyen HS, Payner TD, Cohen-Gadol AA. A novel method for stereotactic, endoscope-assisted transtentorial placement of a shunt catheter into symptomatic posterior fossa cysts. *J Neurosurg Pediatr* 2011;8:15-21.
- Sandberg DI, Souweidane MM. Endoscopic-guided proximal catheter placement in treatment of posterior fossa cysts. *Pediatr Neurosurg* 1999;30:180-5.

How to cite this article: Srinivasan US, Lawrence R. Posterior fossa arachnoid cysts in adults: Surgical strategy: Case series. *Asian J Neurosurg* 2015;10:47.

Source of Support: Nil, **Conflict of Interest:** None declared.