

CASE REPORT

Solitary juvenile xanthogranuloma of the cervical spine in a child: A case report and review of literature

Kamlesh Singh Bhaisor, Awadhesh Kumar Jaiswal, Anant Mehrotra, Rabi Narayan Sahu, Arun Srivastava, Sushila Jaiswal¹, Sanjay Behari

Department of Neurosurgery and ¹Department of Pathology, SGPGIMS, Lucknow, Uttar Pradesh, India

ABSTRACT

The authors present a case of 15 years male child who presented with neck pain and progressive ascending quadriparesis. Magnetic resonance imaging showed lytic mass involving C5 and C6 vertebra with soft tissue extension. Surgical excision of mass done using anterior cervical approach. Postoperatively, patient showed improvement in spasticity and power. Histopathological examination of mass was suggestive of juvenile xanthogranuloma (JXG). At 6 months follow-up, patient was improving without any evidence of recurrence. Only 12 cases of JXG of spine have been reported till date including only four cases involving the cervical spine and among these four cases only two were of pediatric age group.

Key words: Cervical vertebra, histology, myelopathy, surgery, xanthogranuloma

Introduction

JXG is a rare proliferative histiocytic disorder that usually occurs in childhood and is regarded as a non-Langerhans cell histiocytosis.^[1] It is not a true neoplasm, but it is thought to be a reactive proliferation of histiocytes. Etiology and pathogenesis of JXG remains unknown. It usually presents as a cutaneous and self-limited lesion in the first two decades of life. Extracutaneous lesions, especially in disease involving the spine are rare.^[2] We report a case of a 15-year-old child who presented to us with compressive myelopathy at C5–C6 level with a mass lesion involving C5–C6 vertebra and was treated with surgical excision of the mass. On histopathological examination, the mass was found to be xanthogranuloma. To the best of our knowledge, this is 3rd reported case of JXG cervical spine in pediatric age group.

Access this article online	
Quick Response Code: 	Website: www.asianjns.org
	DOI: 10.4103/1793-5482.151525

Address for correspondence:

Dr. Awadhesh Kumar Jaiswal, Department of Neurosurgery, SGPGIMS, Lucknow, Uttar Pradesh, India.
 E-mail: jaiswal_dr_2002@yahoo.co.in

Case Report

History and examination

A 15-year-old male presented with pain in the nape of the neck and gradually progressive ascending weakness of all four limbs along with bladder and bowel involvement for 3 years. On examination, tone was increased in all four limbs with 4/5 power in bilateral upper limbs and 2/5 power in both lower limbs, along with exaggerated deep tendon reflexes in all four limbs. Superficial abdominal reflexes were absent and, bilateral planters were extensor. He had 70–80% sensory loss below T4 level. His routine laboratory studies including hematological and biochemical parameters were within normal limits.

Imaging studies

Computerised tomography scan of the cervical spine revealed a large osseo-destructive lesion involving body of C5 and C6 vertebra which was causing spinal canal compromise [Figure 1a and b]. The lesion was involving surrounding structures with extension into the submuscular plane anteriorly. On magnetic resonance imaging (MRI) evaluation, the mass was isointense on T1 and T2 weighted sequences with minimal contrast enhancement. It was causing distraction of C5 and C6 vertebra body with compression of thecal sac [Figure 2a-d].

Operative procedure

Using anterior cervical approach, the tumor resection was performed. Intra-operatively, the tumor involved whole of the C5 and C6 vertebral body. There was a soft tissue component of the tumor, which was extending into the submuscular plane. Inside the capsule, the tumor consisted of cheesy material

that was minimally vascular. Total tumor excision was done with tricorticate iliac crest bone grafting and plate and screw fixation between C4 and C7 vertebral bodies.

Pathological examination

Microscopic examination showed spindle cells disposed of in intersecting fascicles intermingled with mononuclear xanthomatous cells displaying round nuclei with dense chromatin inconspicuous nucleoli and pale eosinophilic finely vacuolated chromatin. Spindle cells display bland appearing nuclear chromatin and eosinophilic cytoplasm. Occasional cells displayed nuclear atypia and enlargement. Scattered neutrophils were seen admixed with these cells. Focal areas of calcification and occasional osteoclasts like giant cells were also seen. Interspersed areas showed degenerated bony trabeculae and cartilage [Figure 3a and b].

Postoperative course

Postoperatively, patient had significant improvement in neck pain and spasticity in all four limbs. At follow-up of 6 months, he was doing well.

Discussion

JXG was first reported by Adamson in 1905 and was termed as a congenital xanthoma multiplex.^[3] JXG is not a true tumor, but rather a reactive proliferation of histiocytes. JXG is the most common non-Langerhans histiocytosis. Most tumors present early in life, and male predominance has been noted in childhood. Despite the term juvenile, JXG can present during adulthood and is most commonly seen during the third and fourth decade, but no sex predilection is seen in adulthood. In pediatric patients, it is more common in males. Central nervous system involvement in cutaneous and extracutaneous JXG is rare and can be classified according to the location. (1) intraparenchymal (2) dural (3) cranial or spinal column.^[4] Solitary JXG especially involving the spine is very rare.^[5,6]

Until date, only 12 cases have been described in English literature with solitary JXG of the spine.^[1,2,4,7-15] Table 1 summarizes the details of all the 12 cases. Four of these were in the cervical spine, 3 in the thoracic spine and 5 in the lumbosacral spine. JXG is a slow growing tumor and presents with features according to location of the tumor.

On MRI, JXG is isointense to hyperintense on T1-weighted sequences and T2-weighted sequences with no or minimal contrast enhancement. According to Schultz *et al.*^[16] spinal JXG does not enhance whereas enhancement can be seen in cerebral JXG. Spinal JXG should be distinguished from tumors of neural origin such as schwannoma, meningioma, lymphoma, etc., On gross examination, JXG usually are encapsulated with or without cystic component that is yellowish to gray in color. Definitive diagnosis can be made by pathological and immunohistochemical studies. Microscopically, JXG

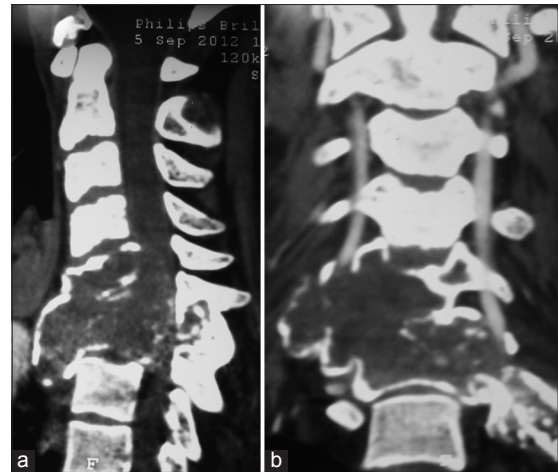


Figure 1: (a and b) contrast enhanced computer tomography showing lytic lesion involving anterior and posterior element of C5 and C6 vertebra with minimal enhancement

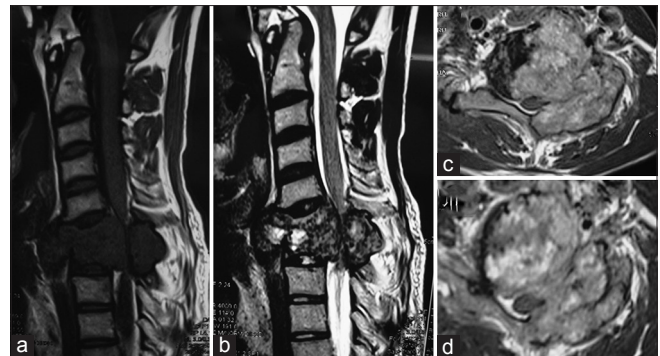


Figure 2: (a) T1-weighted1 saggital magnetic resonance imaging (MRI) showing isointense mass involving anterior and posterior elements of C6 vertebral with thecal sac compression. (b) T2-weighted saggital MRI showing isointense mass with slight hyperintensity involving anterior and posterior element of C6 vertebral body. (c and d) T1-weighted axial cuts of MRI with contrast showing mass involving anterior and posterior element of C6 vertebra with minimal contrast enhancement

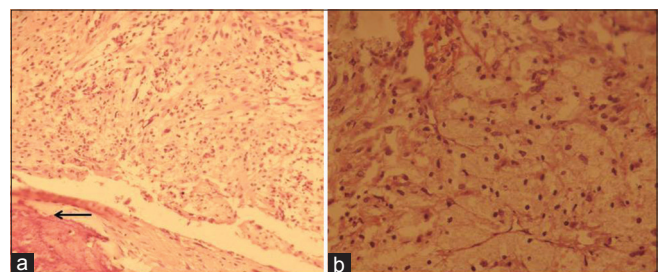


Figure 3: H and E, stained section shows (a) spindle cells disposed in intersecting fascicles intermingled with mononuclear foam cells. Interspersed areas (arrow) show degenerated bony trabeculae and cartilage (x200). (b) Foam cells (x400) displaying round nuclei with dense chromatin inconspicuous nucleoli and pale eosinophilic finely vacuolated cytoplasm (b)

has foamy histiocytic cells with or without Touton giant cells in the background of mononuclear cell infiltrates. In immunohistochemistry studies, JXG has mononuclear cells,

Table 1: Summary of the reported cases of JXG in the literature

Authors/year	Age/sex	Clinical features	Location	Surgery	Outcome
Shimosawa <i>et al.</i> ^[8] 1993	13 months/female	Spastic paraparesis	T6–9 IDEM	T6–T9 laminectomy with excision of tumor	Improved
Kitchen <i>et al.</i> ^[9] 1995	15 years/female	Low back pain	S1 nerve root	L5 laminectomy with total excision	Symptoms improved
Kim <i>et al.</i> ^[2] 1996	16 months/female	Paraparesis	T1–2 IDEM	C7–T3 laminectomy with total excision of tumor	Resolution by 4 months
Iwasaki <i>et al.</i> ^[10] 2001	41 years/female	Weakness and numbness in both lower limbs	Cauda equina	L1–L5 laminectomy with excision of tumor	Not mentioned
Rampini <i>et al.</i> ^[4] 2001	34 years/female	Spastic quadriplegia	C5–C7 IDEM	C5–T1 laminectomy with total excision of tumor	Improved
Dehner <i>et al.</i> ^[1] 2003	14 years/female	Back pain	L3 vertebral body	Not mentioned	Not mentioned
Cao <i>et al.</i> ^[15] 2008	18 years/female	Neck pain	C2 root	C1–C2 laminectomy with total excision of tumor	No recurrence at 2 years
Castro-gago <i>et al.</i> ^[11] 2009	14 years/male	Paraparesis	Cauda equina	L2–L3 laminectomy with partial excision	Postoperative RT, no recurrence at 2 years
Lee <i>et al.</i> ^[12] 2011	29 years/male	Hemiparesis with contralateral hypoesthesia below c2	C1–C2	C1–C2 laminectomy with total excision of tumor	Improved
Jain <i>et al.</i> ^[13] 2011	22 years/female	Progressive back pain	T7 vertebral body	T7 laminectomy with excision of tumor	Improved
Agabegi <i>et al.</i> ^[7] 2011	47 years/female	Bowel, bladder involvement and back pain	L2 vertebral body	T12–L3 laminectomy with partial excision	Postoperative RT, improved at 8 months
Inoue <i>et al.</i> ^[14] 2011	38 years/male	Numbness and weakness of right hand	C8 nerve root	C7–T1 laminectomy	No recurrence at 2 years
Present case/2013	16 years/male	Spastic quadriplegia with neck pain	C5–C6	Anterior cervical approach with excision of tumor	Improved no recurrence at 6 months

RT – Radiotherapy; IDEM – Intradural extramedullary

giant cells and spindle cells, which are positive for lysosomal stain and CD68, but negative for CD1a and S-100 proteins, which are reactive markers for Langerhans cells.

No standard treatment protocol for treatment of JXG of spine has been described as these lesions are extremely rare. These lesions are slow growing benign lesion without regression, unlike cutaneous lesions. Total excision of the tumor should be done with preservation of normal structures and cervical motion. Recurrence has not been reported after gross total excision. Of the 12 cases, two patients underwent partial excision after which they underwent radiotherapy, no recurrence was reported in these patients in follow-up. Despite these results, total excision of the tumor appears to be curative due to the benign nature of the tumor. As the natural course of solitary JXG is not known, so patient should be kept in the long term follow-up.

Our patient was treated with near total excision of the tumor with C5 and C6 corpectomy using anterior cervical approach with bone grafting and spinal stabilization. Postoperatively, patient had significant improvement in spasticity and power in all four limbs.

Cutaneous JXG is commonly found in pediatric patients but till date only 12 cases of solitary JXG of spine have been reported. To the best of our knowledge, our case is 13th case of

solitary xanthogranuloma of spine and 5th in the cervical spine. This is the third case in the pediatric age group affecting the cervical spine.

Conclusion

We present a histologically confirmed case of solitary JXG of the cervical spine in 15-year-old child. JXG should be considered to be a differential diagnosis for such tumors of the spine. Total excision of the tumor should be attempted with preservation of normal neural structures. As these lesions are benign, total excision appears to be curative. These patients should be kept in the long term follow-up as the natural course of these tumors is not known.

References

- Dehner LP. Juvenile xanthogranulomas in the first two decades of life: A clinicopathologic study of 174 cases with cutaneous and extracutaneous manifestations. *Am J Surg Pathol* 2003;27:579-93.
- Kim DS, Kim TS, Choi JU. Intradural extramedullary xanthoma of the spine: A rare lesion arising from the dura mater of the spine: Case report. *Neurosurgery* 1996;39:182-5.
- Adamson NF. Congenital xanthoma multiplex in a child. *Br J Dermatol* 1905;17:222-3.
- Rampini PM, Alimehmeti RH, Egidi MG, Zavanone ML, Bauer D, Fossali E, *et al.* Isolated cervical juvenile xanthogranuloma in childhood. *Spine (Phila Pa 1976)* 2001;26:1392-5.
- Boström J, Janssen G, Messing-Jünger M, Felsberg JU, Neuen-Jacob E, Engelbrecht V, *et al.* Multiple intracranial juvenile xanthogranulomas.

- Case report. *J Neurosurg* 2000;93:335-41
6. Kraus MD, Haley JC, Ruiz R, Essary L, Moran CA, Fletcher CD. "Juvenile" xanthogranuloma: An immunophenotypic study with a reappraisal of histogenesis. *Am J Dermatopathol* 2001;23:104-11
 7. Agabegi SS, Iorio TE, Wilson JD, Fischgrund JS. Juvenile xanthogranuloma in an adult lumbar spine: A case report. *Spine (Phila Pa 1976)* 2011;36:E69-73.
 8. Shimosawa S, Tohyama K, Shibayama M, Takeuchi H, Hirota T. Spinal xanthogranuloma in a child: Case report. *Surg Neurol* 1993;39:138-42.
 9. Kitchen ND, Davies MS, Taylor W. Juvenile xanthogranuloma of nerve root origin. *Br J Neurosurg* 1995;9:233-7.
 10. Iwasaki Y, Hida K, Nagashima K. Cauda equine xanthogranulomatosis. *Br J Neurosurg* 2001;15: 72-73.
 11. Castro-Gago M, Gómez-Lado C, Alvez F, Alonso A, Vieites B. Juvenile xanthogranuloma of the cauda equina. *Pediatr Neurol* 2009; 40:123-125.
 12. Lee SJ, Jo DJ, Lee SH, Kim SM. Solitary Xanthogranuloma of the Upper Cervical Spine in a Male Adult. *J Korean Neurosurg Soc* 2012; 51:54-8.
 13. Jain A, Mathur K, Khatri S, Kasana S, Jain SK. Rare presentation of juvenile xanthogranuloma in the thoracic spine of an adult patient : Case report and literature review. *Acta Neurochir (Wien)* 2011; 153:1813-1818.
 14. Inoue H, Seichi A, Yamamuro K, Kojima M, Kimura A, Hoshino Y. Dumbbell-type juvenile xanthogranuloma in the cervical spine of an adult. *Eur Spine J* 2011;20:S343-7.
 15. Cao D, Ma J, Yang X, Xiao J. Solitary juvenile xanthogranuloma in the upper cervical spine: Case report and review of the literatures. *Eur Spine J* 2008;17:S318-23.
 16. Schultz KD Jr, Petronio J, Narad C, Hunter SB. Solitary Intracerebral juvenile xanthogranuloma: Case report and review of the literature. *Pediatr Neurosurg* 1997;26:315-21.

How to cite this article: Bhaisora KS, Jaiswal AK, Mehrotra A, Sahu RN, Srivastava A, Jaiswal S, *et al.* Solitary juvenile xanthogranuloma of the cervical spine in a child: A case report and review of literature. *Asian J Neurosurg* 2015;10:57.

Source of Support: Nil, **Conflict of Interest:** None declared.