

CASE REPORT

Orbital intraconal abducens nerve schwannoma: A case report and review of the literature

Amresh Subhash Bhaganagare, Vishakha Chandrakant Bidkar, Elvis Rodrigus, Vikas Naik, Balaji Pai

Department of Neurosurgery, Pradhan Mantri Swastha Suraksha Yojana – Superspeciality Hospital, Bangalore Medical College and Research Institute, Bengaluru, Karnataka, India

ABSTRACT

Authors report a case of right orbital intraconal abducens nerve schwannoma in a 32-year lady, who presented with a sense of tightness and discomfort in right eye on looking extreme right side since 4 months. The tumor was totally excised with functional preservation of the nerve by superior orbitotomy. The clinical, radiological features and the management are discussed.

Key words: Abducens, intraconal, intraorbital, schwannoma

Introduction

Schwannomas are tumors arising from the schwann cells of the neural sheath of motor and sensory nerve fascicles and present as well-defined eccentrically placed masses. They may present in three clinical forms; localized schwannomas, in association with neurofibromas (as a part of von Recklinghausen syndrome), or as schwannomatosis.^[1]

Intraorbital schwannomas may arise from different nerves; sometimes, it may be difficult to identify their true origin.^[2] Those arising from the sensory branches of trigeminal nerve are located in superior and medial quadrants of orbit,^[3] those arising from infraorbital nerve are in inferior quadrants^[4] and schwannomas arising from the motor nerves usually arise at their respective myoneural junction. The literature search has identified only three other abducens nerve schwannomas of the orbit.

Video Available: www.asianjns.org

Access this article online

Quick Response Code:



Website:

www.asianjns.org

DOI:

10.4103/1793-5482.151531

Address for correspondence:

Dr. Amresh Subhash Bhaganagare, Department of Neurosurgery, Pradhan Mantri Swastha Suraksha Yojana – Superspeciality Hospital, Bangalore Medical College and Research Institute, Victoria Hospital Campus, Fort Road, Bengaluru - 560 002, Karnataka, India. E-mail: amreshsb@yahoo.com

Case Report

A 32-year-old lady came to our outpatient department with complaints of tightness and discomfort in the right eye, especially on looking toward extreme right since 4 months. Her visual acuity was 6/6 as per Snellen chart and visual fields symmetrical in both eyes on clinical examination. Fundoscopy revealed no abnormality. There were no neurocutaneous markers of neurofibromatosis. Patient was reassured and was asked to review after 15 days. Patient was not relieved of her symptoms, and she noticed mild proptosis of right eye. She underwent magnetic resonance imaging (MRI) scan of the orbit with contrast.

Magnetic resonance imaging scan [Figures 1-3] revealed, a 2.1 cm × 1.8 cm × 1.7 cm well-defined, lobulated intraconal mass lesion in the posterior right orbit in close proximity to the optic nerve, displacing the nerve supero-medially. The lesion is homogeneously hypointense to gray matter on T1-weighted (T1-W) and isointense on T2-W-images. On early postcontrast images, the lesion enhances homogeneously and shows intense enhancement on delayed images.

Patient underwent right frontal craniotomy and superior orbitotomy. Minimal subfrontal dural retraction was necessary. Under the operating microscope, Tenon's fascia was opened in cruciate fashion and opening extended posteriorly till the anterior margin of the optic canal. The intraconal fat was sharply dissected till the superior rectus muscle (SRM) was seen, and dissection continued medial to SRM till the superior branch of the ophthalmic artery was safely isolated. The dissection continued in this plane till the tumor was seen. The tumor was moderately vascular, soft to firm, pinkish with thick capsule. The capsule was incised, and tumor debulked

with cavitron ultrasonic aspirator till very minimal tumor was left attached to capsule. There was no intraconal retraction during the surgery; the lateral rectus muscle (LRM) was seen with the abducens nerve innervating the muscle and tumor capsule arising from the myoneural junction. The tumor capsule was completely excised without damaging the nerve. Operative video is submitted for interested viewers [Video 1]. The edges of Tenon's fascia were just approximated as water tight closure was not possible. The superior orbital plate was small and thin, and roof of the orbit was reconstructed with bioresorbable polycaprolactone (PCL) scaffold, which is known to have osteo-inductive properties. The scalp incision was sutured, and suction drain was placed in subgaleal space.

The histopathology [Figure 4a-d] revealed a well-circumscribed, thin encapsulated neoplasm composed of predominantly interwoven fascicles of spindle cells with elongated nuclei, eosinophilic cytoplasm, and indistinct cytoplasmic borders (Antoni A pattern). Prominent nuclear palisade is observed which is referred to as Verocay bodies. Furthermore, a focal hypocellular area with a loose, vacuolated stroma was observed (Antoni B pattern). The histological features were diagnostic of schwannoma.

Six months after surgery, patient is having complete range of extraocular movements [Figure 5] and the eyes, facial contour is symmetrical. Six months postoperative computed tomography scan [Figure 6] confirmed complete excision; bone formation was not yet visible in the PCL scaffold which was used for orbital roof reconstruction.

Discussion

Though abducens or sixth cranial nerve has the longest intracranial course, schwannomas of the abducens nerve are extremely rare tumors.^[5] The tumor may be located within the cavernous sinus^[6] or more often at the preoptine^[5] region and as intrinsic brainstem tumors.^[7] The literature research has identified only three other cases of isolated schwannoma of the orbit, arising from the terminal branches of the abducens nerve to the LRM.^[1,8,9]

Correct diagnosis and accurate definition of the location and the extent of the lesion greatly facilitate successful surgical

excision. Orbital schwannoma on MRI is usually described as a lesion that produces a low signal on T1-W images and a high signal on T2-W images, which can be homogeneously or heterogeneously enhanced.^[10] The histology of these lesions underlies the variation in their appearance on MRI. Intraorbital abducens schwannoma is situated in lateral intraorbital quadrant, medial to LRM and displaces the optic nerve medially and upwards.^[1,8,9]

We summarize the main features by comparing our case with those described by Irace *et al.*,^[9] Miguel *et al.*^[11] and Feichtinger *et al.*^[8] [Table 1].

Similar to the description by Irace *et al.*,^[9] Miguel *et al.*^[11] and Feichtinger *et al.*^[8] in our case, we were able to demonstrate preoperatively by MRI [Figures 1-3] and intraoperatively by identifying the area of attachment of the tumor, the origin of the schwannoma from the abducens nerve.

The lesions in the lateral quadrant of the orbit can be approached by lateral or superior orbitotomy. Through lateral orbitotomy Irace *et al.*^[9] and Feichtinger *et al.*^[8] could achieve only partial excision of solid tumor and Miguel *et al.*^[11] could do total excision as, fortunately, the tumor was cystic. The superior orbital approach involves frontal craniotomy followed by superior orbitotomy to gain access, and it can be extended for more posterior lesions. Superior orbitotomy gives direct access to superior, medial, and lateral quadrants of orbit with minimal retraction of the intraconal structures thereby ensuring safe and complete excision of the lesions.

Based on the work of Erdogmus *et al.*,^[11] Irace *et al.*^[9] proposed that the entry point of nerve fibers in the muscle (e.g. area nervosa or myoneural junction)^[12] is the zone where intraorbital schwannomas truly arise. When performing intraorbital surgery, anatomic knowledge of the innervation of the extraocular muscles allows one to minimize damage to neural structures. In particular, when approaching the superolateral compartment of the orbit, the knowledge of the course and branching of the abducens nerve is required. This cranial nerve runs on the medial surface of the LRM and innervates in the middle third of the muscle. In our case, this knowledge was essential to preserve nerve integrity

Table 1: Patients with intraorbital abducens nerve schwannoma

Author	Age/sex	Clinical presentation	Tumor size (cm)	Tumor type	Surgical approach	Extent of resection	VI nerve function	Follow-up
Irace <i>et al.</i> , ^[9]	55/male	Abducens nerve palsy; painless proptosis?		Solid	Lateral orbitotomy	Partial	Partial recovery	?
Rui Miguel <i>et al.</i> ^[11]	42/male	Abducens nerve palsy; painful proptosis	2.2	Cystic	Lateral orbitotomy	Total	Total recovery	?
Feichtinger <i>et al.</i> ^[8]	53/female	Abducens nerve paresis, optic atrophy	4.5×2×1.5	Solid	Lateral orbitotomy	Simple intracapsular enucleation (partial)	Partial recovery	?
Present case	32/female	Pain in right eye	2.1	Solid	Superior orbitotomy	Total	Preserved	8 months

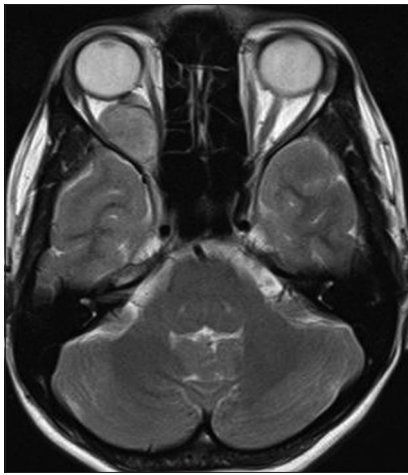

Figure 1: Magnetic resonance imaging T2 iso intense lobulated intraconal lesion displacing right optic nerve medially. The lesion is seen extending from the superior orbital fissure and closely abutting the right lateral rectus muscle

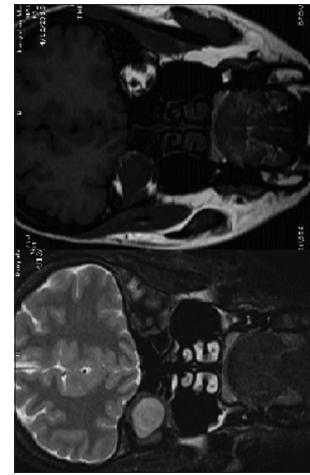


Figure 2: Magnetic resonance imaging coronal sequence showing T1 hypo and T2 iso intense lobulated intraconal lesion occupying the right orbital apex with superomedial displacement of the optic nerve

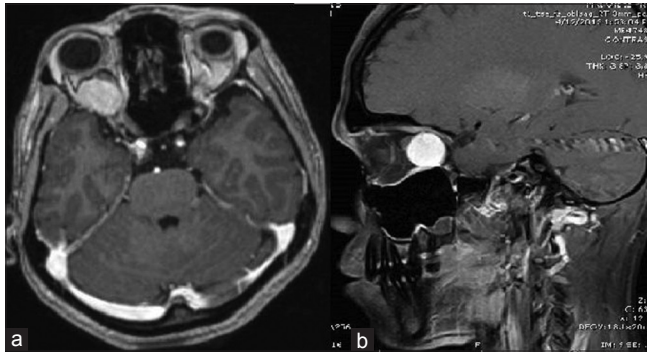


Figure 3: Magnetic resonance imaging postcontrast axial (a) and sagittal (b) sequences showing intense enhancement

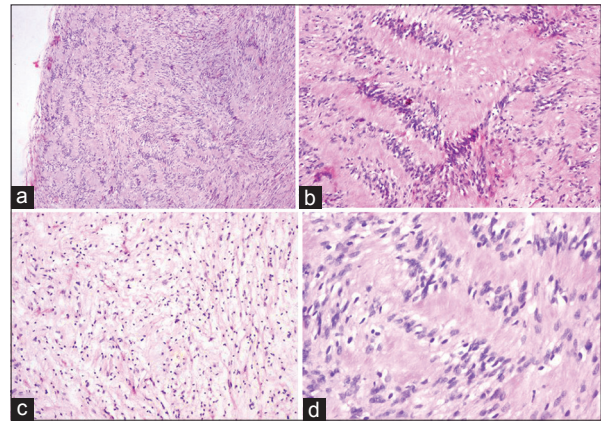


Figure 4: (a) Microphotograph showing a circumscribed thinly capsulated spindle cell neoplasm (H and E, x40). (b) Microphotograph showing cellular Antoni areas with Verocay bodies (H and E, x100). (c) Microphotograph showing hypocellular Antoni B area with a loose, vacuolated stroma (H and E, x100). (d) Microphotograph showing nuclear palisading constituting the Verocay bodies (H and E, x200)

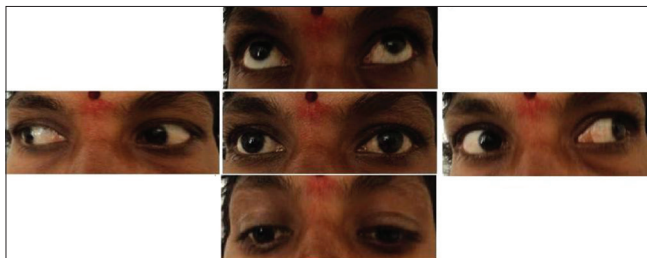

Figure 5: Postoperative photograph of the patient showing synchronous complete range of extraocular movements of both eyes

and function as we could visualize the tumor attachment at myoneural junction, and safe and complete tumor excision was possible. With the availability of PCL scaffolds^[13] the orbital roof can be readily reformed.

Gamma knife surgery (GKS)^[14] has been tried in four patients of intraorbital schwannoma. After GKS, the patient treated for an orbitocavernous schwannoma experienced a significant deterioration in vision, temporary blindness in one eye, and late development of permanent abducens nerve palsy, which were

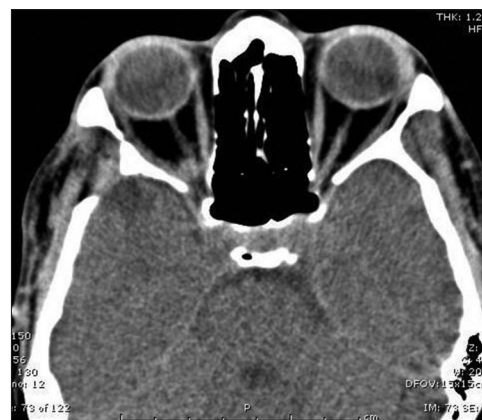


Figure 6: Postoperative computed tomography scan showing complete excision of the tumor, there was no radiological evidence of bone formation in the polycaprolactone scaffold which is known to have osteo-inductive properties

seemingly caused by compression of neurovascular structures within the annulus of Zinn during a temporary increase in the lesion's volume after irradiation. The cisternocavernous schwannoma underwent cystic degeneration 2 years after GKS, and the patient developed diplopia. Purely intracavernous neoplasms in general followed uneventful posttreatment courses. Imaging studies showed temporary enlargement of all tumors during the 1st posttreatment year, but thereafter, there was a trend toward reduction in volume and none of the neoplasms displayed regrowth. GKS controls the growth of abducens nerve schwannomas and may be effectively used to manage intracavernous neoplasms, but however, caution should be used in cases of dumbbell-shaped tumors, particularly those extending through the superior orbital fissure.

Conclusion

Though functional preservation of the abducens nerve is the rule, complete excision of the tumor should be the goal as residual tumor can potentially regrow, and GKS has discouraging outcome. Superior orbitotomy is an ideal approach as it gives direct access to nerve and muscle, which can be safely preserved while complete tumor excision is being achieved.

Acknowledgment

We thank our patient who agreed and gave consent for photographing and submitting the work for publication.

References

1. Miguel FR, Miguel C, Paulo CJ, Pedro SR. Intraorbital abducens nerve schwannoma. *World Neurosurg* 2012;78:375.e1-4.
2. Cantore G, Ciappetta P, Raco A, Lunardi P. Orbital schwannomas:

- Report of nine cases and review of the literature. *Neurosurgery* 1986;19:583-8.
3. Jakobiec FA, Font RL. Peripheral nerve sheath tumours. In: Spencer WH, editor. *Ophthalmic Pathology*. Philadelphia, PA: Saunders; 1986. p. 2616-26.
4. Garg R, Dhawan A, Gupta N, D'souza P. A rare case of benign isolated schwannoma in the inferior orbit. *Indian J Ophthalmol* 2008;56:514-5.
5. Erlich SA, Tymianski M, Kiehl TR. Cellular schwannoma of the abducens nerve: Case report and review of the literature. *Clin Neurol Neurosurg* 2009;111:467-71.
6. Mascarenhas L, Magalhaes Z, Honavar M, Romao H, Resende M, Resende Pereira J, *et al.* Schwannoma of the abducens nerve in the cavernous sinus. *Acta Neurochir (Wien)* 2004;146:389-92.
7. Vachata P, Sames M. Abducens nerve schwannoma mimicking intrinsic brainstem tumor. *Acta Neurochir (Wien)* 2009;151:1281-7.
8. Feichtinger M, Reinbacher KE, Pau M, Klein A. Intraorbital schwannoma of the abducens nerve: Case report. *J Oral Maxillofac Surg* 2013;71:443-5.
9. Irace C, Davi G, Corona C, Candino M, Usai S, Gambacorta M. Isolated intraorbital schwannoma arising from the abducens nerve. *Acta Neurochir (Wien)*. 2008;150:1209-10.
10. Wang Y, Xiao LH. Orbital schwannomas: Findings from magnetic resonance imaging in 62 cases. *Eye (Lond)* 2008;22:1034-9.
11. Erdogmus S, Govsa F, Celik S. Innervation features of the extraocular muscles. *J Craniofac Surg* 2007;18:1439-46.
12. Kakizaki H, Zako M, Miyagawa T, Nakano T, Asamoto K, Iwaki M. Myoneural junctions of extraocular muscles: Distances from the orbital rim and widths. Part 2. *Ophthalmologica* 2006;220:347.
13. Lim TC, Schantz JT, Sundar G, Amrith S. Reconstruction of the Orbit with a Bioresorbable Poly-caprolactone implant: A prospective randomised control clinical trial. Available from: <http://www.clinicaltrials.gov/show/NCT00233922>. Last updated: 2008 May 12.
14. Hayashi M, Chernov M, Tamura N, Yomo S, Ochiai T, Nagai M, *et al.* Gamma Knife surgery for abducent nerve schwannoma. Report of 4 cases. *J Neurosurg* 2010;113 Suppl: 136-43.

How to cite this article: Bhaganagare AS, Bidkar VC, Rodrigus E, Naik V, Pai B. Orbital intraconal abducens nerve schwannoma: A case report and review of the literature. *Asian J Neurosurg* 2015;10:61.

Source of Support: Nil, **Conflict of Interest:** None declared.