

CASE REPORT

Pure cortical ependymoma: A rare entity

Sanjay Bijwe, Sameer Ansari, Vinod Jadhav, Deepak Palande¹

Departments of Pathology and ¹Neurosurgery, Grant Government Medical College and Sir J.J. Hospital, Mumbai, Maharashtra, India

ABSTRACT

Ependymomas are mostly infratentorial, intraventricular tumor, accounting for 2–9% of all central nervous system tumors. Supratentorial pure cortical ependymoma are extremely rare tumor with definite ependymal morphology and uncertain histogenesis. They are mostly low grade tumor and are cured with resection, rendering them favorable prognosis. Our case is of 14-year-old female presenting with headache and convulsion of short duration. She underwent gross total excision of the tumor without radiation therapy and her follow-up is uneventful.

Key words: Cortical, ependymoma, extraventricular, supratentorial

Introduction

Supratentorial cortical ependymomas (CE) are unique tumor with very few cases reported so far in the literature. They occur in the superficial cortical ribbon and have no connection with the ventricular lining.^[1] These tumor have relatively benign course and shows close relationship with the recently described entity - angiocentric glioma (AG).^[2]

Case Report

A 14-year-old female came with complaint of headache, vomiting and seizure since 1-month. Her systemic examination was normal. Routine laboratory examinations were normal. Computed tomography (CT) showed a large, well-defined, extra axial right frontal mass measuring 4 cm × 3 cm × 2.6 cm associated with perifocal edema [Figure 1]. Magnetic resonance imaging (MRI) revealed 4 cm × 3 cm × 2.6 cm, right frontal mass showing contrast enhancement [Figure 2]. Radiologically the differential diagnoses given were? Meningioma and? Oligodendroglioma. Cerebrospinal fluid (CSF) examination did not reveal any

atypical cells. Surgical resection of the mass was planned, and the patient underwent total resection of the tumor, which was located in the parenchyma with no dural attachment. The tumor was clearly demarcated and dissected subpially from the surrounding brain parenchyma. The surgical findings suggested no relationship with the lateral ventricular system. Intraoperative squash cytology reveal [Figure 3] cellular smear showing tumor cells arranged in papillary pattern. The individual cells are round to oval nuclei with focally prominent nucleoli and moderate amount of eosinophilic cytoplasm. At places rosette like structures were also seen favoring the diagnosis of ependymoma. Histopathological examination of the tumor demonstrated diffuse sheet of ependymal cells with focal area showing perivascular pseudorosettes and true rosettes [Figures 4 and 5]. Immunohistochemistry reveal diffuse positive reactivity for glial fibrillary acidic protein [Figure 6] and dot like positivity for epithelial membrane antigen (EMA) [Figure 7]. The Ki-67 index was 5% [Figure 8]. These findings confirmed ependymoma, World Health Organization (WHO) Grade II. The patient's postoperative course was uneventful. He reported no complaints at his 6-month follow-up, and CT and MRI revealed no recurrence.

Discussion

Ependymomas are central nervous system (CNS) tumor arising from ependymal cells lying on the inner surface of brain ventricle and along the central spinal cord.^[3] They are commonly seen in the cervico thoracic segment of the spinal central canal and fourth ventricle.^[3,4] Supratentorial cortical ependymoma is a rare entity where the tumor is seen in cortical region without any connection to the ventricular lining.^[2] The current WHO classification of CNS tumor divide ependymoma into low grade (Grade II) and high grade (Grade III) or anaplastic ependymoma, reserving

Access this article online

Quick Response Code:



Website:

www.asianjns.org

DOI:

10.4103/1793-5482.152111

Address for correspondence:

Dr. Sameer Ansari, Department of Pathology, Grant Government Medical College and Sir J.J. Hospital, Byculla, Mumbai - 400 008, Maharashtra, India.
E-mail: drsameeransari@yahoo.co.in

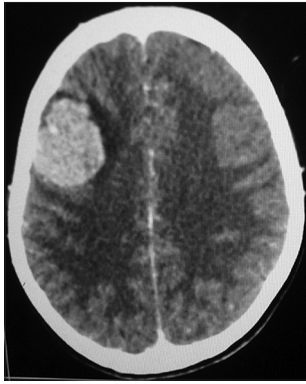

Figure 1: Computed tomography scan showing well defined, extra axial right frontal mass measuring 4 cm × 3 cm × 2.6 cm

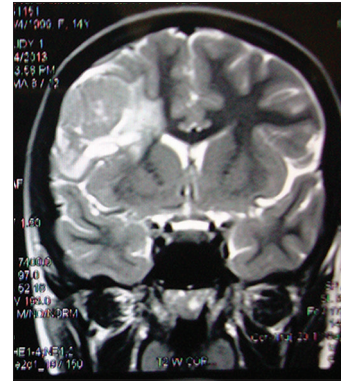


Figure 2: Magnetic resonance imaging showing revealed 4 cm × 3 cm × 2.6 cm right frontal mass showing contrast enhancement

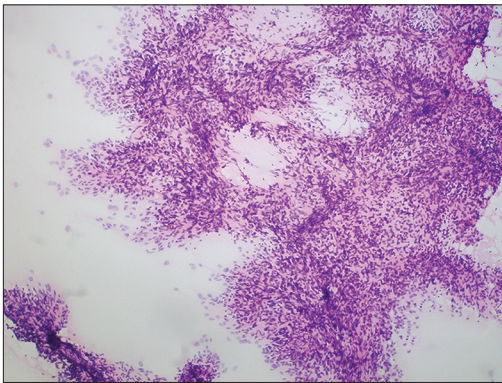


Figure 3: Intra-operative squash cytology shows round to oval tumor cells in papillary pattern (H and E, ×200)

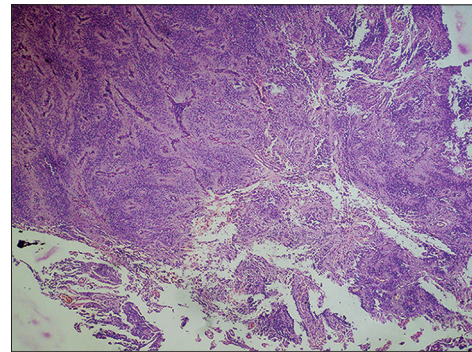


Figure 4: Microphotograph showing diffuse sheet of ependymal cells with focal area showing perivascular pseudorosette and true rosettes (H and E, ×100)

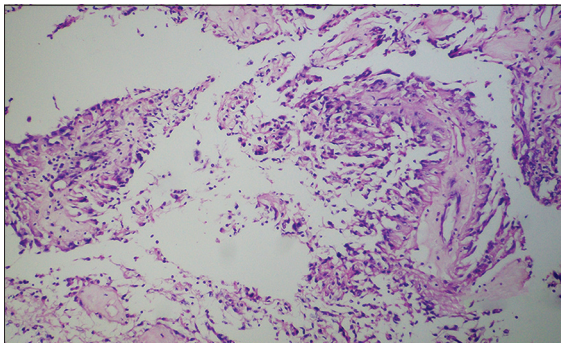


Figure 5: Microphotograph showing perivascular pseudorosette and true rosettes (H and E, ×200)

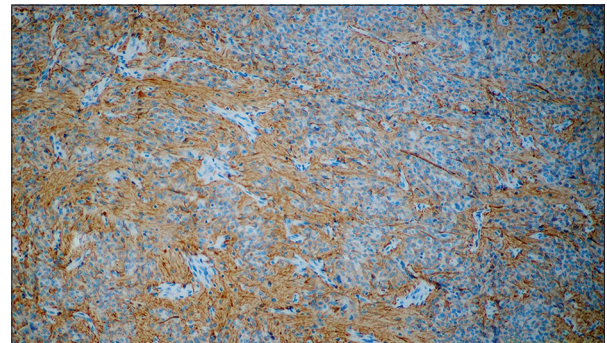


Figure 6: Immunohistochemistry showing diffuse positive reactivity for glial fibrillary acidic protein (H and E, ×200)

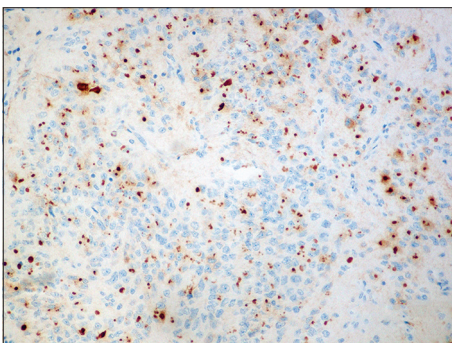


Figure 7: Immunohistochemistry showing dot like positivity for epithelial membrane anti-gen (H and E, ×200)

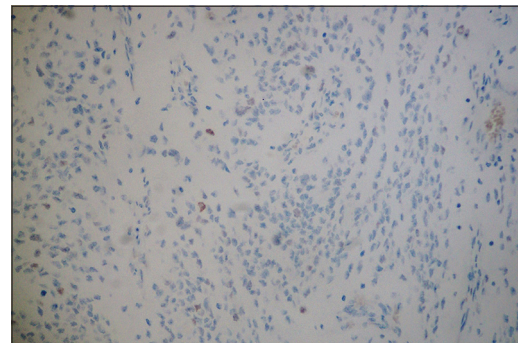


Figure 8: Immunohistochemistry showing low Ki-67 index (5%) (H and E, ×200)

Grade I for myxopapillary ependymoma.^[5] The mean age of presentation is 27 ± 19 years.^[3] They frequently, but not always present with seizures, but despite their high association with epilepsy they are hardly seen in temporal lobe.^[6]

Our patient also presented with seizure although had a mass in frontal lobe. The pathogenesis of ependymoma remains uncertain. Some suggest that they originate from cell type other than terminally differentiated ependyma since they arise at sites where ependymal cells are absent.^[6] Hegyi *et al.* in their reported case of ectopic retinal ependymoma proposed their origin from Muller cells, concluding that glial cells with progenitor properties are the cell of origin for these tumor rather than terminally differentiated ependyma.^[7] Progenitor cell hypothesis could be suggested to explain the origin of CE as their occurrence in teratomas seem to support this view.^[8-10] Roentgenographically, it shows a well-defined solid to cystic mass located in peripheral cortical rim with minimal associated vasogenic edema.^[3]

On squash cytology it reveal cellular smear comprised of tumor cells in papillary pattern against fibrillary background with focal area showing perivascular pseudorosettes. The cells show round nucleus with stippled chromatin and 1–2 small nucleoli.^[11] Histopathology shows true ependymal rosettes and perivascular pseudorosettes which are the characteristic features defining these tumors. Less typical morphological features that can be seen include tanycytic, epithelioid and clear cell features.^[3] Rarely it can show additional spindle cell component and schwannian like nodules features that are typical of AG as described by Lehman.^[12] Our case did not show the above described features ruling out the possibility of AG. AG are seizure associated tumor characterized by an angiocentric pattern of growth, monomorphous bipolar cells and features of ependymal differentiation.^[13] The close differential that can also be considered for this tumor is astroblastoma, which also reveals rosettes which have shorter and stouter cytoplasmic processes when compared to rosettes of ependymoma.^[14] Immunohistochemistry plays a pivotal role in differentiating these two entities as EMA shows dot like positivity in ependymomas, which is characteristic for this tumor.^[2] Anaplastic Grade III ependymomas are characterized by increased cellularity, marked mitotic activity, microvascular proliferation and pseudopalisading necrosis. It is important to identify anaplastic ependymoma as it shows increased chances of recurrences and requires radiation therapy along with survival resection.^[1] Metastatic seeding along the CSF pathway is frequently seen and is widespread in anaplastic form.^[1] Hence, preoperative CSF examination for ruling out metastatic seeding along with postoperative MRI to evaluate the extent of excision is mandatory. Surgical excision is the main modality of treatment in Grade II

ependymomas, whereas anaplastic ependymomas require surgical resection along with radiation therapy.^[12,15-19] The 5 year survival rate as described by Metellus *et al.* is $57.1\% \pm 8.7\%$.^[20] Therefore CE appear to have a relatively favorable prognosis as compared to other ependymomas. However, it is unclear if their indolent behavior depends on an earlier presentation due to cortical involvement, their accessibility in addition to resectability or their intrinsic pathobiology.^[21] Gender, histopathology type, location of tumor, extent of surgery, patient age at diagnosis plays an important role in the prognosis of these tumor.^[22,3]

References

1. Dilli UD, Yıldırım M, Suren D, Turk CC, Goktaş S, Parlak E, *et al.* Frontal lobe ependymoma: A case report. *Erciyes Med J* 2013;35:75-8.
2. Hiniker A, Lee HS, Chang S, Berger M, Perry A. Cortical ependymoma with unusual histologic features. *Clin Neuropathol* 2013;32:318-23.
3. Van Gompel JJ, Koeller KK, Meyer FB, Marsh WR, Burger PC, Roncaroli F, *et al.* Cortical ependymoma: An unusual epileptogenic lesion. *J Neurosurg* 2011;114:1187-94.
4. Mckeever PE, Boyer PJ. The brain spinal cord and meninges. In: Mills ES, editor. *Sternberg's Diagnostic Surgical Pathology*. 4th ed. New Delhi: Jaypee Brothers Medical Publishers; 2006. p. 446-51.
5. Louis DN, Ohgaki H, Wiestler OD, Cavenee WK, Burger PC, Jouvet A, *et al.* The 2007 WHO classification of tumours of the central nervous system. *Acta Neuropathol* 2007;114:97-109.
6. Roncaroli F, Consales A, Fioravanti A, Cenacchi G. Supratentorial cortical ependymoma: Report of three cases. *Neurosurgery* 2005;57:E192.
7. Hegyi L, Peston D, Theodorou M, Moss J, Olver J, Roncaroli F. Primary glial tumor of the retina with features of myxopapillary ependymoma. *Am J Surg Pathol* 2005;29:1404-10.
8. Busse C, Nazeer T, Kanwar VS, Wolden S, LaQuaglia MP, Rosenblum M. Sacrococcygeal immature teratoma with malignant ependymoma component. *Pediatr Blood Cancer* 2009;53:680-1.
9. Guerrieri C, Jarlsfelt I. Ependymoma of the ovary. A case report with immunohistochemical, ultrastructural, and DNA cytometric findings, as well as histogenetic considerations. *Am J Surg Pathol* 1993;17:623-32.
10. Mikami M, Komuro Y, Sakaiya N, Tei C, Kurahashi T, Komiyama S, *et al.* Primary ependymoma of the ovary, in which long-term oral etoposide (VP-16) was effective in prolonging disease-free survival. *Gynecol Oncol* 2001;83:149-52.
11. Manasa PL, Uppin MS, Sundaram C. Analysis of squash smear cytology of ependymomas. *Acta Cytol* 2012;56:183-8.
12. Lehman NL. Central nervous system tumors with ependymal features: A broadened spectrum of primarily ependymal differentiation? *J Neuropathol Exp Neurol* 2008;67:177-88.
13. Lehman NL. Patterns of brain infiltration and secondary structure formation in supratentorial ependymal tumors. *J Neuropathol Exp Neurol* 2008;67:900-10.
14. Burger PC. Ependymoma. In: Burger PC, editor. *Diagnostic Pathology Neuropathology*. 1st ed. Canada: Amirsys Publisher; 2012. p. 96-113.
15. Yurt A, Selçuki M, Ertürk AR, Küpelioglu A. Large supratentorial cortical ependymoma in a child. *Clin Med Res* 2010;8:25-7.
16. Lehman NL, Jordan MA, Huhn SL, Barnes PD, Nelson GB, Fisher PG, *et al.* Cortical ependymoma. A case report and review. *Pediatr Neurosurg* 2003;39:50-4.
17. Lum DJ, Halliday W, Watson M, Smith A, Law A. Cortical ependymoma or monomorphous angiocentric glioma? *Neuropathology* 2008;28:81-6.
18. Miyazawa T, Hirose T, Nakanishi K, Uozumi Y, Tsuzuki N, Shima K. Supratentorial ectopic cortical ependymoma occurring with intratumoral hemorrhage. *Brain Tumor Pathol* 2007;24:35-40.
19. Mork SJ, Loken AC. Ependymoma: A follow-up study of 101 cases. *Cancer* 1977;40:907-15.

20. Metellus P, Figarella-Branger D, Guyotat J, Barrie M, Giorgi R, Jouvet A, *et al.* Supratentorial ependymomas: Prognostic factors and outcome analysis in a retrospective series of 46 adult patients. *Cancer* 2008;113:175-85.
21. Van Gompel JJ, Rubio J, Cascino GD, Worrell GA, Meyer FB. Electroocortigraphy-guided resection of temporal cavernoma: Is electrocortigraphy warranted and does it alter the surgical approach? *J Neurosurg* 2009;110:1179-85.
22. McGuire CS, Sainani KL, Fisher PG. Both location and age predict survival in ependymoma: A SEER study. *Pediatr Blood Cancer* 2009;52:65-9.

How to cite this article: Bijwe S, Ansari S, Jadhav V, Palande D. Pure cortical ependymoma: A rare entity. *Asian J Neurosurg* 2015;10:162-5.

Source of Support: Nil, **Conflict of Interest:** None declared.