

## CASE REPORT

# Spontaneous atlantoaxial subluxation associated with tonsillitis

Meenalochani Shunmugam, Santosh Poonnoose

Department of Neurosurgery, Flinders Medical Centre, Flinders Drive, Bedford Park, Adelaide, SA 5042, Australia

## ABSTRACT

Atlantoaxial subluxation is a rare condition and requires a high index of suspicion to diagnose and treat in order to avoid long-term sequelae. Here, we present a case of late presentation of a nontraumatic rotatory subluxation of the atlantoaxial joint or atlantoaxial rotatory subluxation. A 17-year-old girl presented 3 months after the onset of nonspecific upper limb sensory symptoms which eventually settled spontaneously. Initial conservative management by the general practitioner had no effect. Computed tomography scanning revealed a Type 1 dislocation with rotatory fixation and with <3 mm anterior displacement of the atlas. The management of Type 1 subluxations is usually conservative with bed rest, oral nonsteroidal anti-inflammatory drugs, muscle relaxants, reduction (if required) and immobilization with a soft collar. This patient, however, required more invasive management due to the late presentation and slightly greater fixed deformity. As the subluxation could not be reduced with active manipulation, Gardner-Wells tongs with traction were applied. She then progressed to a pinned HALO, cyber neck support and subsequently an aspen collar which was eventually weaned off over a few weeks. The outcome and radiologic alignment at follow-up was satisfactory.

**Key words:** Atlantoaxial subluxation, Grisel's syndrome, torticollis

## Introduction

Nontraumatic atlantoaxial subluxation (Grisel's syndrome) is a rotatory subluxation of the atlantoaxial joint caused by an inflammatory process in the upper neck.<sup>[1,2]</sup> Described by Sir Charles Bell in 1830, and named after Pierre Grisel in 1930, this condition remains rare, and its pathogenesis incompletely understood. It primarily affects the pediatric population with 90% of patients being under 21 years of age.<sup>[3]</sup> It is seen most frequently following upper respiratory tract infections and surgical procedures of the head and neck.<sup>[1]</sup> Its management involves reducing the subluxation and treating the infectious process.<sup>[1]</sup>

## Case Report

A 17-year-old girl presented to the emergency department with torticollis toward the left. Three months prior to presentation she had suffered from tonsillitis and awoke one day with torticollis, denying any history of trauma. Initial symptoms included nonspecific sensory symptoms involving the upper limb and pain in the neck with restriction of neck movements. The tonsillitis settled uneventfully with antibiotics. She consulted her general practitioner who managed her torticollis conservatively with physiotherapy and manipulation with no relief.

On examination, there was fixed rotation of the neck to the left with normal neurological assessment. Active manipulation of the head and neck was painful and therefore reduction impossible. A computed tomography (CT) scan and magnetic resonance imaging demonstrated rotatory subluxation at C1/C2 with intact ligaments and no critical compression of the spinal cord [Figures 1 and 2].

An attempt at manual reduction was unsuccessful, so Gardner-Wells tongs with traction weight was applied with regular oral diazepam concurrently. Four days later and with 8 pounds (3.63 kg) of traction weight, a CT scan and plain radiographs of her neck confirmed near normal alignment [Figure 3].

She was, therefore, braced with a pinned HALO vest and followed-up closely as an outpatient. After a total of 3 months

### Access this article online

#### Quick Response Code:



#### Website:

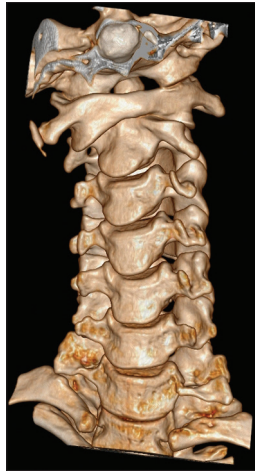www.asianjns.org

#### DOI:

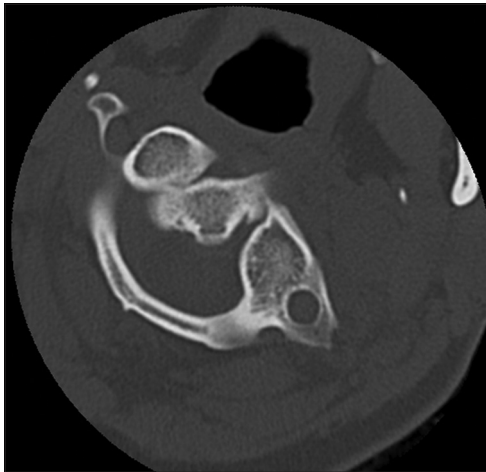
10.4103/1793-5482.152112

### Address for correspondence:

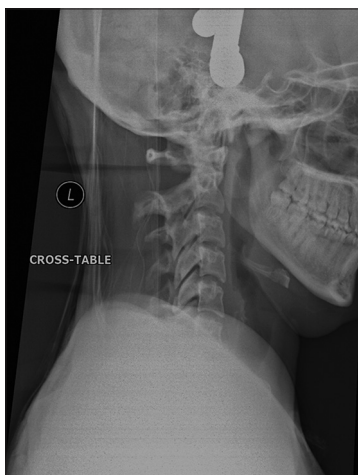Dr. Meenalochani Shunmugam, Department of Neurosurgery, Flinders Medical Centre, Flinders Drive, Bedford Park, Adelaide, SA 5042, Australia.  
E-mail: meenushun@gmail.com



**Figure 1:** Computed tomography neck three-dimension reconstruction - ventral view showing anterior subluxation of the right L1 facet



**Figure 2:** Axial computed the tomography slice of C1-C2 showing the rotation subluxation prior to reduction



**Figure 3:** Lateral view cervical spine-X-ray alignment after 8 pounds traction

in the pinned HALO, she was transitioned into a “cyber” neck support and subsequently placed into an aspen collar which

was also gradually weaned off over a period of 4 weeks. She remains neurologically intact with normal radiological vertebral alignment.

## Discussion

The atlantoaxial joint is formed by two opposing, saddle shaped biconvex surfaces which allows up to 40° of rotation to either side.<sup>[4]</sup> The most widely accepted theory for Grisel’s syndrome is the two-hit hypothesis. The first-hit is cervical ligamentous laxity seen in the pediatric population at baseline; the second-hit is the induction of spasm by inflammatory mediators carried to cervical muscles by the pharyngovertebral venous plexus.<sup>[1,3]</sup>

Fielding and Hawkins described a grading system with rotatory fixation that serves as a guide to the severity of injury:

- Type 1 is <3 mm anterior displacement of the atlas
- Type 2 is 3–5 mm displacement
- Type 3 is >5 mm and
- Type 4 is posterior displacement.<sup>[5]</sup>

Types 1 and 2 are not typically associated with neurologic impairment, but Types 3 and 4 are reported to have a 15% incidence of a range of neurologic involvement, the most severe being paralysis and death.<sup>[2]</sup> Kraft and Tschopp have proposed to add Type 0 - persistent torticollis with no radiologic evidence of subluxation.<sup>[6]</sup>

## Treatment suggestions are

- Type 0 - antibiotic therapy with close follow-up
- Type 1 - conservative with bed rest, oral nonsteroidal anti-inflammatory drugs, muscle relaxants, reduction (if required) and immobilization with a soft collar
- Type 2 - reduction and cervical traction with a stiff cervical collar followed by a period of the halo vest for 6–12 weeks
- Types 3 and 4 - cervical traction and bed rest with a period of cervical immobilization.<sup>[7]</sup>

All the above would require serial imaging in order to assess progress. Surgery with open reduction and cervical fusion should be explored in recurrent cases or where conservative treatment has failed.<sup>[7]</sup> The patient discussed here had a Type 1 injury, but due to the long interval between onset and presentation, a period of traction and HALO were applied. This case illustrates that there can be a variety of presentations of atlantoaxial rotatory subluxation, and each case should be assessed carefully to determine the best management option for optimal patient outcome.

## References

1. Osiro S, Tiwari KJ, Matusz P, Gielecki J, Tubbs RS, Loukas M. Grisel’s syndrome: A comprehensive review with focus on pathogenesis, natural history, and current treatment options. *Childs Nerv Syst* 2012;28:821-5.

2. Galer C, Holbrook E, Treves J, Leopold D. Grisel's syndrome: A case report and review of the literature. *Int J Pediatr Otorhinolaryngol* 2005;69:1689-92.
3. Battiata AP, Pazos G. Grisel's syndrome: The two-hit hypothesis – A case report and literature review. *Ear Nose Throat J* 2004;83:553-5.
4. Singh VK, Singh PK, Balakrishnan SK, Leitao J. Traumatic bilateral atlantoaxial rotatory subluxation mimicking as torticollis in an adult female. *J Clin Neurosci* 2009;16:721-2.
5. Fielding JW, Hawkins RJ. Atlanto-axial rotatory fixation. Fixed rotatory subluxation of the atlanto-axial joint. *J Bone Joint Surg Am* 1977;59:37-44.
6. Kraft M, Tschopp K. Evaluation of persistent torticollis following adenoidectomy. *J Laryngol Otol* 2001;115:669-72.
7. Rinaldo A, Mondin V, Suárez C, Genden EM, Ferlito A. Grisel's syndrome in head and neck practice. *Oral Oncol* 2005;41:966-70.

**How to cite this article:** Shunmugam M, Poonnoose S. Spontaneous atlantoaxial subluxation associated with tonsillitis. *Asian J Neurosurg* 2015;10:139-41.

**Source of Support:** Nil, **Conflict of Interest:** None declared.