

## CASE REPORT

# Metaplastic conus meningioma and its applied aspects

Srikanth Reddy, Aneel Kumar Pulligopu, Ashish Kumar, Barada Prasad Sahu

Department of Neurosurgery, Nizam's Institute of Medical Sciences, Punjagutta, Hyderabad, Andhra Pradesh, India

## ABSTRACT

Cranial meningiomas may present with or without major deficits depending on their location and morphology. Spinal meningiomas account for 25% of all the spinal tumors. Most commonly encountered in the dorsal spine in middle-aged females, these intradural-extramedullary tumors can usually be excised without difficulty. Rarely, they can be encountered in the lumbar spine and may create many tactical problems for the surgical team especially if it is calcified and contains metaplastic bone. We report a 55-year-old patient who presented with backache and investigations revealed a calcified lesion at L1 level that was thought of as an ependymoma initially. Intraoperatively, the lesion was calcified in parts, and the histopathology revealed it to be a metaplastic meningioma with calcification. The patient had a transient hip weakness, which recovered completely later on. Calcification in meningiomas is common. However, frank bony metaplasia is extremely rare. More importantly, the applied aspect of their presence in the region of conus lies in the careful dissection to prevent damage to the surrounding neural structures. Awareness regarding the same may help us preventing complications in the future.

**Key words:** Calcification, conus, metaplastic meningioma

## Introduction

Spinal meningiomas are the second only to tumors of the nerve sheath in the intradural-extramedullary location. They account for approximately 25% of all spinal tumors. Approximately, 80% of spinal meningiomas are located in the thoracic spine, followed by cervical spine (15%), lumbar spine (3%), and near foramen magnum (2%).<sup>[1-3]</sup> Based on location, lumbar meningiomas constitute merely 2–3% of all spinal tumors. We hereby present a case of 55-year-old lady presenting with persistent low backache diagnosed to have intradural-extramedullary calcified metaplastic meningioma at L1 undergoing complete surgical excision of the lesion.

## Case Report

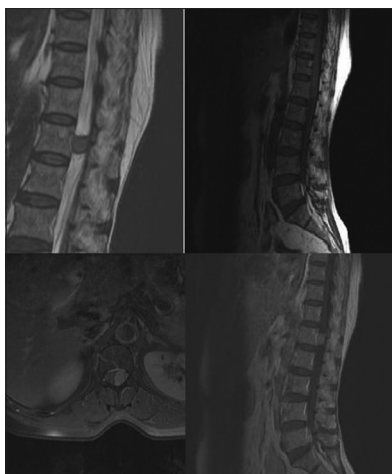A 55-year-old female patient consulted us with persisting dull aching low backache for past 2 months, radiating along

the posterior aspect of her right thigh. Pain aggravated with lying down in the supine position for prolonged periods and was relieved in sitting a position and partially with analgesics. Her neurological examination was within normal limits. Magnetic resonance imaging showed a solitary intradural-extramedullary iso-intense lesion on T1 and T2-weighted images, homogeneously enhancing on contrast measuring 3 cm × 2 cm, located at L1 region pushing the conus medullaris to left side [Figure 1]. A presumptive diagnosis of ependymoma was made. Patient underwent D12 and L1 laminectomy, exposing normal dura above and below the lesion. Dura was opened lateral to lesion towards the left side to avoid injury to conus-cauda and nerve rootlets. Tumor was brownish red, soft in the center and firm to hard in consistency as we proceeded outwards. The calcified peripheral parts had to be cut with a scalpel after protecting the roots and only then the tumor was completely excised. Adherent part of the tumor to dura was excised, and the dural base was coagulated. Histology showed frank bony trabeculae within the meningioma. The lesion was compromising of spindle cells arranged in whirling pattern and in syncytical pattern. Metaplastic bone was seen along with psammomatous calcification [Figure 2]. Mitosis was sparse 0–1/10 HPF. There was no necrosis. Progesterone receptor status was negative, and Ki 67 index showed a labeling index of <1%; features consistent with Metaplastic Meningioma. Postoperatively patient had mild weakness of hip flexion (4/5) that improved over next 3 days with physiotherapy. At present patient is asymptomatic and under our follow-up for 3 months.

Access this article online	
<b>Quick Response Code:</b> 	<b>Website:</b> <a href="http://www.asianjns.org">www.asianjns.org</a>
	<b>DOI:</b> 10.4103/1793-5482.153498

### Address for correspondence:

Dr. Ashish Kumar, Department of Neurosurgery, Nizam's Institute of Medical Sciences, Punjagutta, Hyderabad - 500 082, Andhra Pradesh, India.  
 E-mail: drashishmch@hotmail.com

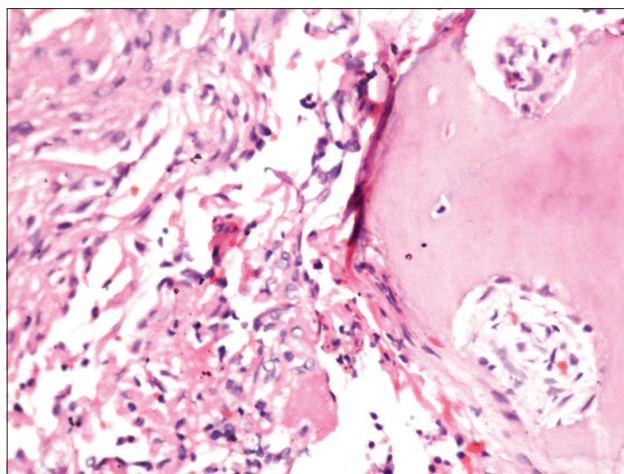


**Figure 1:** Magnetic resonance imaging lumbar spine showing the lesion that is iso-intense on T1-weighted and extremely hypointense on T2-weighted imaging along with homogenous contrast enhancement evident on sagittal and axial images

## Discussion

Meningiomas are the most common benign intracranial tumors arising from arachnoid cap cells. Spinal meningiomas though not uncommon account for approximately 0.75–12.7% of all meningiomas<sup>[4,6]</sup> and about 25–46% of total spinal cord tumors.<sup>[7,8]</sup> These lesions most commonly involve the thoracic region (67–84%) and encountered least commonly in the lumbar region (2–10%).<sup>[2,3]</sup> Meningiomas presenting as primary tumors of the intradural conus and cauda equina region are still rare, and these represent only 2% of all spinal cord meningiomas.<sup>[2,4,5]</sup> Overall incidence is common among middle-aged women, but the sex incidence is equal in the lumbosacral region.<sup>[9]</sup> Our patient presented with only dull aching backache. As spinal meningiomas are generally slow growing benign tumors, neurological deficits or gait disturbances appear following significant spinal cord compression mostly at an advanced stage of the disease. Hence, these unspecific symptoms such as local pain are often misinterpreted until the diagnosis is confirmed by neuroimaging procedures<sup>[10-12]</sup> like in our case.

Metaplasia of the arachnoid cells has been proposed as the etiology of ossification by some and others favored dystrophic calcification as the pathogenesis.<sup>[13]</sup> Psammoma bodies are especially frequent in spinal meningiomas.<sup>[14]</sup> Approximately 50–90% of spinal meningiomas have psammoma bodies compared with only 10% of the intracranial form.<sup>[15]</sup> Where they are particularly numerous, they have a tendency to fuse and form calcium spicules. The gradual confluence of calcium deposits can give the meningioma a rock-like consistency,<sup>[16]</sup> like in our case where metaplastic bone formation was noted along with psammomatous calcification. The quintessential surgical challenge in our case was to excise it piecemeal where the tumor had to be cut with scalpel and underlying



**Figure 2:** The histopathology showing spindle cells arranged in whorls and syncytial pattern along with the presence of frank ossification with chondrocytes

adherent rootlets needed to be separated with great care under microscope. But still patient ended up having hip flexion weakness that gradually improved with physiotherapy, this emphasizing the eloquent nature of underlying structures. Many investigators have stated that calcification of meningioma is another variable in tumor recurrence as it adds to incomplete removal of the tumor.<sup>[7,17,18]</sup> Also, outcome following surgery for metaplastic spinal meningioma can be good, despite the severity of the pre and intraoperative condition; however, highly calcified tumors may bear a poor prognosis.<sup>[7,18]</sup> At times, it is mentioned that a calcified anterior spinal, thoracic meningioma should be managed like a calcified disk herniation despite the increased risk of cerebrospinal fluid leakage.<sup>[19,20]</sup> Therefore, the detection of metaplastic bone within a meningioma is important to estimate the difficulty of resection and thereby improving the postoperative prognosis by careful intra-operative handling in eloquent region like conus.

## References

1. Frank BL, Harrop JS, Hanna A, Ratliff J. Cervical extradural meningioma: Case report and literature review. *J Spinal Cord Med* 2008;31:302-5.
2. Salehpour F, Zeinali A, Vahedi P, Halimi M. A rare case of intramedullary cervical spinal cord meningioma and review of the literature. *Spinal Cord* 2008;46:648-50.
3. Sahni D, Harrop JS, Kalfas IH, Vaccaro AR, Weingarten D. Exophytic intramedullary meningioma of the cervical spinal cord. *J Clin Neurosci* 2008;15:1176-9.
4. Arnautovic K, Arnautovic A. Extradural intradural spinal tumors: A review of modern diagnostic and treatment options and a report of a series. *Bosn J Basic Med Sci* 2009;9 Suppl 1:40-5.
5. Saydam O, Senol O, Schaaaj-Visser TB, Pham TV, Piersma SR, Stemmer-Rachamimov AO, et al. Comparative protein profiling reveals minichromosome maintenance (MCM) proteins as novel potential tumor markers for meningiomas. *J Proteome Res* 2010;9:485-94.
6. Solero CL, Fornari M, Giombini S, Lasio G, Oliveri G, Cimino C, et al. Spinal meningiomas: Review of 174 operated cases. *Neurosurgery* 1989;25:153-60.

7. Roux FX, Nataf F, Pinaudeau M, Borne G, Devaux B, Meder JF. Intraspinal meningiomas: Review of 54 cases with discussion of poor prognosis factors and modern therapeutic management. *Surg Neurol* 1996;46:458-63.
8. Cohen-Gadol AA, Zikel OM, Koch CA, Scheithauer BW, Krauss WE. Spinal meningiomas in patients younger than 50 years of age: A 21-year experience. *J Neurosurg* 2003;98:258-63.
9. Mathew P, Todd NV. Intradural conus and cauda equina tumours: A retrospective review of presentation, diagnosis and early outcome. *J Neurol Neurosurg Psychiatry* 1993;56:69-74.
10. Gezen F, Kahraman S, Canakci Z, Bedük A. Review of 36 cases of spinal cord meningioma. *Spine (Phila Pa 1976)* 2000;25:727-31.
11. Morandi X, Haegelen C, Riffaud L, Amlashi S, Adn M, Brassier G. Results in the operative treatment of elderly patients with spinal meningiomas. *Spine (Phila Pa 1976)* 2004;29:2191-4.
12. Doita M, Harada T, Nishida K, Marui T, Kurosaka M, Yoshiya S. Recurrent calcified spinal meningioma detected by plain radiograph. *Spine (Phila Pa 1976)* 2001;26:E249-52.
13. Naderi S, Yilmaz M, Canda T, Acar U. Ossified thoracic spinal meningioma in childhood: A case report and review of the literature. *Clin Neurol Neurosurg* 2001;103:247-9.
14. Dross PE, Raji MR. CT myelography of calcified thoracic neurilemmoma. *AJNR Am J Neuroradiol* 1985;6:967-8.
15. Nyström SH, Nyholm M. The origin of the calcium deposits in psammoma bodies of human spinal meningiomas. *Naturwissenschaften* 1966;53:703-4.
16. Lunardi P, Missori P, Franco C, Delfini R, Fortuna A. Hard-rock spinal meningioma. Case report and review of the literature. *J Neurosurg Sci* 1992;36:243-6.
17. Pear BL, Boyd HR. Roentgenographically visible calcifications in spinal meningioma. *Am J Roentgenol Radium Ther Nucl Med* 1974;120:32-45.
18. Camp JD, Adson AW, Shugrue JJ. Roentgenographic findings associated with tumors of spinal column, spinal cord and associated tissues. *Am J Cancer* 1933;17:348-72.
19. Messori A, Rychlicki F, Salvolini U. Spinal epidural en-plaque meningioma with an unusual pattern of calcification in a 14-year-old girl: Case report and review of the literature. *Neuroradiology* 2002;44:256-60.
20. Jenny B, Rilliet B, May D, Pizzolato GP. Transthoracic transvertebral approach for resection of an anteriorly located, calcified meningioma. Case report. *Neurochirurgie* 2002;48:49-52.

**How to cite this article:** Reddy S, Pulligopu AK, Kumar A, Sahu BP. Metaplastic conus meningioma and its applied aspects. *Asian J Neurosurg* 2015;10:166-8.

**Source of Support:** Nil, **Conflict of Interest:** None declared.