

## CASE REPORT

# Choroid plexus papilloma

Divya Sethi, Rashmi Arora, Ketan Garg, Parul Tanwar

Department of Pathology, VMMC and Safdarjang Hospital, New Delhi, India

## ABSTRACT

Choroid plexus tumors are rare intracranial tumors which account for only 0.4-0.6% of all brain tumors. These are intraventricular papillary neoplasms derived from choroid plexus epithelium and range from choroid plexus papillomas (World Health Organisation (WHO) grade I) to choroid plexus carcinomas (WHO grade III). It is an important albeit rare cause of hydrocephalous. We present to you the case of a 1-year-old child who presented with the signs and symptoms of hydrocephalous and was diagnosed as choroid plexus papilloma on histopathology.

**Key words:** Choroid plexus, lateral ventricle, papilloma

## Introduction

Choroid plexus tumors are intraventricular papillary neoplasms derived from choroid plexus epithelium and account for 0.4-0.6% of all brain tumors. Choroid plexus papillomas (CPP) outnumber choroid plexus carcinomas (CPC) by a ratio of at least 5:1. CPP are confined to lateral (50%), third (5%), and fourth (40%) ventricles with two or three ventricles involved in 5% of cases.<sup>[1]</sup>

## Case Report

A 1-year-old male child was brought to us with history of large-sized head and irritability since the last 3 months and occasional vomiting. There was no history of fever, any visual disturbances, speech affection or any other cranial nerve involvement. He did not have any altered sensorium, convulsions, head trauma, or tuberculous contact.

Examination revealed a normal general physical examination. On examination of the central nervous system, the child was conscious. Fundoscopy showed evidence of bilateral papilledema; vision was grossly normal. There was no other cranial nerve affection. The other systems were normal. Our clinical diagnosis was hydrocephalous. Radiographs of the skull

showed sutural separation with a silver-beaten appearance. The magnetic resonance imaging (MRI) of the brain revealed a large mass in the posterior horn of the right lateral ventricle attached by a pedicle, with moderate hydrocephalus [Figure 1]. The child was operated through a right parietal craniotomy and the lateral ventricle opened by a cortical incision behind the post-central gyrus. The highly vascular friable tumor was exposed, its pedicle was clamped and cauterized, and then the tumor was removed piecemeal.

Resected tissue was received in fragments aggregating to 2 × 1 × 1 cm. A few papillary areas were noted grossly. Histopathologic examination showed fronds of fibrovascular tissue covered by uniform cuboidal to columnar epithelial cells [Figures 2 and 3]. No nuclear atypia, necrosis or mitosis was seen. Immunoperoxidase staining showed the tumor cells to be positive for glial fibrillary acidic protein and epithelial membrane antigen. A diagnosis of choroid plexus papilloma was made.

The patient was followed-up with a computed tomography (CT) scan 2 weeks after surgery which showed a decrease in the hydrocephalus, with normal appearing choroid plexus. All the signs and symptoms in the child had resolved postoperatively and he was discharged 2 weeks later.

## Discussion

Choroid plexus tumors represent a spectrum of neoplasms ranging from well-differentiated papillomas (WHO grade I) to

This is an open access article distributed under the terms of the Creative Commons Attribution-NonCommercial-ShareAlike 3.0 License, which allows others to remix, tweak, and build upon the work non-commercially, as long as the author is credited and the new creations are licensed under the identical terms.

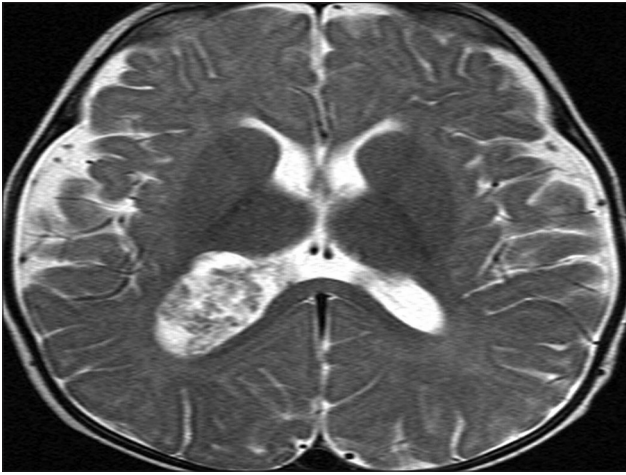
**For reprints contact:** reprints@medknow.com

Access this article online	
Quick Response Code:	Website: www.asianjns.org
	DOI: 10.4103/1793-5482.153501

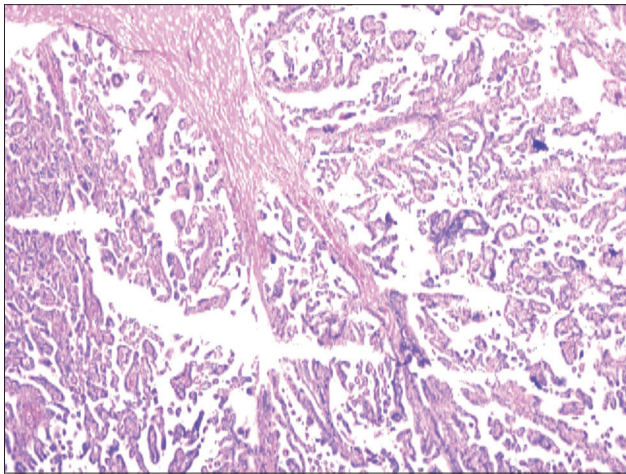
## Address for correspondence:

Dr. Divya Sethi, Senior Resident, Department of Pathology, VMMC and Safdarjang Hospital, New Delhi, India. E-mail: dr.divyasethi@gmail.com

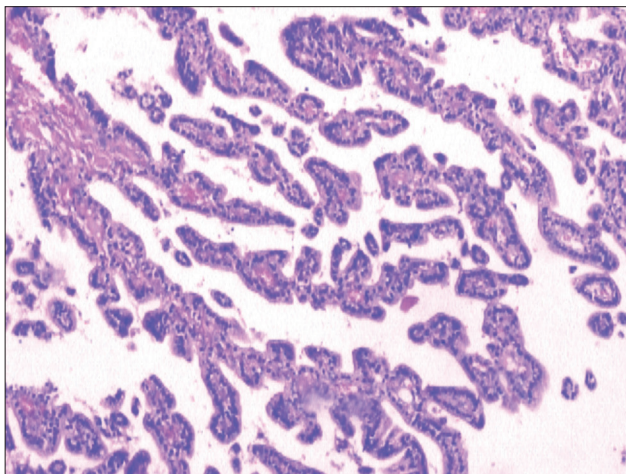
**How to cite this article:** Sethi D, Arora R, Garg K, Tanwar P. Choroid plexus papilloma. Asian J Neurosurg 2017;12:139-41.



**Figure 1:** The magnetic resonance imaging of the brain revealing a large mass in the posterior horn of the right lateral ventricle attached by a pedicle



**Figure 2:** Photomicrograph revealing multiple papillary structures with a fibrovascular core (H and E,  $\times 40$ )



**Figure 3:** Photomicrograph showing uniform cuboidal to columnar epithelial cells lining the papillary structures (H and E,  $\times 100$ )

highly aggressive choroid plexus carcinomas (WHO grade III), with rare intermediate forms referred to as “atypical CPP”, for

which the biologic behavior is still to be defined.<sup>[2]</sup> The fourth ventricle is the most common site of occurrence, followed by the lateral and third ventricles. In children, it occurs more commonly in the lateral ventricles, while the fourth ventricle appears to be the preferred site in adults. Benign tumors are more common in the fourth ventricle, while the anaplastic variety are seen more often in the lateral ventricle.<sup>[3]</sup>

Symptomatology of tumors of the lateral ventricle include convulsions, mental changes, papilledema leading to loss of vision and focal deficits like hemiparesis.<sup>[4]</sup> With tumors in the fourth ventricle, symptoms are headache, ataxia, nystagmus, cerebellar signs, dizziness, loss of vision, vomiting, and diplopia.<sup>[5]</sup>

The clinical progression is usually one of gradual deterioration. Complications that can occur with CPP include spontaneous hemorrhage from the tumor, dissemination of tumor fragments, and hydrocephalus.<sup>[3]</sup>

A CT scan, which is diagnostic, shows a hypodense, lobulated intraventricular mass, which may have finely speckled calcification and which enhances brightly after contrast. MRI will show, on T1-weighted images, the tumor to be hypo- or isointense relative to brain, but hyperintense relative to brain on T2-weighted images.

On gross pathology, the papillomas are soft, pink, globular masses with irregular projections and are highly vascular and friable. Histopathologic examination of the resected tumor is typical of CPP which corresponds to WHO grade I tumors of the nervous system. Papillary fronds lined by bland columnar epithelium are characteristic features. The absence of mitotic activity, nuclear pleomorphism, and necrosis distinguishes it clearly from atypical choroid plexus papilloma and carcinoma.<sup>[1]</sup>

CPPs should be distinguished from bilateral villous hypertrophy of choroid plexus. Both lesions have similar histopathologic features. Bilateral villous hypertrophy is differentiated from CPP by CT scan and MRI findings, which show dense and homogeneously enhanced lesion and by their tendency to extend that leads to hydrocephalus, which usually resolves after complete resection.<sup>[6,7]</sup>

Expression of cytokeratin, vimentin and S-100 are well documented in CPP. The absence of Epithelial Membrane Antigen (EMA) and Glial Fibrillary Acidic Protein (GFAP) further favors the diagnosis of CPP. It is interesting to note that there is variable expression of S-100, vimentin, and GFAP in CPP compared to CPC. There is more S-100 and transthyretin (TTR) tumor positive cells in CPP compared to less frequent staining in CPCs. On the other hand, GFAP may be focally seen in some cases of CPP but positive in about 20% of CPC. It has been reported that fourth ventricle tumors express more S-100 than lateral ventricle tumors and older patients (above 20 years) express more GFAP and TTR than younger patients.<sup>[8]</sup>

Immunohistochemical expression of p53 expression was reported to be consistently positive in choroid plexus carcinoma but undetected in the majority of CPPs proving the role of gene mutation in cancer genesis.<sup>[9]</sup>

CPP are associated with favorable long-term prognosis. Factors that correlate with prognosis are often related to tumor size, preoperative symptoms, and the difficult surgical intervention related to its anatomical location. Most clinicians advocate a “wait and watch” approach after gross total resection of CPP. Improvement in surgical techniques and surgery after care has improved the prognosis of patients. Recurrences are occasionally seen and rare cases of metastases to suprasellar and even craniospinal seeding have been reported.<sup>[10]</sup>

### Financial support and sponsorship

Nil.

### Conflicts of interest

There are no conflicts of interest.

### References

1. Aguzzi A, Brandner S, Paulus W. Choroid plexus tumours. In: Kleihues P, Cavenee WK, editors. World Health Organization Classification of Tumours. Pathology and Genetics: Tumours of the Nervous System. Lyon: IARC Press; 2000. p. 84-6.
2. McGirr SJ, Ebersold MJ, Scheithauer BW, Quast LM, Shaw EG. Choroid plexus papillomas: Long-term follow-up results in a surgically treated series. *J Neurosurg* 1988;69:843-9.
3. Harsh GR, Wilson CB. Neuroepithelial tumors of the adult brain. In: *Neurological Surgery*. 3<sup>rd</sup> ed. Philadelphia: WB Saunders Co; 1990. p. 3103-5.
4. Gradin WC, Talyon C, Fruin AH. Choroid plexus papilloma of the third ventricle: Case report and review of the literature. *Neurosurgery* 1983;12:217-20.
5. Bohm E, Strang R. Choroid plexus papillomas. *J Neurosurg* 1961;18:493-500.
6. Tacconi L, Delfini R, Cantore G. Choroid plexus papillomas: Consideration of a surgical series of 33 cases. *Acta Neurochir (Wien)* 1996;138:802-10.
7. Erman T, Göçer AI, Erdoğan S, Tuna M, Ildan F, Zorludemir S. Choroid plexus papilloma of bilateral lateral ventricle. *Acta Neurochir (Wien)* 2003;145:139-43.
8. Paulus W, Jänisch W. Clinicopathologic correlations in epithelial choroid plexus neoplasms: A study of 52 cases. *Acta Neuropathol* 1990;80:635-41.
9. Jay V, Ho M, Chan F, Malkin D. P53 expression in choroid plexus neoplasms: An immunohistochemical study. *Arch Pathol Lab Med* 1996;120:1061-5.
10. McEvoy AW, Galloway M, Revesz T, Kitchen ND. Metastatic choroid plexus papilloma: A case report. *J Neurooncol* 2002;56:241-6.