

## CASE REPORT

# Rare case report of Traumatic neuroma of anterior superior alveolar nerve associated with high frenal attachment

Anuradha Ananthaneni, Namala Srilekha, Vijay Srinivas Guduru, Mohammad Asif Kiresur

Department of Oral Pathology, St. Joseph Dental College, Eluru, Andhra Pradesh, India

## ABSTRACT

We present an incredible case of traumatic neuroma (TN) in the anterior superior alveolar nerve leading to the swelling in the upper labial mucosa. This paper attempts to highlight the rarity of site of occurrence of this lesion and reports the first case of TN of anterior superior alveolar nerve.

**Key words:** Lip, nasopalatine, nerve, neuroma, rare, traumatic

## Introduction

Traumatic neuroma (TN) is due to the proliferation of a nerve in a reaction to surgery or injury. Oral TN features are akin to TNs in other body parts. It is mostly diagnosed in middle age and show a female predilection. Clinically, it presents as painful firm nodule which is, usually, seen in the mental foramen area, tongue and lower lip. Histologically, it discloses disorganized proliferation of nonencapsulated nerve bundles in a dense collagenous matrix.<sup>[1-4]</sup>

We present a case of TN in the anterior superior alveolar nerve leading to the swelling in the upper labial mucosa. This paper highlights an interesting case of TN arising from anterior superior alveolar nerve in the patient with high frenal attachment, chronic lip sucking habit and with the previous history of surgery.

## Case Report

A 50-year-old female reported to the outpatient department with a chief complaint of a growth over the upper lip since 2 years

and spacing in the upper front teeth since 6 years. The swelling was not associated with the history of pain. The patient gave a history of upper lip sucking habit into the spacing between upper anterior teeth and recurrence of the swelling that was excised 4 years back. There was no history of hyperesthesia and parasthesia in the upper lip. Past medical and dental history were insignificant. Clinical examination revealed an oval-shaped, smooth swelling associated with high frenal attachment measuring 1 cm × 0.5 cm approximately, extending 0.2 cm on either side of upper labial frenum [Figure 1]. The surrounding mucosa appeared normal. On palpation, it was nontender, firm in consistency. No cervical lymphadenopathy was observed. A provisional diagnosis of epithelial polyp with fibrosis was made. Differential diagnosis was given as fibroma, lipoma, mucocele, sialolithiasis, benign minor salivary gland tumors, schwannoma and neurofibroma. Routine blood investigations were within normal limits. Surgical excision of the lesion was done under local anesthesia. Grossly, the specimen was 0.9 cm × 0.3 cm in size, whitish brown in color and firm in consistency. Histopathological examination revealed numerous interwining and haphazardly arranged nonencapsulated nerve bundles admixed with the fibrovascular stroma [Figures 2 and 3]. Based on these features, it was diagnosed as TN probably arising from anterior superior alveolar nerve.

## Discussion

Oder in 1811 1<sup>st</sup> time used the term “Amputation neuroma” as a synonym to TN. In response to trauma or surgery, there is reactive proliferation of neural tissue involving the peripheral nerves hence not considered as true neoplasm.<sup>[2,4,5]</sup>

There are two types of neuromas. True neuroma, which contains mainly nerve tissue whereas, in a false neuroma, connective tissue derived from the nerve sheath forms the

### Access this article online

#### Quick Response Code:



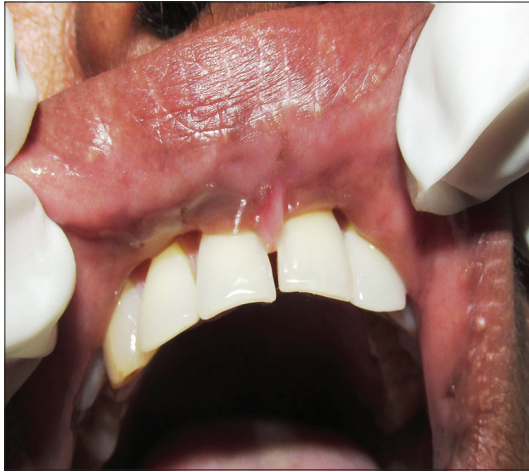**Website:**  
www.asianjns.org

**DOI:**  
10.4103/1793-5482.153502

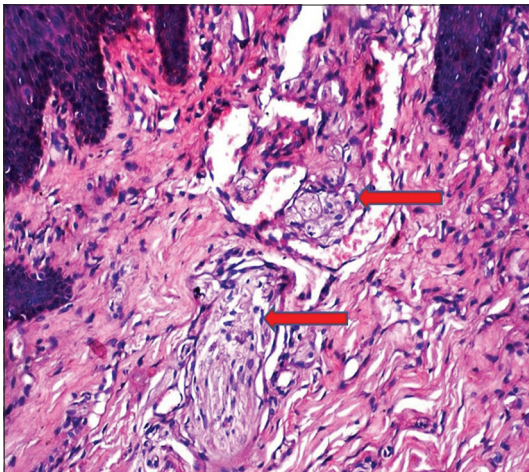
### Address for correspondence:

Dr. Anuradha Ananthaneni,  
Department of Oral Pathology, St. Joseph Dental College,  
Duggirala, Eluru - 534 004, Andhra Pradesh, India.  
E-mail: anuradhaundavalli@yahoo.com

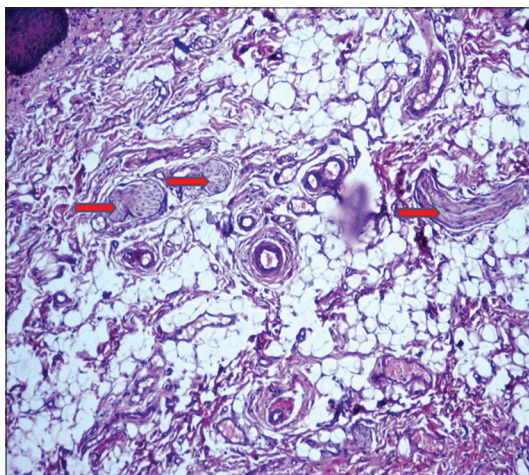
major part of the lesion.<sup>[6]</sup> Lopes *et al.* have reported TN with mature ganglion cells, called as pseudoganglioneuroma.



**Figure 1:** Swelling associated with high frenal attachment



**Figure 2:** Presence of nerve bundles (red arrows) just beneath the epithelium within the connective tissue (H and E, ×40)



**Figure 3:** Nerve bundles without capsule (red arrows) seen admixed with the fibrovascular stroma (H and E, ×40)

The development of symptomatic TN may be due to chronic irritation, mechanical destruction, complicated wound healing or irregular scar developed close to the sensory nerve injury. Motor nerve does not show the development of TN because of absence or little potential for regeneration. In the head and neck region, TN is caused consequent to tooth extraction, neck dissection, the ramus split surgery, incision and drainage and parotidectomy with tooth extraction to be the most common etiological factor. Tooth extraction, ill fitted denture wearing, intraoral incision for drainage have been reported as etiologies of TN in the mental region.<sup>[4]</sup> Common intraoral locations are the mental foramen, lower lip and tongue.<sup>[1,5]</sup> Contributing factors in this case could be trauma due to high frenal attachment, chronic upper lip sucking habit and previous surgical intervention might have traumatized the anterior superior alveolar nerve resulting in TN. Review of literature reveals no case of TN in the upper lip involving anterior superior alveolar nerve.

Foltan *et al.* proposed a hypothesis for the development of TN which can be divided into five phases: Injury to nerve and adjacent tissue, simultaneous proliferation of nerve and wound repairing cells and action of signaling molecules, wound and scar contraction, defensive reaction (proliferation) of nerve fibers causing constriction and finally development of a balance between nerve regeneration (proliferation) and damage (contraction).

When nerve is severed as a result of surgery or trauma, proximal stump regenerates by growth of axons and proliferation of Schwann cells in an attempt to establish innervation with the distal segment. If these regenerating element encounters a barrier in the form of scar, proximal stump continues to proliferate and produces a disorganized interlace of neural fibers and connective tissue extending into the surrounding soft tissue, whereas distal axons suffer Wallerian degeneration. Cytokines (such as interleulin 1b, interleukin-10, transforming growth factor- $\beta$ 1) and other extracellular signals act in this site. The irregular nerve fibers proliferate and immerse in scar tissue. Myofibroblasts present inside the wound contract the scar. So, in order to defend neural fiber from contraction injury, surrounding peri- and epineural tissue around the nerve fibers attenuate to proliferate. As a result of this defensive reaction of the nerve, tissue constricts. Then a balance between nerve regeneration (proliferation) and damage (contraction) develops. The development of TN can be circumvented by placing the injured or transected nerve away from potential excessive fibroproduction site and/or to avoid the external factors leading to excessive fibroproduction.<sup>[4,7]</sup>

They occur at any age but most commonly seen in middle-aged women. Our case was also a female patient

of middle age group. Bimodal occurrence in young and old individuals is noted as younger age group are more prone to trauma, and older age group frequently undergo surgeries.<sup>[8]</sup> Both trauma in the form of chronic lip sucking habit and surgery might have played a role in the development of TN in our case.

They are characteristically smooth surfaced, nonulcerated nodules, less than 2 cm in diameter as in the present case. Pain has been considered an inimitable feature of this lesion that may be due to the constriction of nerves by stromal fibrosis.<sup>[3]</sup> Since many of nerves at injury site are amyelinated, pressure aggravates the condition. Sist's research observed that oral TN located at the mental foramen were the most painful of all other sites. On an average 25–33% of oral TNs, pain was reported to be intermittent or constant, ranging from mild tenderness or burning to severe radiating type.<sup>[1,4,6]</sup> Asymptomatic nature in this case can be explained by the absence of inflammation as TN with inflammation are most likely to be painful than those without significant inflammation.

Clinically TN must be differentiated from swellings on upper lip like sialolothiasis, lipomas, hemanigiomas, benign minor salivary gland tumors, schwannoma, neurofibroma, canalicular adenomas and last but not least from mucocele. Histologically, TN must be differentiated from the neurofibroma, palisaded encapsulated tumor and multiple endocrine neoplasia (MEN2b). Participation of all elements of nerve fascicles, irregularly arranged varying sized fascicles and identification of damaged nerve helps to rule out neurofibroma. Disorder arrangement of nerve fascicles also ruled out palisaded encapsulated tumor. MEN2b, usually, associated with medullary carcinoma of the thyroid, pheochromocytoma of the adrenal glands, and skeletal anomalies. Histologically, the oral lesions demonstrate complex bundles of nerves, with a prominent perineurium within a fibrous stroma. Absence of all the above features along with the presence of history of prior trauma or surgery to the involved area and the surroundings tissue showing reactive fibrosis with or without chronic inflammation eliminates MEN. Ultrastructurally, TN exhibits multiple laminae of perineural cells ensheathing numerous nerve fascicles within the collagenous stroma<sup>[9]</sup>

Simple excision along with removal of the resembling proximal

stump in an area away from old scar tissue is considered to be the best treatment. Tay *et al.* found 35% diminution in the development of TN by diathermy. Steriotactic radiosurgery, local infiltration with steroid, sympathetic nerve block, and ultrasonic therapy are the other treatment options.<sup>[1,4]</sup> Nerve sections or blockage with alcohol are not indicated as they are ineffective most of the times and are detremintal.<sup>[5]</sup> Surgical intervention was successful in most of the cases but in few cases, removal of the lesions had limited effect on the pain pattern which was due to permanent discharge in ascending PGM (pattern generating mechanisms) induced by painful impulse from periphery.<sup>[4]</sup> Occasional lesions found to recur.<sup>[1,5]</sup>

## Conclusion

Traumatic neuroma can occur even in the anterior superior alveolar nerve with a clinical presentation as a swelling in the upper lip. It must be differentiated from the other upper lip swellings and is important to accurately recognize this condition in order to any avoid misdiagnosis.

## References

1. Neville BW, Damm DD, Allen CM, Bouquot JE. Oral and Maxillofacial Pathology. 2<sup>nd</sup> ed. Philadelphia: Saunders WB; 2002. p. 454-5.
2. Rajendran R. Shafer's Oral Pathology. 6<sup>th</sup> ed. Amsterdam: Elsevier; 2006. p. 196.
3. Lopes MA, Vargas PA, Almeida OP, Takahama A, León JE. Oral traumatic neuroma with mature ganglion cells: A case report and review of the literature. J Oral Maxillofac Pathol 2009;13:67-9.
4. Yang JR, Wang CJ, Kao WB, Wang YL. Traumatic neuroma of bilateral mental nerve: A case report with literature review. Taiwan J Oral Maxillofac Surg 2010;21:252-60.
5. Arribas-García I, Alcalá-Galiano A, Gutiérrez R, Montalvo-Moreno JJ. Traumatic neuroma of the inferior alveolar nerve: A case report. Med Oral Patol Oral Cir Bucal 2008; 13:E186-8.
6. Anuradha A, Ramprasad VV, Vijay Srinivas G, Kashyap B, Suvarna M. Traumatic neuroma – An unforeseen lesion subsequent to simple extraction. SRM Univ Dent Sci 2012;3:160-2.
7. Foltán R, Klíma K, Spacková J, Sedý J. Mechanism of traumatic neuroma development. Med Hypotheses 2008; 71:572-6.
8. Barnes L. Surgical Pathology of Head and Neck. 3<sup>rd</sup> ed. USA: Informa health care; 2009.p. 676-8.
9. Basnaker M, Kumar GS. Neural tumors of oral and para oral region. Int J Dent Clin 2011;3:34-43.

**How to cite this article:** Ananthaneni A, Srilekha N, Guduru VS, Kiresur MA. Rare case report of Traumatic neuroma of anterior superior alveolar nerve associated with high frenal attachment. Asian J Neurosurg 2015;10:169-71.

**Source of Support:** Nil, **Conflict of Interest:** None declared.